
Severe Systemic Reaction to Diphosphonate Bone Imaging Agents: Skin Testing to Predict Allergic Response and a Safe Alternative Agent

Angelita Ramos-Gabatin, Joseph A. Orzel, Thomas R. Maloney, John E. Murnane, and Ronald D. Borchert

Departments of Nuclear Medicine and Medicine, Wilford Hall USAF Medical Center, San Antonio, Texas

We describe a severe systemic reaction which occurred in a patient on two occasions after i.v. injection of chemically related diphosphonate bone imaging agents. Skin testing showed reactivity to multiple commercially available diphosphonate compounds but no significant response to pyrophosphates. A subsequent pyrophosphate bone scan resulted in no adverse reaction. Severe systemic reactions to diphosphonates can occur, skin testing may prove useful in evaluating allergic reactions, and pyrophosphates appear to be a safe alternative agent in patients proven or suspected allergic to diphosphonates.

J Nucl Med 27:1432-1435, 1986

Adverse reactions to radiopharmaceuticals are rare events with an estimated annual incidence in the United States of one to six reactions per hundred thousand (1, 2). A much higher incidence, between 1/1000 and 1/10,000, has been reported in the United Kingdom in a 7-year period between 1977 and 1983 (3). Suspected adverse reactions to diphosphonate compounds comprise between 8 and 27% of the total number of adverse reactions (1,3). However, the true incidence is speculative as proving an adverse reaction is difficult. Faulty reporting and failure to associate an adverse reaction with radiopharmaceutical administration compromise data collection (1,3,4). Previous reports have not documented the potential for a severe systemic reaction to diphosphonates. We report a severe adverse reaction to diphosphonates, proven by rechallenge. Skin testing correlated well with the patient's response, and suggested that pyrophosphates may be safe alternative agents.

CASE REPORT

A 21-yr-old healthy male was hospitalized for evaluation of a severe systemic illness consisting of nausea, headache, chills,

cough, increased myalgias, and fever of 105.2°F which began 8 hr after i.v. injection of 20 mCi of methylene technetium-99m (^{99m}Tc) diphosphonate (MDP)* for re-evaluation of a stress fracture. The patient had no history of previous allergic reactions, was completely well, and was taking no medications prior to the bone scan. No friends or roommates were ill prior to or after the patient's adverse reaction. The patient's illness resolved in 24 hr and multiple studies including extensive cultures, blood counts, biochemical panels, and viral titers including Epstein-Barr virus, were negative or unremarkable.

We discovered the patient had a similar though less severe reaction 1 mo earlier when an initial bone scan was performed to diagnose a metatarsal stress fracture. On that occasion, significant symptoms began within 4 hr of injection of 20 mCi of [^{99m}Tc]hydroxymethylene diphosphonate (HDP)†. Both bone scans showed a metatarsal stress fracture with normal biodistribution of radiopharmaceutical (Fig. 1). A pyrogen reaction was considered, but six other patients injected before and after this patient, from the same multidose vials, on both occasions showed no adverse response.

To further evaluate the patient's adverse reaction, skin testing was performed, on the patient and a normal volunteer, using multiple, chemically related commercial diphosphonate bone agent kits. Two commercial pyrophosphate agents were also tested along with pertechnetate, saline and histamine controls. The concentration of the histamine used was 2.75 mg/cc in sterile water. To minimize radiation exposure and potential for contamination, all radiopharmaceutical kits were prepared with ^{99m}Tc generator eluate which was allowed to decay to background. Otherwise, the manufacturer's guidelines for kit preparation were precisely followed. The radio-

Received Dec. 2, 1985; revision accepted Mar. 21, 1986.

For reprints contact: Joseph A. Orzel, MD, Dept. of Radiology, SB-05, University of Washington, Seattle, WA 98195.

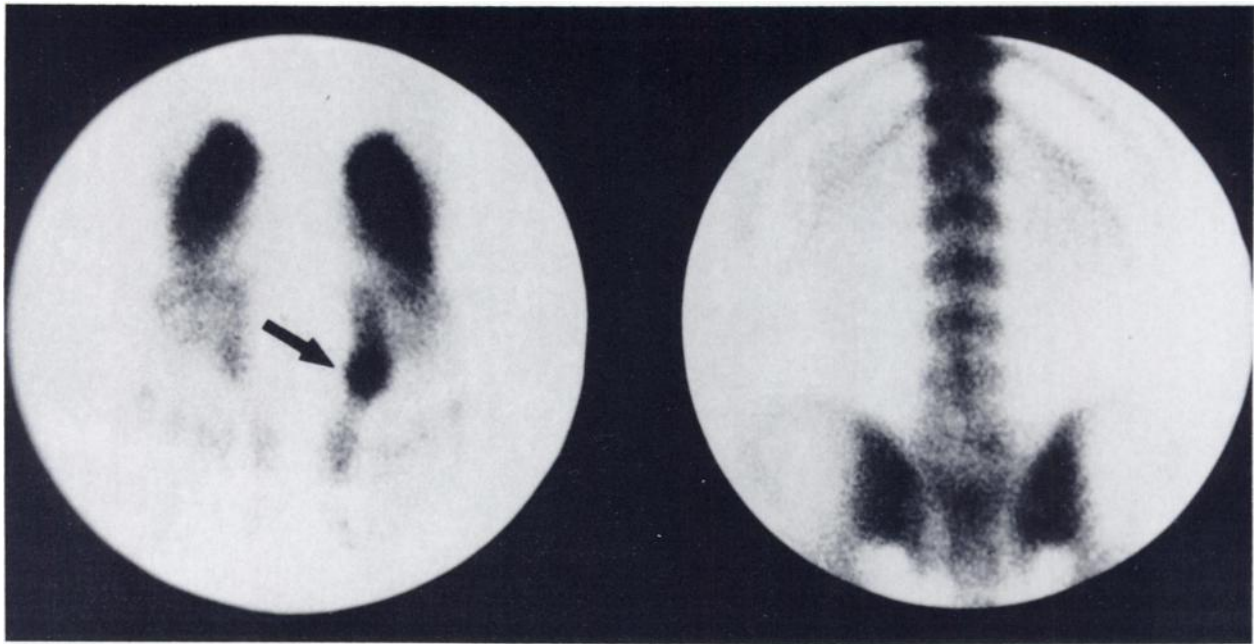


FIGURE 1
Initial [^{99m}Tc]MDP bone scan shows metatarsal stress fracture (arrow) and normal biodistribution

pharmaceuticals were applied full strength (0.66–6.6 mg/cc depending on individual kit) using prick and intradermal injection within 30 min of kit preparation. Prick testing consisted of lightly puncturing the skin through a drop of the test material. Intradermal testing was performed by injecting ~0.02 ml into the dermis using a 26-gauge needle and tuberculin syringe. Skin tests were read at 15 min and 8 hr, to exclude a later response, though the late reading was unnecessary. The volunteer control subject was reactive only to histamine. The patient showed only a minimal responsiveness to prick testing, but demonstrated a significant wheal and erythema response on intradermal testing with all diphosphonates compounds (Table 1). The largest reaction was seen with the methylene diphosphonate agent which caused the

more severe systemic response with the patient's second bone scan. A mild wheal was elicited by two pyrophosphate agents and pertechnetate, but no erythema was noted suggesting that pertechnetate, tin compounds, or other compounds common to all the kits were not responsible for the patient's systemic reaction. The relative lack of responsiveness to pyrophosphates suggested it might be safe to use this agent in the face of a documented severe adverse reaction to diphosphonates. A follow-up bone scan was performed with 20.0 mCi of [^{99m}Tc] pyrophosphate 3 wk after the patient's second diphosphonate study without adverse reaction (Fig. 2).

DISCUSSION

An adverse reaction to a radiopharmaceutical is defined by Shani et al. (5) as "an unanticipated physiologic response of the patient to the vehicle carrying the radiation, not the radiation itself." From 1976 to 1981, 277 adverse reactions were reported to the Adverse Reactions Registry, a cooperative venture of the United States Pharmacopoeia, the Society of Nuclear Medicine, and the Food and Drug Administration (1,2). Twenty-two of these reactions were due to [^{99m}Tc]MDP with 12 considered probable, eight possible, and two unlikely. The most common probable reaction (8/22) was a delayed or late-onset rash, appearing 4 to 24 hr after injection. Although no previously reported reaction to [^{99m}Tc] diphosphonates has been comparable in severity to that noted in our patient, it is interesting that there was also a significant delay between injection of diphosphonate and development of our patient's most severe symptoms.

Our patient developed a severe systemic reaction requiring hospitalization on two occasions after admin-

TABLE 1
Radiopharmaceutical Skin Testing Results

	Wheal size and erythema (E) in mm	
	Prick	Intradermal
Normal saline	0	0
Histamine	8 × 20 (20 × 20 E)	10 × 15 (30 × 30 E)
^{99m} TcO ₄	0	10 × 10
[^{99m} Tc]PPi [*]	0	5 × 6
[^{99m} Tc]PPi [†]	5 × 5	8 × 8
[^{99m} Tc]MDP [‡]	0	8 × 10 (22 × 24 E)
[^{99m} Tc]HDP [§]	0	8 × 10 (18 × 19 E)
[^{99m} Tc]MDP [¶]	5 × 6 (10 × 15 E)	8 × 8 (15 × 20 E)

* Sodium pyrophosphate-TechneScan PYP (Mallinckrodt).

† Sodium (pyro- and trimeta-) phosphates-Pyrolite (Dupont-NEN Medical Products).

‡ Medronate disodium-Osteolite (DuPont-NEN Medical Products).

§ Oxidronate sodium-Osteoscan-HDP (Mallinckrodt).

¶ Medronic acid-MDP-Squibb (Squibb).

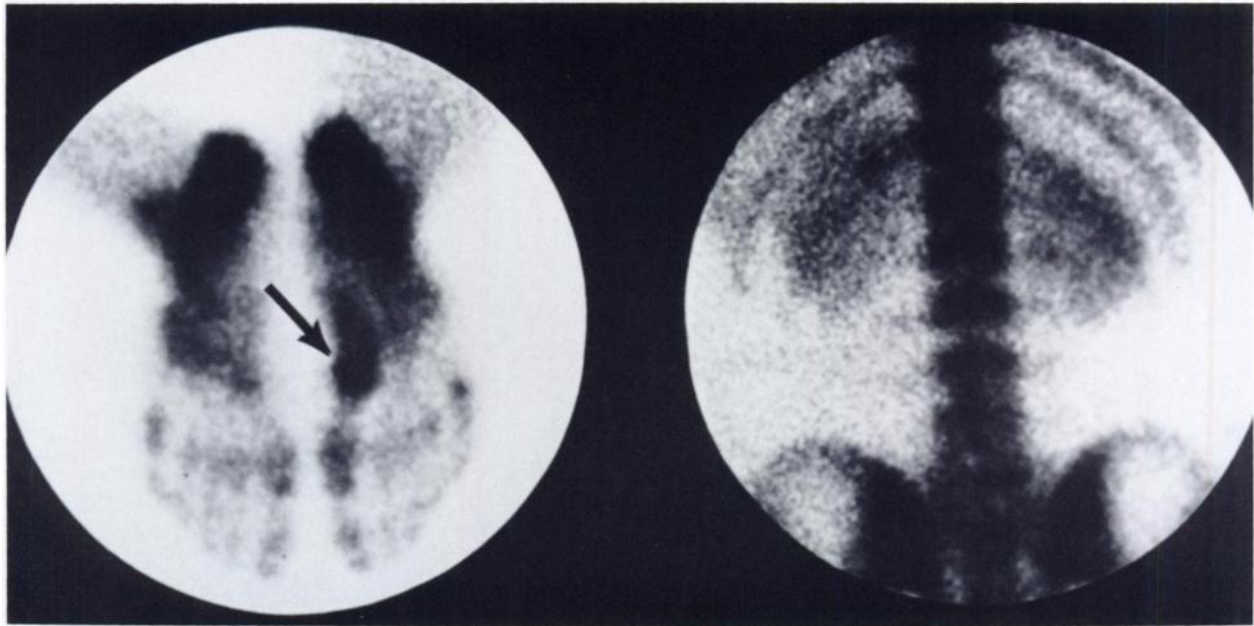


FIGURE 2
 $[^{99m}\text{Tc}]$ Pyrophosphate bone scan shows decreased bone to soft tissue ratio compared to diphosphonate study, but is diagnostic for stress fracture (arrow)

istration of two chemically similar commercial bone agents ($[^{99m}\text{Tc}]$ MDP and $[^{99m}\text{Tc}]$ HDP). No alternative explanation for these illnesses could be found and the same adverse response on rechallenge confirms the diagnosis. An acute reaction to pyrogen is implausible as no reaction was seen in other patients injected from the same kits before and after this patient. Pyrogen reactions are also exceedingly rare owing to the extreme precautions routinely taken in the preparation of modern commercial radiopharmaceutical kits which frequently include use of the very sensitive limulus amoebocyte lysate gelation test for pyrogens (6,7). In addition, radiopharmaceuticals do not provide adequate growth conditions for bacteria or fungi (8).

Skin testing is an accepted technique for evaluating suspected allergy to a wide range of compounds though we are not aware of any previous use for evaluating reactions to radiopharmaceuticals (9). In our patient, intradermal skin testing, yielding a significant wheal and flare response, correlated well with systemic reactivity to diphosphonates. A negative skin test does not completely exclude the possibility of a significant reaction; however, the lack of response to skin testing with tin, pertechnetate, common kit contents, and pyrophosphate suggested these were not offending agents and that pyrophosphate might be safely used in the face of documented diphosphonate allergy. Our patient's response and skin testing also demonstrated cross reactivity to several diphosphonate compounds and it would not appear reasonable or safe to substitute a chemically distinct but similar agent when dealing with suspected diphosphonate allergy.

CONCLUSIONS

We conclude that (a) severe systemic reactions to diphosphonate bone imaging agents do occur, but are probably exceedingly rare, (b) cross reactivity among chemically similar diphosphonate compounds is likely, (c) intradermal skin testing may correlate well with systemic reactivity and predict allergic response, and (d) pyrophosphate may be a safe, alternative bone imaging agent in patients proven or suspected allergic to diphosphonate compounds.

FOOTNOTES

- * Medronic Acid-MDP, Squibb, New Brunswick, NJ.
- * Mallinckrodt, St. Louis, MO (oxidronate sodium-osteoscan-HDP).

REFERENCES

1. Cordova MA, Hladik WB, Rhodes BA: Validation and characterization of adverse reactions to radiopharmaceuticals. *Noninvasive Med Imag* 1:17-24, 1984
2. Moore M, Rhodes BA: Adverse reactions to radiopharmaceuticals. *J Nucl Med* 23:550-551, 1982
3. Keeling DH, Sampson CB: Adverse reactions to radiopharmaceuticals. United Kingdom 1977-1983. *Br J Radiol* 57:1091-1096, 1984
4. Atkins HL, Hauser W, Richards P, et al: Adverse reactions to radiopharmaceuticals. *J Nucl Med* 13:232-233, 1972
5. Shani J, Atkins HL, Wolf W: Adverse reactions to

- radiopharmaceuticals. *Semin Nucl Med* 6:305-328, 1976
6. Rhodes BA, Cordova MA: Adverse reactions to radiopharmaceuticals: Incidence in 1978, and associated symptoms. Report of the adverse reactions subcommittee of the Society of Nuclear Medicine. *J Nucl Med* 21:1107-1110, 1980
 7. Murata H, Kobayashi M, Iio M, et al: Sensitivity of the limulus test and inhibitory factors in the radiopharmaceuticals. *J Nucl Med* 17:1088-1092, 1976
 8. Abra RM, Bell NDS, Horton PW: The growth of microorganisms in some parenteral radiopharmaceuticals. *Int J Radiopharm* 5:187-193, 1980
 9. Barbee RA, Lebowitz MD, Thompson HC, et al: Immediate skin test reactivity in the general population sample. *Ann Intern Med* 84:129-133, 1976