

# Hyperthyroidism Caused by a Toxic Intrathoracic Goiter with a Normal-Sized Cervical Thyroid Gland

R. Prakash, N. Lakshmipathi, A. Jena, V. Behari, and M.K. Chopra

*Medical Division, Institute of Nuclear Medicine and Allied Sciences, Delhi, India*

The rare presentation of hyperthyroidism caused by an intrathoracic goiter with a normal-sized cervical thyroid gland is described. The toxic intrathoracic goiter demonstrated avid uptake of [ $^{131}\text{I}$ ] and [ $^{99\text{m}}\text{Tc}$ ]pertechnetate, with comparatively faint isotopic accumulation seen in the cervical thyroid. A chest roentgenogram and radioisotope scan should be mandatory in cases of hyperthyroidism having no cervical thyroid enlargement to explore the possibility of a toxic intrathoracic goiter.

*J Nucl Med* 27:1423–1427, 1986

**I**ntrathoracic goiter most commonly presents as a superior mediastinal mass and accounts for ~ 10% of all mediastinal masses (1,2). Pathological studies have shown that intrathoracic goiters almost always occur as a result of inferior extension of thyroid tissue in the neck (3). The connection between intrathoracically placed goiters and the cervical gland is clearly demonstrable in the majority of cases (4,5), which are classified as secondary intrathoracic goiters. Completely separated, aberrant, or primary intrathoracic goiters arise from ectopic tissue which has separated from the gland proper during embryonic life and descended into the mediastinum (6,7).

Intrathoracic goiters may be asymptomatic and discovered incidentally, but may cause clinical symptoms due to pressure on adjacent structures as the goiter enlarges within the rigid thoracic inlet (8). These goiters are usually nontoxic nodules; hyperthyroidism has been reported to be an unusual accompaniment ranging from 0 to 15% in recent series (4,5). However, all these reported cases had enlarged thyroid glands in the neck.

We report a case of intrathoracic goiter causing hyperthyroidism and feedback suppression of a normal-sized cervical thyroid gland. Radioisotope scans showed faint continuity of the intrathoracic mass with the lower pole of the right lobe of the thyroid. A review of the literature is presented.

## CASE REPORT

A 52-yr-old female presented with a 4-mo history of weakness, weight loss in spite of a normal appetite, and two episodes of hemoptysis. There were associated symptoms of increased bowel frequency, nervousness, palpitations, insomnia, and tremulousness.

Physical examination revealed a slightly overweight female in no distress, blood pressure was 140/90 mmHg supine, pulse 96 and regular. Her skin was warm and moist, and she had fine finger tremors. A mild lid lag and lid retraction was evident on the right side. There was no palpable goiter.

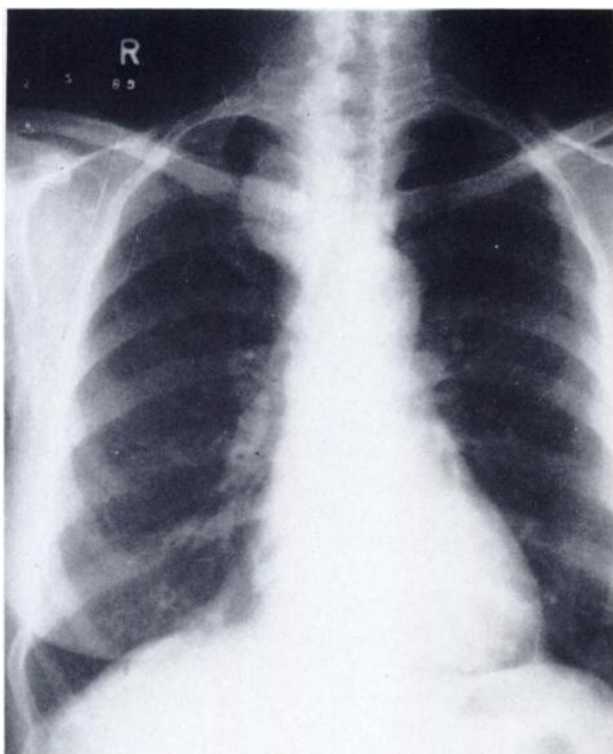
Chest x-ray (Figs. 1 and 2) showed a 6 × 5 cm diameter mass in the right superior middle mediastinum with central calcification. There was no significant tracheal compression or displacement.

Laboratory investigations confirmed the clinical diagnosis of hyperthyroidism. Thyroid hormone estimation done by radioimmunoassay showed serum total triiodothyronine level of 390 ng/dl (normal range 70–220 ng/dl) and serum thyroxine of 21 µg/dl (normal 5–13.5).

Thyroid radioactive iodine uptake (RAIU) was measured over the neck with a single channel analyzer and as per IAEA recommendations (9). The uptake after oral administration of 25 µCi iodine-131 ( $^{131}\text{I}$ ) was 15% at 2 hr and 34% at 24 hr. A gamma camera thyroid scan was done at 24 hr (Fig. 3) using an 8-mm aperture pinhole collimator positioned 7 cm above the suprasternal notch. A 10-min count image showed a functioning intrathoracic goiter on the right side in the position corresponding to that of the mediastinal mass observed on the chest x-ray. The central area had reduced activity consistent with degeneration. Faint radioactivity was observed in the normal-sized cervical thyroid. Iodine-131 uptake measured with the probe now focused over the mediastinal mass was 32%.

Received Oct. 7, 1985; revision accepted Mar. 31, 1986.

For reprints contact: Rajeev Prakash, MD, Scientist 'C', Institute of Nuclear Medicine and Allied Sciences, Probyn Rd., Delhi-110 007, India.



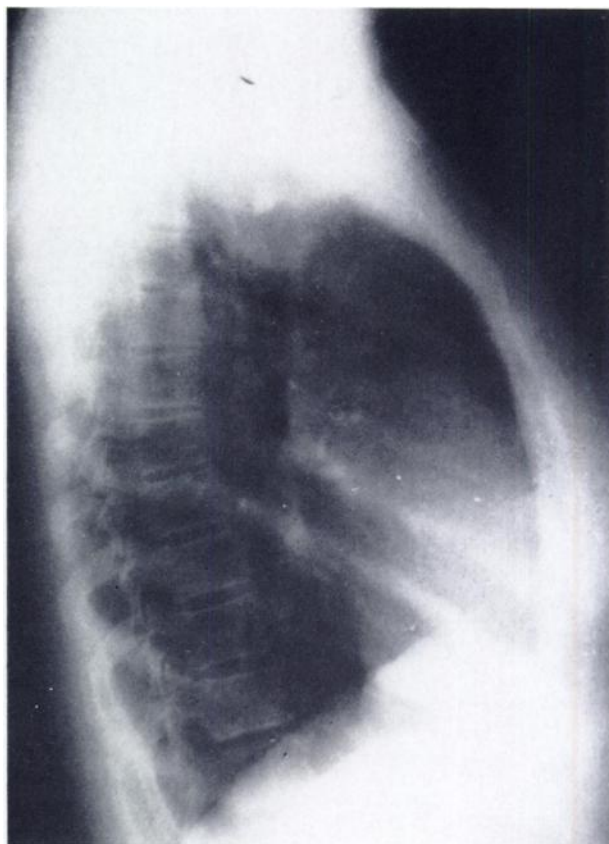
**FIGURE 1**  
Posteroanterior roentgenogram shows homogenous mass in superior mediastinum to right of midline producing minimal impression on trachea with no significant displacement

A technetium-99m ( $^{99m}\text{Tc}$ ) pertechnetate thyroid scan was obtained after i.v. administration of 5 mCi of the radionuclide. A 400,000-count pinhole image showed intense isotopic uptake in the intrathoracic nodule with few central areas of reduced, patchy uptake suggestive of multinodularity (Fig. 4). Comparatively faint accumulation of the radionuclide was seen in the cervical thyroid.

A diagnosis of hyperthyroidism due to a hyperfunctioning intrathoracic goiter with a normal-sized cervical thyroid gland was made. The patient was initially treated with graded doses of carbimazole with good improvement. As there was no obvious tracheal compression, nor any pressure symptoms, she was subsequently treated with 15 mCi of [ $^{131}\text{I}$ ]sodium iodide. Four months after radioiodine therapy the patient was clinically and biochemically euthyroid (triiodothyronine 200 ng/dl, thyroxine 12  $\mu\text{g/dl}$ ).

## DISCUSSION

Intrathoracic goiter is one of the major considerations in the evaluation of superior mediastinal masses. Substernal and partial intrathoracic goiters generally represent intrathoracic extensions of cervical thyroid tissue (10); 75–80% of these masses descend into the anterior mediastinum while the remainder descend into the posterior mediastinum (11) with middle mediastinal goiters being rarely encountered. Completely separated,

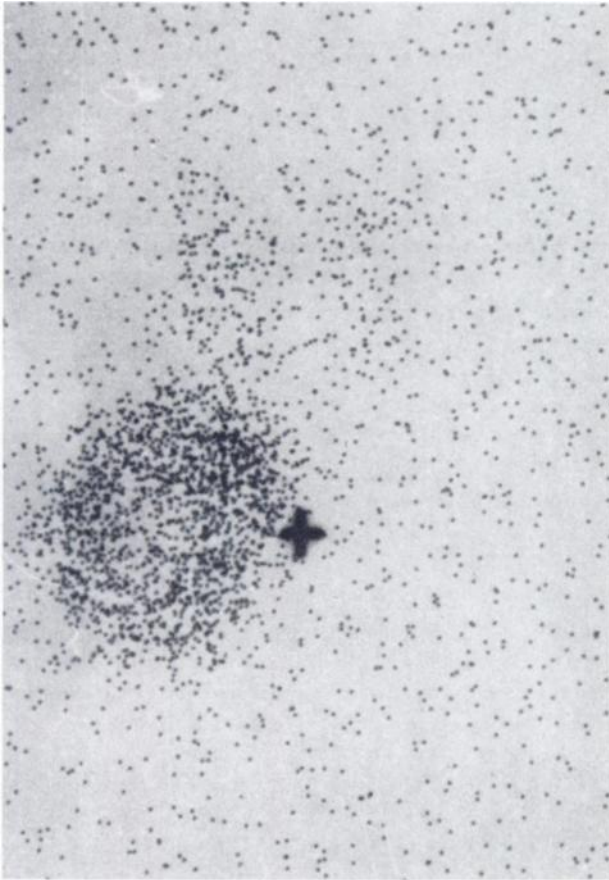


**FIGURE 2**  
Lateral view demonstrates mass to be in middle mediastinum with evidence of central calcification. There is no significant tracheal compression

ectopic or so-called primary intrathoracic goiters are extremely rare (6,12) and presumably originate from fragmented embryonic thyroid tissue that has descended into the mediastinum (7).

Intrathoracic goiters occur most commonly in the fifth decade of life (10) with a female predilection of 3 to 4:1 (5). These may be completely asymptomatic in 15–50% of cases (3,13). Clinical manifestations include hoarseness, cough, dyspnoea, and stridor (5,10,14) and dysphagia may occur in 1/3 of cases. The rarer presentations include superior vena cava syndrome (15), hypertension (16), and hyperthyroidism (17).

Earlier reports have shown that fewer than 10% of substernal goiter patients had elevations in thyroid hormone levels (4). More recent series have shown only an occasional hyperthyroid patient (10,18). However, all these patients had associated cervical thyroid enlargement and could be classified as having secondary intrathoracic goiters. In the case cited by Ng Tang Fui et al. (18) it is obvious on the thyroid scan performed after radioiodine therapy that the intrathoracic goiter was an extension of the enlarged left lobe of the thyroid gland. Our patient presented with classic features of hyperthyroidism, confirmed by thyroid function tests. Thyroid

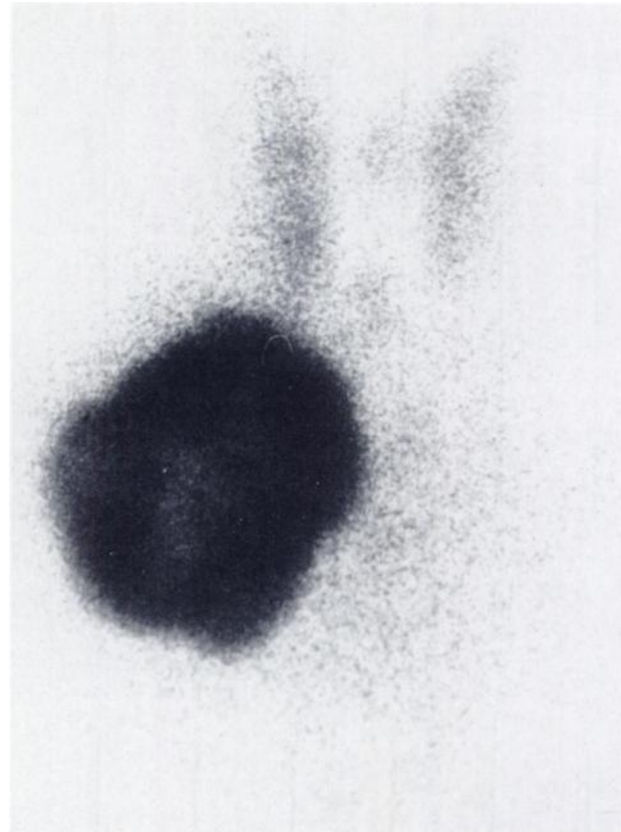


**FIGURE 3**  
Iodine-131 thyroid scan shows hyperfunctioning intrathoracic goiter on right side with comparatively faint uptake in normal-sized cervical thyroid

scan conclusively demonstrated a normal-sized thyroid gland with increased uptake in the intrathoracic goiter located in the superior mediastinum.

The diagnostic procedures currently in use for evaluation of intrathoracic goiter include chest radiography (19), radionuclide scintigraphy (20), transmission computed tomography (21), as well as invasive techniques such as angiography and mediastinoscopic biopsy. The routine chest x-ray is a valuable initial study for compartmental localization of a mediastinal mass and also demonstrates tracheal displacement or compression and areas of calcification. Computerized tomography of intrathoracic goiter can note continuity of the mediastinal mass with the cervical gland, well-defined borders, focal calcifications, high contrast attenuation values of the goiter and postcontrast enhancement.

Radionuclide scintigraphy is capable of detecting most intrathoracic goiters (6,22) and  $^{131}\text{I}$  scanning has been recommended in all mediastinal masses regardless of their location (13). The  $^{131}\text{I}$  scan is preferred over other radioisotopes for demonstration of intrathoracic goiter. The low-energy photons of  $^{123}\text{I}$  are absorbed by the thoracic bony structures overlying the goiter, and



**FIGURE 4**  
Technetium-99m pertechnetate thyroid scan shows avid uptake by intrathoracic nodule with central patchy areas. Faint continuity with right lower pole of cervical thyroid is seen

in  $^{99\text{m}}\text{Tc}$  images the high blood background from the cardiovascular blood pool can interfere with the scan quality and visualization of a retrosternal thyroid. The role of isotopes is, however, controversial as negative thyroid scans in retrosternal goiter may occur when there is too little uptake of radioiodine by the goiter (10,23). Furthermore, accumulation of these isotopes in an intrathoracic location is not specific for goiter as [ $^{99\text{m}}\text{Tc}$ ]pertechnetate uptake has been reported in substernal parathyroid adenoma (24) and also in an anterior mediastinal thymoma (25). Iodine-131 mediastinal uptake has also been noted in two cases of bronchiogenic carcinoma (26,27). However, in the present case the clinical features in combination with high thyroid hormone levels and isotopic uptake in the intrathoracic goiter with near-total suppression of the cervical thyroid were diagnostic of a toxic intrathoracic goiter.

Scintigraphy provides an excellent estimate of the functional status of a mediastinal goiter. The majority of such goiters are nontoxic nodules, with the rare case being associated with hyperthyroidism. Autonomous nodules produce hyperthyroidism when the secretory activity exceeds levels necessary to suppress TSH re-

lease; thus the completeness of suppression of extranodular tissue on a thyroid scan is a valuable index of their secretory activity (28). Our case presumably presented early in the development of hyperthyroidism in the intrathoracic goiter which had not yet produced complete feedback suppression of the cervical thyroid. However, the possibility of low degree autonomous function in the cervical thyroid also contributing to the hyperthyroid state cannot be ruled out.

Intrathoracic goiters are generally considered an indication for surgery (5), especially in hyperthyroidism, as radioiodine rarely relieves tracheal deviation or compression even though the hyperthyroid state may be controlled (29). However, this patient did not have significant tracheal deviation or compression symptoms and was treated with radioiodine after stabilization with antithyroid drugs. Serial follow-up over 4 mo has shown definite clinical and biochemical improvement.

Diffuse and nodular toxic goiters account for more than 90% of the hyperthyroidism seen in practice. The less common causes of hyperthyroidism include struma ovarii (30), metastatic well-differentiated thyroid cancer (31), subacute thyroiditis (32), and overproduction of a thyroid stimulating hormone (33). The possibility of hyperthyroidism due to struma ovarii should be considered whenever ascites or a palpable ovarian mass is noted in association with hyperthyroidism. A cervical multinodular goiter is usually present. The diagnosis can be confirmed by showing radioactive iodine uptake (RAIU) over the pelvic mass. Suppression of thyroid RAIU may not necessarily occur since hyperplastic tissue is frequently present in both the cervical and pelvic areas (33). Metastatic papillofollicular cancer is also clinically obvious since most patients have had previous thyroid surgery for cancer and have extensive metastases to bone, lung, and liver. Thyroid RAIU is low and the diagnosis is confirmed by demonstrating uptake over the metastases. Subacute thyroiditis presents with typical features of thyroid tenderness, fever, palpitations, and heat intolerance. Thyroid hormone levels are invariably increased in the acute phase with markedly depressed thyroid RAIU. Overproduction of a thyroid stimulating hormone producing diffuse goiter and hyperthyroidism with increased thyroid uptake is present in metastatic trophoblastic malignancies and TSH-producing pituitary tumors.

As these cases are rare, it has been suggested that a hyperthyroid patient with either a diffuse goiter or no palpable thyroid abnormality can be presumed to have Graves' disease (34). Our case demonstrates that presence of hyperthyroidism with a high radioiodine uptake in the neck but without cervical thyroid enlargement would suggest that the radiation is coming from the upper chest. In such cases a chest roentgenogram followed by radionuclide scanning should be performed to explore the possibility of an intrathoracic goiter.

## REFERENCES

- Daniel RA Jr., Diveley WL, Edwards WH, et al: Mediastinal tumors. *Ann Surg* 151: 783-795, 1960
- Benjamin SP, McCormack LJ, Effler DB, et al: Primary tumors of the mediastinum. *Chest* 62:297-303, 1972
- Sweet RH: Intrathoracic goiter located in the posterior mediastinum. *Surg Gynecol Obstet* 89:57-66, 1949
- Lamke LO, Bergdahl L, Lamke B: Intrathoracic goitre: A review of 29 cases. *Acta Chir Scand* 145:83-86, 1979
- Allo MD, Thompson NW: Rationale for the operative management of substernal goiters. *Surgery* 94:967-977, 1983
- Falor WH, Kelley TR, Krabill WS: Intrathoracic goiter. *Ann Surg* 142:238-247, 1955
- Dundas P: Intrathoracic aberrant goiter. *Acta Chir Scand* 128:729-736, 1964
- Katlick MR, Wang C, Grillo HC: Substernal goiter. *Ann Thorac Surg* 39:391-399, 1985
- Calibration and standardization of thyroid radioiodine uptake measurements. Recommendations drawn up at a consultants meeting 1960, convened by the International Atomic Energy Agency. *Acta Radiol* 58:233-240, 1962
- Sand ME, Laws HL, McElvein RB: Substernal and intrathoracic goiter: Reconsideration of surgical approach. *Am Surg* 49:196-202, 1983
- Frazer RG, Pare JAP, eds: Diseases of the mediastinum. In *Diagnosis of Diseases of the Chest*. Philadelphia, WB Saunders, 1978, pp 1793-1870
- Kaplan WD, Watnick M, Holman BL: Scintigraphic identification of complete thoracic goiter with normal appearing cervical thyroid: A case report. *J Can Assoc Radiol* 25:193-195, 1974
- Irwin RS, Braman SS, Arvantidis AN, et al: <sup>131</sup>I thyroid scanning in preoperative diagnosis of mediastinal tumor. *Ann Intern Med* 89:73-74, 1978
- Wakeley CPG, Mulvany JH: Intrathoracic goiter. *Surg Gynecol Obstet* 70:702-710, 1940
- Sy WM, Lao RS, Seo IS: Scintigraphic features of superior vena caval obstruction due to substernal nontoxic goitre. *Br J Radiol* 55:301-303, 1982
- Holden MP, Wooler GH, Ionescu MI: Massive retrosternal goitre presenting with hypertension. *Thorax* 27:772-774, 1972
- Lahey FH: Intrathoracic goiter (secondary hyperthyroidism). *Surg Clin North Am* 1:641-662, 1921
- Ng Tang Fui S, Prior J, Saunders AJ, et al: Posterior intrathoracic goitre as a cause of thyrotoxicosis. *Br J Radiol* 52:995-997, 1979
- Grainger RG, Pierce JW: Mediastinal lesions. In *A Textbook of Radiology and Imaging*, Sutton D, ed. Edinburgh, Churchill Livingstone, 1980, pp 390-404
- Cawthon MA, Hartshorne MF, Karl RD, et al: Tomographic scintigraphy of a retrotracheal goiter. *Clin Nucl Med* 9:45-46, 1984
- Bashisht B, Ellis K, Gold RP: Computed tomography of intrathoracic goiters. *Am J Roentgenol* 140:455-460, 1983
- Salvatore M, Gallo A: Accessory thyroid in the anterior mediastinum: Case report. *J Nucl Med* 16:1135-1136, 1975
- Shih W-J, Cho S-R, Purcell M, et al: Diagnostic imaging in mediastinal tumor. *Clin Nucl Med* 9:702-707, 1984

24. Naunheim KS, Kaplan EL, Kirchner PT: Preoperative technetium-99m imaging of a substernal parathyroid adenoma. *J Nucl Med* 23:511-513, 1982
25. Wilson RL, Cowan RJ: Tc-99m pertechnetate uptake in a thymoma: Case report. *Clin Nucl Med* 7:149-150, 1982
26. Fernandez-Ulloa M, Maxon HR, Mehta S: Iodine-131 uptake by primary lung adenocarcinoma—misinterpretation of <sup>131</sup>I scan. *JAMA* 236:857-858, 1976
27. Acosta J, Chitkara R, Khan F, et al: Radioactive iodine uptake by a large cell undifferentiated bronchiogenic carcinoma. *Clin Nucl Med* 7:368-369, 1982
28. Hamburger JI: Solitary autonomously functioning thyroid lesions; Diagnosis, clinical features and pathogenetic considerations. *Am J Med* 58:740-748, 1975
29. Beierwaltes WH: The treatment of hyperthyroidism with iodine-131. *Semin Nucl Med* 8:95-103, 1978
30. Kempers RD, Dockerty MB, Hoffman DL, et al: Struma ovarii—ascitic, hyperthyroid, and asymptomatic syndromes. *Ann Intern Med* 72:883-893, 1970
31. Chapman CN, Sziklas JJ, Spencer RP, et al: Hyperthyroidism with metastatic follicular thyroid carcinoma. *J Nucl Med* 25:466-468, 1984
32. Teixeira VL, Romaldini JH, Rodrigues HF, et al: Thyroid function during the spontaneous course of subacute thyroiditis. *J Nucl Med* 26:457-460, 1985
33. Hamilton CR, Maloof F: Unusual types of hyperthyroidism. *Medicine* 52:195-215, 1973
34. Dorfman SG: Hyperthyroidism: Usual and unusual causes. *Arch Intern Med* 137:995-996, 1977