Poor Results with Technetium-99m (V) DMS and Iodine-131 MIBG in the Imaging of Medullary Thyroid Carcinoma

Thomas E. Hilditch, John M.C. Connell, Alex T. Elliott, Thomas Murray, and Nicholas S. Reed

West of Scotland Health Boards, Department of Clinical Physics and Bio-Engineering; and MRC Blood Pressure Unit, West of Scotland Radionuclide Dispensary, and Glasgow Institute of Radiotherapeutics and Oncology, Western Infirmary, Glasgow, Scotland

The value of [^{99m}Tc(V)]DMS and [^{131}I]MIBG in imaging medullary carcinoma of the thyroid was investigated in five patients. Results with [^{99m}Tc(V)]DMS were negative in all five patients as well as with [^{131}I]MIBG in four patients; however, there was significant tumor uptake in one patient with [^{131}I]MIBG.

J Nucl Med 27:1150–1153, 1986

In most cases of medullary carcinoma of the thyroid (MCT) there is no uptake of radioiodide or technetium-99m (^{99m}Tc) pertechnetate in the affected areas (*1*), consistent with the fact that MCT arises from the calcitonin-secreting parafollicular cells in the thyroid which are not involved in thyroid hormone synthesis. In some cases, however, MCT has been found to concentrate iodide and there have been reports of treatment of MCT with iodine-131 (^{131}I) iodide (*2,3*). It has been suggested that in such cases there may be two tumor components, one of medullary cell-type and the other of follicular cell-type, the latter resulting in radioiodide uptake (*4*). Immunocytochemical studies, however, have suggested that some MCT cells produce both calcitonin and thyroglobulin (*5,6*). While the derivation of such pluripotent cells is unclear, trapping of iodide in this cell-type might be expected.

A number of other radiopharmaceuticals, such as [^{99m}Tc]phosphates and thallium-201-thallous chloride, may be of use, occasionally, in the localization of MCT (*2*). Two additional radiopharmaceuticals have been introduced recently—[^{131}I]metaiodobenzylguanidine ([^{131}I]MIBG), which is useful in the detection of pheochromocytoma and other neoplasms of neuroectodermal origin (*7*), and [^{99m}Tc(V)]dimercaptosuccinic acid ([^{99m}Tc(V)]DMS), in which the ^{99m}Tc core exhibits characteristics comparable to the orthophosphate ion (*1*). Both have been reported to be valuable in localizing MCT (*1,8–12*). We describe a comparative study of these two radiopharmaceuticals in a small series of patients with MCT.

MATERIALS AND METHODS

Each patient was given a thyroid blocking dose of 60 mg potassium iodide twice daily, commencing 24 hr before the start of the study and continuing throughout its duration.

Imaging with [^{99m}Tc(V)]DMS was performed first. The radiopharmaceutical was prepared as described previously (*1*) making use of a commercial lyophilized kit which had been transported and stored in accordance with the supplier's instructions.* Each patient received 2–3 mCi [^{99m}Tc(V)]DMS intravenously with imaging being performed 2 hr later using a gamma camera. Anterior and posterior views of the whole trunk were acquired. At 48 hr, the patient was given 0.5 mCi [^{131}I]MIBG intravenously and imaging was performed after another interval of 48 hr. In one patient, imaging had been performed 10 wk previously using [^{131}I]MIBG alone (*10*).

CASE REPORTS

Five patients with elevated calcitonin levels were investigated (Table 1). In three cases the presence of MCT was confirmed pathologically and in the remaining cases there was a family history of MEN type 2a. Two patients were known to have pheochromocytoma.

The findings with [^{99m}Tc(V)]DMS were the same in all patients with no clearly identifiable focus of uptake in the

Received Sept. 17, 1985; revision accepted Feb. 19,1986.

For reprints contact: T.E. Hilditch, PhD, Dept. of Clinical Physics and Bio-Engineering, 11 West Graham St., Glasgow G4 9LF, Scotland.

TABLE 1
Details of Patients Studied

Patient no.	Age	Sex	Known kindred MEN type 2a	Adrenal status	Thyroid status	Plasma calcitonin level at time of imaging (ng/l)*
1	65	F	No	Normal circulating catecholamines	Thyroidectomy 8yr ago: Histology confirmed MCT†	10,000
2	40	M	Yes	Normal circulating catecholamines	Thyroidectomy 5yr ago: Histology confirmed MCT†	138
3	40	M	Yes	Bilateral pheochromocytoma	—	140
4	21	M	Yes	Normal circulating catecholamines	—	240
5	63	F	Yes	Bilateral pheochromocytoma	Thyroidectomy after imaging study: Histology confirmed MCT	2,400

*Normal range 10–45 ng/l.
†Conventional radiological and ultrasonic examination of trunk and neck at time of radionuclide imaging did not reveal presence of tumor.

thyroid gland and surrounding areas (Fig. 1). There was slight uptake by both thyroid lobes in two patients. A large proportion of the tracer was concentrated in the kidneys, resulting in good visualization in the kidneys in all patients (Fig. 1). The remainder of the tracer was distributed fairly uniformly throughout the rest of the trunk with no obvious focus of uptake. In one case, imaging was repeated at 24 hr but the results were the same as at 2 hr.

There was no thyroidal uptake in four out of five patients with [^{131}I]MIBG nor was there any other abnormal focus of uptake except in the patients with pheochromocytoma. In one case, however, there was thyroid uptake within the left lobe of the gland (Fig. 2) which had been visualized in a previous examination (*10*). There was no uptake of [^{99m}Tc(V)]DMS at this site. Subsequent surgery and histologic examination of excised tissue confirmed this focus of MIBG uptake to be medullary carcinoma of the thyroid. The tumor was 1.8 cm in diameter and situated within the left lower lobe of the thyroid gland. Uptake in the tumor at 48 hr was 0.1% of the injected dose and the biologic half-period 40–90 days. This patient also had uptake in both adrenal glands, corresponding to known pheochromocytoma. Uptake in the right adrenal lesion was estimated to be 0.5% dose with a biologic half-period of 2.2 days. Uptake in the left lesion was considerably less. The second patient with pheochromocytoma had an uptake of 1.6% [^{131}I]MIBG in the right adrenal gland.

DISCUSSION

Unlike the original studies with [^{99m}Tc(V)]DMS (*1,8*), the present study has failed to demonstrate significant uptake of the radionuclide in MCT. The mechanism postulated for uptake of ^{99m}Tc in MCT depends

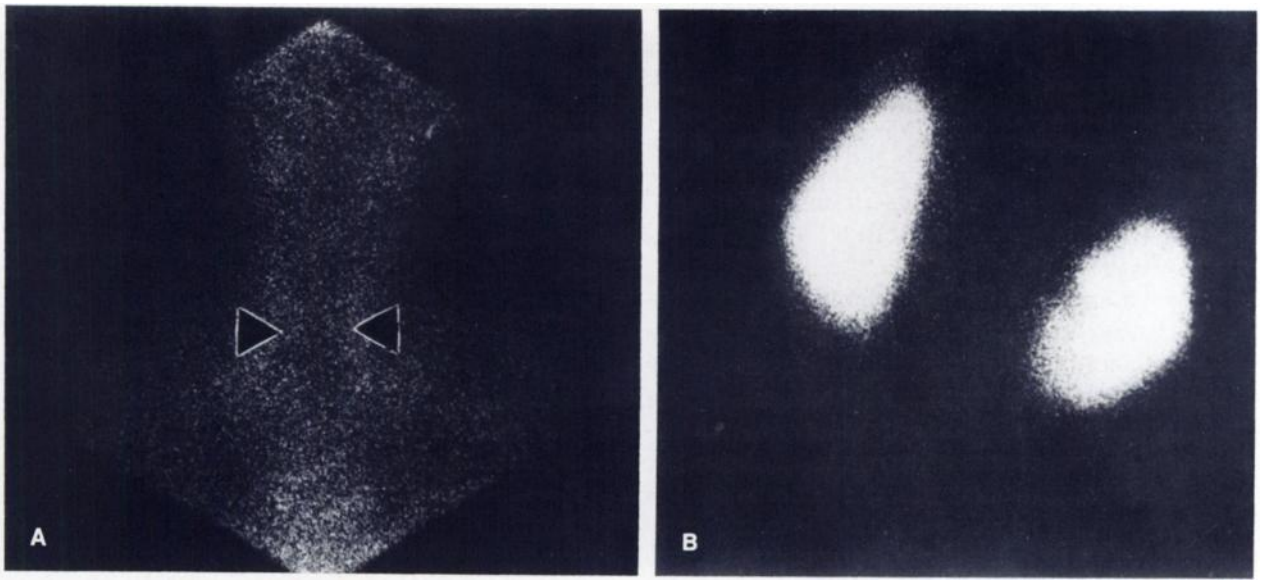

FIGURE 1
Images of thyroidal (A) and renal (B) areas using [^{99m}Tc(V)]DMS in Patient 4. Location of thyroid gland is indicated in image (A)

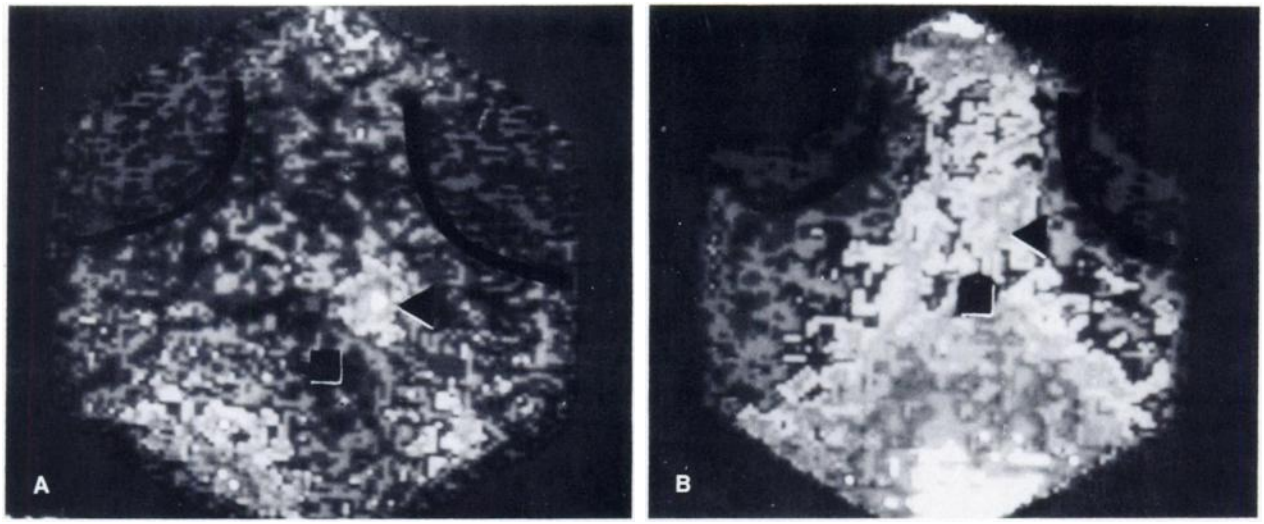

FIGURE 2
Comparison of images of thyroidal area using [^{131}I]MIBG (A) and [^{99m}Tc(V)]DMS (B) in Patient 5. These images were derived from color images and have not been enhanced. Markers indicate sites of suprasternal notch and thyroid tumor

on the presence of the dissociated TcO_4^{-3} anion in the radiopharmaceutical. This anion is structurally analogous to PO_4^{-3} which has been shown to be taken up by neoplasms, possibly as a consequence of calcification (*2*). To achieve the required degree of dissociation, the [^{99m}Tc]DMS is prepared in an alkaline medium with the amount of reducing agent ($SNCl_2$) strictly controlled. The recommended procedures for preparation were adhered to in the present study. However, whereas the studies in all five patients with MCT in the original published work were positive (*8*), the results in all five patients in this study were negative.

There were no obvious reasons for this discrepancy between the two studies, but it may be that the preparation of suitable [^{99m}Tc(V)]DMS is very sensitive to small variations in the presence of foreign constituents within the media used in preparation. Alternatively, uptake may be very dependent on the degree of calcification within the tumor and differences between patients may not be totally unexpected, although in the patient in the present series with a positive [^{131}I]MIBG result the tumor was heavily calcified. Further work is clearly necessary.

There were also negative results in four out of five patients with [^{131}I]MIBG. In one case, however, there was significant uptake by the neoplasm, observed in two separate investigations. The efficacy of thyroid blocking in the patient was checked by studies with iodine-123 iodide. Subsequent surgical excision and pathology confirmed the thyroid lesion to be MCT. The retention time of the MIBG in the thyroid lesion was much longer than that taken up by the adrenal lesions (pheochromocytoma) which were also present. Hoefnagel et al. (*13*) have reported similar findings in their study of MCT in which only one out of six patients demonstrated uptake of [^{131}I]MIBG. That patient was treated successfully with a therapeutic dose of the radiopharmaceutical. Other groups have reported uptake of MIBG by MCT in both the localized and disseminated form (*9,11,12*).

No mechanism has been proposed for the occasional uptake of MIBG in MCT. In neoplasms such as pheochromocytoma and neuroblastoma, concentration of the radiopharmaceutical is thought to be attributable to its structural similarity to noradrenaline which leads to accumulation of the material by the catecholamine reuptake mechanism present in presynaptic cells (*14–16*). Other tumors of neuroectodermal origin, namely carcinoid tumors (*17*) and nonsecreting paragangliomas (*18*), have been reported to take up MIBG. MCT has demonstrated variability with regard to other radiopharmaceuticals, such as radioiodide and [^{99m}Tc]phosphate, with occasional uptake being reported (*2*). It is likely that no one radiopharmaceutical is adequate for localizing MCT.

FOOTNOTE

* Daiichi Radioisotopes, Tokyo, Japan.

REFERENCES

1. Ohta H, Yamamoto K, Endo K, et al: A new imaging agent for medullary carcinoma of the thyroid. *J Nucl Med* 25:323–325, 1984
2. Spencer RP: Medullary thyroid carcinoma: Radiotracers in therapy and evaluation of primary or metastatic sites. *J Nucl Med* 25:514–517, 1984
3. Nusynowitz ML, Pollard E, Benedetto AR, et al: Treatment of medullary carcinoma of the thyroid with I-131. *J Nucl Med* 23:143–146, 1982

4. Spencer RP, Garg V, Raisz LG, et al: Radioiodide uptake and turnover in a pseudo-medullary thyroid carcinoma. *J Nucl Med* 23:1006–1010, 1982
5. Kameda Y, Harada T, Ito K, et al: Immunohistochemical study of the medullary thyroid carcinoma with reference to C-thyroglobulin reaction of tumour cells. *Cancer* 44:2071–2082, 1979
6. Hales M, Rosenau W, Okerlund MD, et al: Carcinoma of the thyroid with a mixed medullary and follicular pattern. *Cancer* 50:1352–1359, 1982
7. Shapiro B, Copp JE, Sisson JC, et al: Iodine-131 metaiodobenzylguanidine for the locating of suspected phaechromocytoma: Experience in 400 cases. *J Nucl Med* 26:576–585, 1985
8. Endo K, Ohta H, Sakahara H, et al: Distinctive behaviour of ^{99m}Tc (V) dimercaptosuccinic acid as a tumour-seeking agent. In *Radiopharmaceuticals and Labelled Compounds*, Vienna, IAEA, 1985, pp 201–209
9. Endo K, Shiomi K, Kasagi K, et al: Imaging of medullary thyroid cancer with ^{131}I-MIBG. *Lancet* 2:233, 1984
10. Connell JMC, Hilditch TE, Elliott AT, et al: ^{131}I-MIBG and medullary carcinoma of the thyroid. *Lancet* 2:1273–1274, 1984
11. Sone T, Fukunaga M, Otsuka N, et al: Metastatic medullary thyroid cancer: Localisation with iodine-131 metaiodobenzylguanidine. *J Nucl Med* 26:604–608, 1985
12. Poston GJ, Thomas AMK, MacDonald DWR, et al: ^{131}I-MIBG uptake by medullary carcinoma of thyroid. *Lancet* 2:560, 1985
13. Hoefnagel CA, de Kraker J, Marcuse HR, et al: Detection and treatment of neural crest tumours using I-131-meta-iodobenzylguanidine. *Eur J Nucl Med* 11:A73, 1985
14. Iverson LL: Catecholamine uptake process. *Br Med Bull* 29:130–135, 1973
15. Wieland DM, Wu J-L, Brown LE, et al: Radiolabeled adrenergic neuron-blocking agents: Adrenomedullary imaging with ^{131}I iodobenzylguanidine. *J Nucl Med* 21:349–353, 1980
16. Tobes MC, Jaques S, Wieland DM, et al: Effect of uptake-one inhibitors on the uptake of norepinephrine and metaiodobenzylguanidine. *J Nucl Med* 26:897–907, 1985
17. Fischer M, Kamanabroo D, Sanderkamp H, et al: Scintigraphic imaging of carcinoid tumours with 131-I-MIBG. *Lancet* 2:165, 1984
18. Smit AJ, Van Essen LH, Hollema H, et al: 131-I-MIBG uptake in a non-secreting paraganglioma. *J Nucl Med* 25:984–986, 1984