
Cerebral Edema Following Iodine-131 Therapy for Thyroid Carcinoma Metastatic to the Brain

Frederick L. Datz

Department of Nuclear Medicine, University of Utah School of Medicine, Salt Lake City, Utah

Brain metastases are rare in well-differentiated thyroid carcinoma but when present they can lead to the patient's death. Iodine-131 therapy for intracerebral thyroid carcinoma metastases causes radiation-induced acute cerebral edema that can lead to CNS complications and even death. We present a case in which a patient with intracerebral ¹³¹I uptake developed seizures, slurred speech, and muscle weakness 12 hr following ¹³¹I therapy. The patient's CT scan, post-therapy, confirmed an intracranial metastasis with a significant amount of surrounding edema. Radiotherapists, when using external beam radiation to treat intracerebral metastases, commonly place these patients on steroids, glycerol, or mannitol prior to instituting therapy, to prevent complications from radiation-induced cerebral edema. This technique could be applied to ¹³¹I therapy of intracranial thyroid carcinoma metastases as well.

J Nucl Med 27:637-640, 1986

Papillary, follicular, or mixed tumors account for the vast majority of thyroid cancers. Although 90% of patients with papillary carcinoma have tumor involving regional nodes at the time of initial diagnosis, distant metastases are rare, occurring in only 1% (1). Four to twenty percent develop distant metastases over the course of their disease. Follicular carcinomas have a higher incidence of distant spread, both at the time of initial presentation and subsequently. Most distant metastases of well-differentiated thyroid carcinoma are to the lungs and bone. These metastases can be effectively treated with iodine-131 (¹³¹I) therapy (2).

The brain is a relatively rare site for well differentiated thyroid carcinoma (1,3). However, of patients that die of thyroid carcinoma, brain metastases are more common and not infrequently are the cause of death (4,5).

Early complications of ¹³¹I therapy for metastatic thyroid carcinoma are primarily radiation sickness, sialoadenitis, transient bone marrow suppression, and pain in the metastasis following treatment (6). However, we recently treated a patient with a brain metastasis who, 12 hr following therapy, developed seizures, slurred speech, and muscle weakness secondary to ra-

diation-induced cerebral edema. A description of the case follows with suggestions on how to prevent central nervous system (CNS) complications of ¹³¹I therapy.

CASE REPORT

A 66-yr-old female was in good health until 14 yr previously when a nodule was found in the right lobe of her thyroid. A right thyroid lobectomy was performed and the histology was interpreted as benign. Five years later, the patient developed a pathologic fracture of the left humerus. A biopsy showed well-differentiated papillary-follicular carcinoma. The patient then underwent a total thyroidectomy. A subsequent ¹³¹I scan revealed intense uptake in the humerus which was treated with a total of 900 mCi over the next 3 yr. The metastatic lesion continued to progress however, and the patient underwent amputation. Two years later, the patient developed lung nodules on chest x-ray. A repeat whole-body ¹³¹I scan was then performed 6 wk after the patient stopped thyroid medication (the TSH was 90 μ IU/ml).

The scan revealed widespread metastatic disease involving the lung, mediastinum and distal femur (Fig. 1). Two foci of increased uptake were also present in the left and right parietal areas (Fig. 2). Skull films were normal in the parietal areas, although a lytic lesion was present in the occipital region. A computed tomographic (CT) scan was recommended to determine if the uptake seen in the head was osseous or intracranial but the patient refused.

The patient was admitted to the hospital and treated with 200 mCi of ¹³¹I. Twelve hours after institution of therapy, the

Received Sept. 16, 1985; revision accepted Dec. 31, 1985.

For reprints contact: Frederick L. Datz, MD, Associate Professor of Radiology, Clinical Director of Nuclear Medicine, University of Utah Health Sciences Center, 50 North Medical Dr., Salt Lake City, UT 84132.

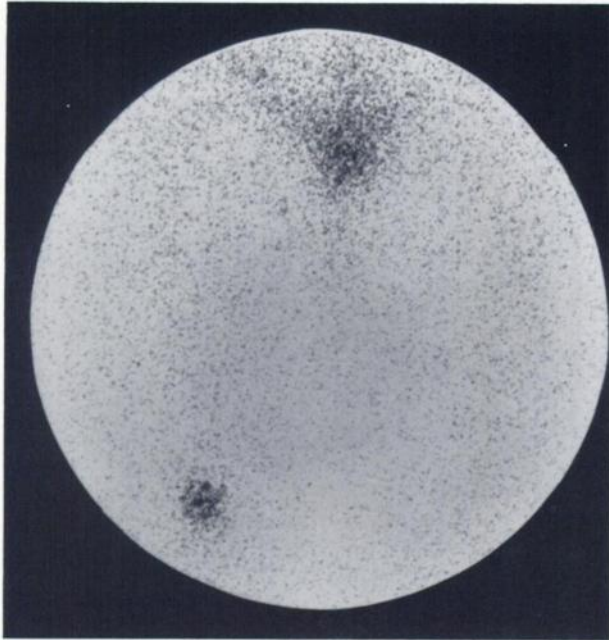


FIGURE 1
Iodine-131 scan over femurs. Increased uptake in osseous metastasis is seen at distal portion of right femur

patient had a focal clonic seizure involving the right upper extremity and face. She subsequently developed slurring of her speech and weakness on her right side. The patient was treated acutely with i.v. valium, dilantin, and decadron. A plain and enhanced head CT scan performed the next day revealed an enhancing lesion of the left temporal parietal area with a large amount of associated edema and mass effect (Fig. 3). There was no evidence of acute bleeding in the area of the metastasis or elsewhere in the brain. No definite abnormality

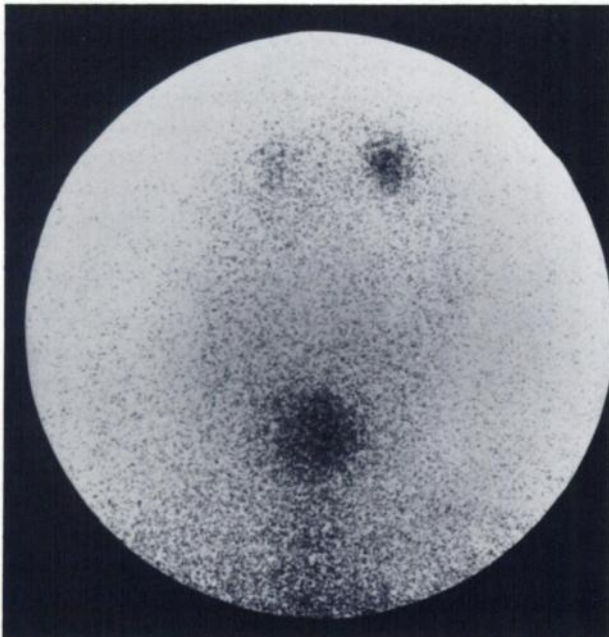


FIGURE 2
Iodine-131 scan over anterior skull shows increased uptake in left and right parietal areas, more intense on left

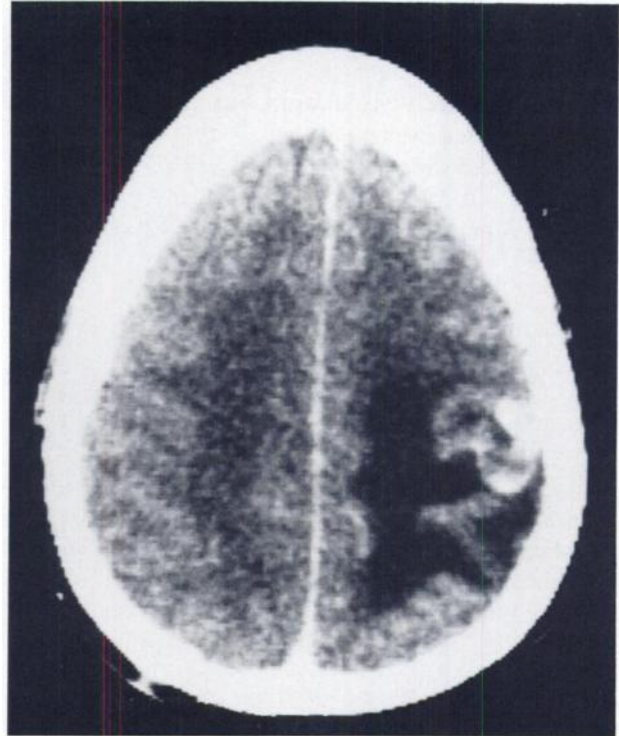


FIGURE 3
Transmission CT scan with contrast post-therapy. Enhancing lesion in left temporal parietal area with large amount of surrounding edema and mass effect

was noted in the right parietal region. A single, well-circumscribed lytic lesion was present in the occipital bone.

During the remainder of her hospitalization, the patient remained on steroids and had only one more seizure. The slurring of her speech improved, although some remained. Her motor strength improved. At the time of discharge, she had apraxia with hyperflexia and positive Babinski reflex on the right side.

DISCUSSION

Thyroid carcinoma is relatively rare disease that affects ~1 in 27,000 people (7). In individuals who have undergone head and neck irradiation, however, the incidence can be as high as 5–7 per 100.

The majority of patients with thyroid carcinoma have papillary, follicular, or a mixed pattern, as in our patient (1). Papillary carcinoma has an ~10% mortality rate over several decades. Although over 90% of regional lymph nodes are involved microscopically with tumor at the time of presentation, only about 1% have distant metastases (1). Subsequently, 4–20% of patients will develop distant metastases. In follicular carcinoma, tumor spreads to regional lymph nodes in only 10% of patients. However, distant metastases occur more frequently than in papillary carcinoma with 3.3% having distant metastases at the time of presentation (1). Follicular carcinoma patients have a greater propensity to develop distant metastases during the course of their

disease and have a higher death rate than patients with papillary carcinoma.

The most common sites of distant metastases from well-differentiated thyroid carcinoma are the lungs and bone (1,2). Beierwaltes has shown that patients with lung metastases treated with ^{131}I had a 5-yr survival of 92% and a 10-yr survival of 87% (2). Patients with bone metastases, however, had only a 44% survival at 10 yr.

The brain is a relatively rare site for thyroid carcinoma metastases. In Mazzaferri's review of 571 patients with papillary carcinoma, only one patient developed brain metastases (1). A recent review of M.D. Anderson Hospital's experience in well-differentiated thyroid carcinoma showed that of 352 patients, only two developed brain metastases (3).

However, brain metastases are much more frequent in patients who die of thyroid carcinoma. Of the two patients reported from M.D. Anderson, both died as a result of their brain metastases (3). Tollefsen et al., reviewing the deaths of 16 patients from follicular carcinoma, found one died from brain metastases (4). In addition, of 70 patients dying from papillary carcinoma, brain metastases was the cause of death in 10% (5). In this study, the remainder died from local neck recurrence (40%), pulmonary metastases (31%), bone metastases (10%), local recurrence plus pulmonary metastases (7%) and hepatic metastases (1%).

Serious complications from ^{131}I therapy can be divided into early complications (up to 3 mo after treatment) and late complications. Of early complications, the most frequent is acute radiation sickness (6). This usually occurs within 12 hr of administration and has been reported in 36–73% cases. Another common problem is sialoadenitis. This usually occurs shortly after treatment and may last for several days. Brief, asymptomatic bone marrow suppression may occur within 1 mo of treatment; transient anemias have been reported in 36% of patients, leukopenia (10%), and thrombocytopenia (3%). Permanent or severe marrow suppression has been reported when the blood radiation dose was high, but has not been observed when the radiation dose to the blood was less than 200 rad. Finally, some patients report the development of pain in their metastases following treatment. This presumably is due to radiation-induced swelling and is analogous to radiation thyroiditis.

We were only able to find two prior reports of CNS complications of ^{131}I therapy; one life threatening, the other fatal. Holmquist and Lake reported a patient with papillary-follicular carcinoma of the thyroid with metastases to the lung, skeleton, and brain (8). This patient was treated with 135 mCi ^{131}I , and shortly following therapy, developed left-sided seizures, which continued intermittently for 1 hr, and left-sided weakness. A cerebral angiogram revealed a highly vascular 3–4 cm mass in the right parietal area. Six days following radiation

therapy, the patient continued to show depression of his sensorium and total paralysis of his left side. A craniotomy was performed and a bulging hemorrhagic tumor removed. Pathologic examination of the tissue revealed a well-differentiated tumor of the follicular cell type with considerable central necrosis. Assay of several samples of the less necrotic tissue in a dose calibrator showed an average uptake of 1.2 μCi of ^{131}I per g of tissue. The sudden hemorrhage into the tumor was felt to have been caused by the ^{131}I therapy.

Hurley and Becker in a review of thyroid carcinoma, mentioned they had observed one case of severe, fatal cerebral edema after ^{131}I treatment of a patient with functioning cerebral metastases (6). No further details of the case were given.

In our case, as in the two cases above, the patient's tumor was under TSH stimulation which can stimulate tumor growth (9). However, the timing of the patients' seizures makes radiation-induced cerebral edema the most likely cause.

External beam radiation for cerebral metastases from a variety of tumors is commonly performed (10–12). In a review of complications secondary to external beam radiation, most were seen within 24 hr of the initiation of therapy (13). In patients who died of radiation-caused complications, pathologic evidence of cerebral edema and transtentorial herniation was found in all cases autopsied.

Corticosteroids are widely used to reduce the incidence of radiation-induced cerebral edema in patients receiving external beam therapy (13–18). Steroids have been shown to decrease both the amount of radiation-induced cerebral edema and the CNS complication rate of external beam therapy. The particular steroid used is not important (15). Many therapists begin the steroids 48–72 hr prior to the initiation of the radiation therapy (15).

How steroids reduce cerebral edema associated with brain metastases is not clear (19). It appears steroids may stabilize the capillary endothelial membrane preventing serum proteins and other materials from crossing it, or they may stabilize cellular lysosomal membranes against the release of enzymatic toxins which produce deleterious effect on adjacent brain tissue.

Adrenocorticosteroids have been suggested as a cause of decreased iodine uptake in thyroid glands (20). For that reason, glycerol, which has been used as an alternative to dexamethasone in patients receiving brain irradiation or mannitol, might be a better choice for ^{131}I therapy of thyroid carcinoma (18).

REFERENCES

1. Mazzaferri EL: Papillary and follicular thyroid cancer: A selective approach to diagnosis and treatment. *Ann Rev Med* 32:73–91, 1981
2. Varma VM, Beierwaltes WH, Nofal MM, et al: Treatment of thyroid cancer: Death rates after surgery and

- after surgery followed by sodium iodide I-131. *JAMA* 214:1437-1442, 1970
3. Maheshwari YK, Hill CS, Haynie TP III, et al: ¹³¹I therapy in differentiated thyroid carcinoma: MD Anderson hospital experience. *Cancer* 47:664-671, 1981
 4. Tollefsen HR, Shah JP, Huvos AG: Follicular carcinoma of the thyroid. *Am J Surg* 126:523-528, 1973
 5. Tollefsen HR, DeCosse JJ, Hutter RVP: Papillary carcinoma of the thyroid. *Cancer* 17:1035-1044, 1964
 6. Hurley JR and Becker DV: The use of radioiodine in the management of thyroid cancer. In *Nuclear Medicine Annual 1983*, Freeman LM, Weissmann HS, eds. New York, Raven Press, 1983, pp 329-382
 7. Theros EG, Siegel BA, Alazraki NP, et al., eds: *Nuclear Radiology (Second Series) Syllabus*, Chicago, American College of Radiology, 1978, pp 560-564
 8. Holmquist DL, Lake P: Sudden hemorrhage in metastatic thyroid carcinoma of the brain during treatment with iodine-131. *J Nucl Med* 17:307-309, 1976
 9. Crile G, Jr: The endocrine dependency of certain thyroid cancers and the danger that hypothyroidism may stimulate their growth. *Cancer* 10:1119-1137, 1957
 10. Chao JH, Phillips R, Nickson JJ: Roentgen-ray therapy of cerebral metastases. *Cancer* 7:682-689, 1954
 11. Chu FCH, Hilaris BB: Value of radiation therapy in the management of intracranial metastases. *Cancer* 14:577-581, 1961
 12. Deutsch M, Parsons JA, Mercado R, Jr: Radiotherapy for intracranial metastases. *Cancer* 34:1607-1611, 1974
 13. Young DF, Posner JB, Chu F, et al: Rapid-course radiation therapy of cerebral metastases: Results and complications. *Cancer* 34:1069-1076, 1974
 14. Nisce LZ, Hilaris BS, Chu FCH: A review of experience with irradiation of brain metastasis. *Am J Roentgenol Radium Ther Nucl Med* 111:329-333, 1971
 15. Posner JB: Management of central nervous system metastases. *Semin Oncol* 4:81-91, 1977
 16. Cairncross JG, Kim JH, Posner JB: Radiation therapy for brain metastases. *Ann Neurol* 7:529-541, 1980
 17. Lokich JJ: The management of cerebral metastasis. *JAMA* 234:748-751, 1975
 18. Bedikian AY, Valdivieso M, Heilbrun LK, et al: Glycerol: A successful alternative to dexamethasone for patients receiving brain irradiation for metastatic disease. *Cancer Treat Rep* 62:1081-1083, 1978
 19. Weinstein JD, Toy FJ, Jaffe ME, et al: The effect of dexamethasone on brain edema in patients with metastatic brain tumors. *Neurology* 23:121-129, 1972
 20. Datz FL: *Gamuts in Nuclear Medicine*, Norwalk, CT, Appleton-Century Crofts, 1983, pp 16-17