
Scintigraphic Assessment of Neorectal Motor Function

P. Ronan O'Connell, Keith A. Kelly, and Manuel L. Brown

Department of Surgery, Gastroenterology Unit, and Section of Diagnostic Nuclear Medicine, Mayo Clinic and Foundation, Rochester, Minnesota

Colectomy, mucosal resection, and ileal pouch-anal anastomosis have become alternatives to proctocolectomy and ileostomy for patients with ulcerative colitis or polyposis coli. The aim of this study was to develop a scintigraphic technique for assessment of the "neorectal" motor function of such patients. An artificial stool, consisting of a 7.5% dispersion of aluminum magnesium silicate in water, was labeled with 1 mCi [^{99m}Tc]sulfur colloid and instilled into the neorectum. Static pre- and postevacuation scans and dynamic acquisition scans during evacuation were taken with the patient seated on a commode. The imaging provided good anatomic definition of the pouch and quantitated the usual rate and percentage of neorectal evacuation at about 10 ml stool/sec and 60% of instilled stool, respectively. This technique appeared to be a safe, simple, useful tool for assessing the neorectal motor function of patients with ileal pouch-anal anastomosis.

J Nucl Med 27:460-464, 1986

Colectomy, mucosal resection, and endorectal ileoanal anastomosis offer an attractive surgical alternative to permanent ileostomy for patients requiring excision of the large intestine for ulcerative colitis or familial polyposis. Although proposed as early as 1947 (1), only in the past 8 years has there been widespread acceptance of the technique following publication of a series of 17 patients by Martin (2). The operation removes diseased mucosa, yet preserves the anal sphincters and the transanal route of defecation. All patients experience at least temporary difficulties with increased stool frequency, episodic incontinence, and perineal irritation in the postoperative period due, in part, to the loss of a compliant rectum, but most patients eventually have an acceptable clinical result (3).

Clinical results have been improved by either using postoperative balloon dilatation to increase the capacity of the "neorectum" when the ileum itself is used for the ileoanal anastomosis (4) or, preferably, by adding an ileal pouch proximal to the ileoanal anastomosis to provide a more capacious neorectum than occurs with a straight ileoanal anastomosis (5-8). The ileal pouch usually results in a satisfactory stool frequency of ~6

motions/day and almost perfect continence, but stasis within the pouch due to inefficient evacuation may cause the passage of frequent small stools and incontinence (9).

We developed a new scintigraphic test to better evaluate function in patients who have had the ileal pouch-anal operation and, especially, to estimate the efficiency and rate of neorectal evacuation.

MATERIALS AND METHODS

In Vitro Studies

An artificial stool must be safe, simulate the consistency of ileostomy stool, and easily bind a technetium-99m (^{99m}Tc) compound in order to be useful as a neorectal scanning medium. Aluminum magnesium silicate[†] is an inert powder which swells in water to form a colloidal dispersion used as a suspending and thickening agent in pharmaceutical preparations (10). A dispersion of the silicate in water at 37°C forms a thick paste similar in consistency to ileostomy stool.

An in vitro study of isotope binding to the silicate was performed using [^{99m}Tc]pertechnetate, [^{99m}Tc]albumin, and [^{99m}Tc]sulfur colloid. Ten milliliters of water, 10 μCi ^{99m}Tc, and sufficient aluminum magnesium silicate powder were added to each of nine test tubes so that 5, 7.5, and 10% dispersions of the silicate resulted in three sets of three tubes, respectively. The tubes were centrifuged and the supernatant collected.

Received July 17, 1985; revision accepted Nov. 26, 1985.

For reprints contact: Manuel L. Brown, MD, Dept. of Nuclear Medicine, Mayo Clinic, Rochester, MN 55905.

* A portion of this work was presented at the 32nd Annual Meeting of The Society of Nuclear Medicine, Houston, Texas, June 3, 1985.

An additional 10 ml of water was then added to each test tube, and the contents thoroughly mixed. The tubes were centrifuged again and the supernatant collected. The supernatants and residue were counted in a well counter[†] with an energy window setting 0–200 keV. The percentage binding of isotope to the aluminum magnesium silicate was determined in each case. Technetium-99m sulfur colloid was found to have greater binding affinity for the silicate gel than either [^{99m}Tc]pertechnetate or [^{99m}Tc]albumin (Table 1). The consistency of the 7.5% dispersion of aluminum magnesium silicate was closest to the semisolid consistency of ileoanal stool. Thus, this concentration of gel labeled with [^{99m}Tc]sulfur colloid was selected for use in the subsequent *in vivo* studies.

In Vivo Studies

The clinical protocol was approved by the Mayo Institutional Review Board in October, 1984. Twenty-three patients and seven healthy controls were studied. The patients were 24 ± 2 mo (mean ± s.e.m.) following operation for ulcerative colitis, and their ages ranged from 23 to 56 yr (mean ± s.e.m., 38 ± 2 yr). Four patients had an “S” ileal pouch-anal anastomosis (5) and 19 a “J” ileal pouch-anal anastomosis (11). Among the seven controls were two men and five women; their ages ranged from 24 to 68 yr (mean, 37 ± 6 yr). There were ten females of child-bearing age in the study, all of whom had a negative pregnancy test on the day prior to study.

The scanning medium used was a 7.5% colloidal dispersion of aluminum magnesium silicate labeled with 1 mCi ^{99m}Tc. The volume of aluminum magnesium silicate used in each subject was determined by prior balloon manometry that measured the maximum capacity of either the rectum or neorectum (11). This closely simulates the usual state of filling of the distal bowel at the time of defecation.

The scanning medium was prepared by adding 1 mCi [^{99m}Tc]sulfur colloid to 370 ml water at 37°C. Thirty grams of aluminum magnesium silicate powder were then slowly added while constantly stirring to produce a smooth thick paste. The gel was left stirring at 37°C for 15 min prior to use. A 1-ml sample was then taken and weighed, and ^{99m}Tc activity counted in a well

counter. The ^{99m}Tc activity/g of labeled aluminum magnesium silicate was calculated. The labeled aluminum magnesium silicate and its container were then weighed before insertion of aluminum magnesium silicate into the subject for scanning.

The patients were given no special bowel preparation apart from the opportunity to evacuate the neorectum immediately before the test. Controls were given a phosphate enema 3 hr prior to the study to empty the rectum and to facilitate rectal manometry which was performed 2 hr before the scan. For introduction of the labeled aluminum magnesium silicate into the distal bowel, the subjects lay on the left side with hips fully flexed. A 16-French tube, 12 cm long, was inserted 10 cm per anum, and the labeled aluminum magnesium silicate introduced, using a 150-ml syringe. The volume introduced was equivalent to the maximum tolerable neorectal capacity. The residual aluminum magnesium silicate and its container were then weighed and the weight of the aluminum magnesium silicate inserted calculated. Knowing the activity per gram of the instilled aluminum magnesium silicate allowed the total activity inserted to be calculated in each case.

A 5-min pre-evacuation anterior scan of the neorectum was obtained with the subjects standing in front of a gamma camera[‡] having a low energy, all purpose collimator and linked to a computer.[§] Next, the subject was seated on a radiolucent commode with a pre-weighed plastic bag lining the collection pan. A pre-evacuation right lateral scan was obtained over five min. The computer was then set for dynamic acquisition of 2-sec images over 4 min. Each subject was asked to defecate at will, but without moving. When this was completed, the subject was given the opportunity to move about and, if possible, evacuate residual labeled aluminum magnesium silicate. Finally, the lateral and anterior scans were repeated, each over 5 min.

The plastic liner containing the excreted aluminum magnesium silicate was removed from the commode and weighed. A 1-ml sample of the excreted material was taken, weighed, and then counted in a well counter to calculate ^{99m}Tc activity. The ^{99m}Tc activity/g material excreted and the total ^{99m}Tc activity excreted were calculated. The total activity excreted was divided by the total activity administered, and the percent of the instilled aluminum magnesium silicate that was evacuated was determined. The ^{99m}Tc activity of aluminum magnesium silicate evacuated was compared with the activity of the aluminum magnesium silicate prior to instillation, following correction for decay to determine if fecal material within the rectum or neorectum had diluted the aluminum magnesium silicate.

Data Analysis

The scanning data were analyzed by comparing total pre- and post-evacuation counts for anterior and lateral

TABLE 1
Binding of ^{99m}Tc Isotopes to Aluminum Magnesium Silicate

Aluminum magnesium silicate		% ^{99m} Tc isotope binding		
% Dispersion	Consistency	Pertechnetate	Albumin	Sulfur colloid
5.0	Liquid	65.0	96.8	99.8
7.5	Semisolid gel	65.0	96.2	99.8
10.0	Solid gel	65.0	95.0	99.8

scans following correction for decay. The percentages of evacuation obtained from the scanning data were compared with the percentage weight and activity of aluminum magnesium silicate evacuated. On the lateral pre-evacuation and post-evacuation scans, radioactivity clearly outlined the ileal pouch or rectum. Some activity passed into the distal ileum proximal to the ileal pouch in patients or into the sigmoid colon in volunteers. These areas were recognized on the scan by narrowing and angulation of the reservoir. Using a joystick and regions of interest program on the computer, activity in the distal ileum could be separated from the ileal pouch in patients and the sigmoid colon from the rectum in controls. The pre-evacuation areas of interest thus defined were applied to the dynamic emptying data and separate emptying curves for the areas of interest were obtained. The time taken for evacuation of the ileal pouch or rectum was determined visually from the emptying curves. The rate of evacuation was derived by dividing the total volume of aluminum magnesium silicate evacuated determined by scintigraphy by the time taken for evacuation.

Statistical evaluation was performed using Student's t-test for paired and unpaired data and linear regression analysis as appropriate.

RESULTS

The volume of labeled aluminum magnesium silicate instilled in each subject, equivalent to the maximum

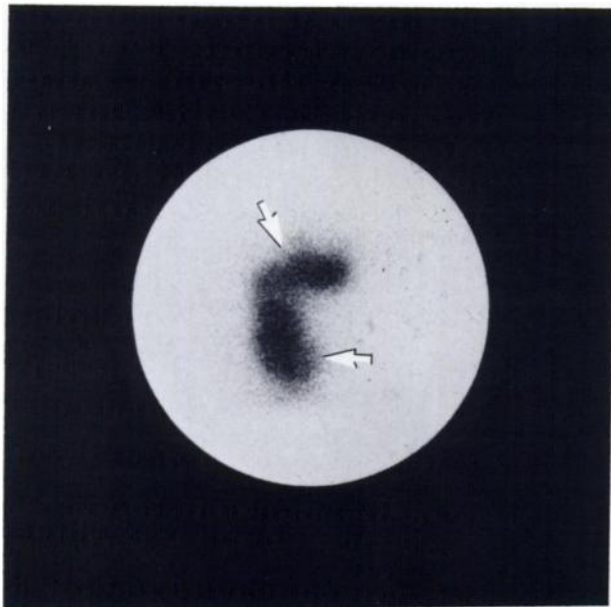


FIGURE 1
Lateral neorectal scintigraphic scan of patient with "J" pouch ileoanal anastomosis showing pouch (lower arrow) and distal ileum (upper arrow)

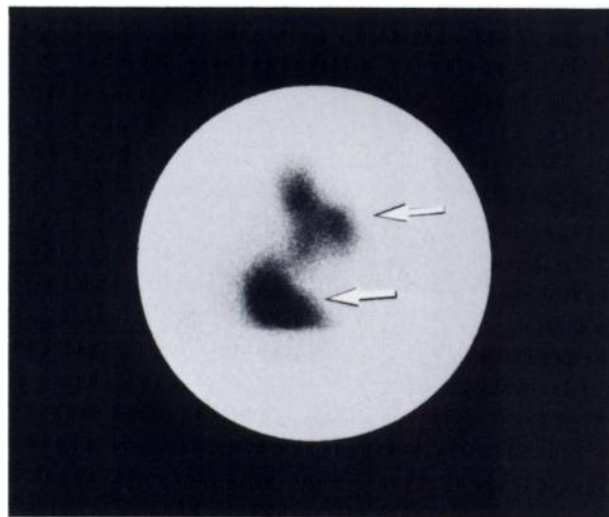


FIGURE 2
Lateral rectal scintigraphic scan of healthy volunteer, showing rectum (lower arrow) and sigmoid colon (upper arrow)

tolerable neorectal or rectal capacity, was a mean \pm s.e.m. of 320 ± 36 ml in patients and 330 ± 29 ml in unoperated volunteers ($p > 0.05$). All patients and controls were able to retain the labeled aluminum magnesium silicate until asked to evacuate, and none complained of discomfort. The pre-evacuation lateral scans demonstrated that the labeled aluminum magnesium silicate was distributed in both the ileal pouch and the distal ileum in patients ($54 \pm 6\%$ pouch, $46 \pm 6\%$ ileum, Fig. 1) and the rectum and sigmoid colon of volunteers ($71 \pm 5\%$ rectum, $29 \pm 5\%$ colon, Fig. 2).

All subjects could evacuate on request. The emptying results obtained from analysis of the anterior and lateral scans correlated closely. Little difference was found between the mean amount evacuated when measured by anterior and lateral scan (Table 2). Because the lateral scan provided a clearer anatomic outline of the neorectal pouch and distal ileum without overlapping, it was used to estimate evacuation in all subjects.

TABLE 2
Validation of Scintigraphic Estimation of Neorectal Emptying by Comparison with Stool Weight and ^{99m}Tc Activity Evacuated

% Evacuation	r	p
Lateral scan compared with AP scan	0.86	<0.001
Weight aluminum magnesium silicate compared with lateral scan*	0.92	<0.001
Weight aluminum magnesium silicate compared with ^{99m}Tc activity	0.90	<0.001

* Scan overestimates weight evacuated by $9.6 \pm 2.6\%$.

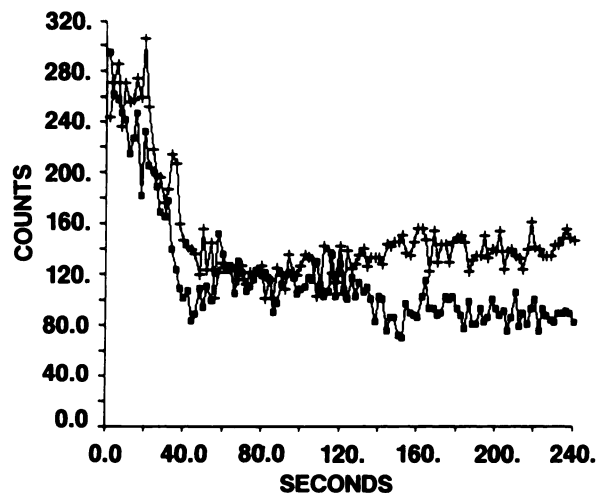


FIGURE 3
Neorectal emptying curves of ileal "J" pouch showing prompt evacuation of ileal pouch (+--++) and distal ileum (■-■-■)

The ^{99m}Tc activity/g of aluminum magnesium silicate before insertion and after recovery was similar (before: $7.3 \pm 0.8 \times 10^5$ cpm/g; after: $7.0 \pm 0.8 \times 10^5$ cpm/g; $p > 0.05$). This indicated that contamination by nonradioactive material did not occur and allowed a valid comparison to be made between the efficiency of evacuation determined by scintigraphy and that calculated from the weight of instilled aluminum magnesium silicate recovered. A close correlation was present between these two methods of estimating emptying; however, scanning slightly overestimated the weight emptied by $9.6 \pm 2.6\%$ (Table 2). Had contamination of instilled aluminum magnesium silicate by nonradioactive intestinal contents occurred, scintigraphic determination of emptying deficiency would have been expected to underestimate rather than overestimate emptying efficiency determined by the weight of aluminum magnesium silicate evacuated. The difference was assumed to be because of movement of isotope in the distal ileum towards the pouch and away from the gamma camera during evacuation, with resulting increased attenuation of radioactivity. We did not perform left-sided emptying studies to test this hypothesis. The weight of labeled aluminum magnesium silicate emptied correlated closely with the emptying estimated by calculating the recovery of total activity of ^{99m}Tc instilled into the pouch (Table 2).

The onset of evacuation by patients occurred promptly on command. Defecation lasted <90 sec in 20 of the 23 patients (median 20 sec). In these patients, $61 \pm 3\%$ of the instilled labeled aluminum magnesium silicate was emptied at a rate of 11.3 ± 1.8 ml labeled aluminum magnesium silicate/sec (Fig. 3). The remaining three patients took >90 sec to empty. In these patients, emptying was less efficient ($37 \pm 5\%$ of labeled aluminum magnesium silicate emptied), and the rate

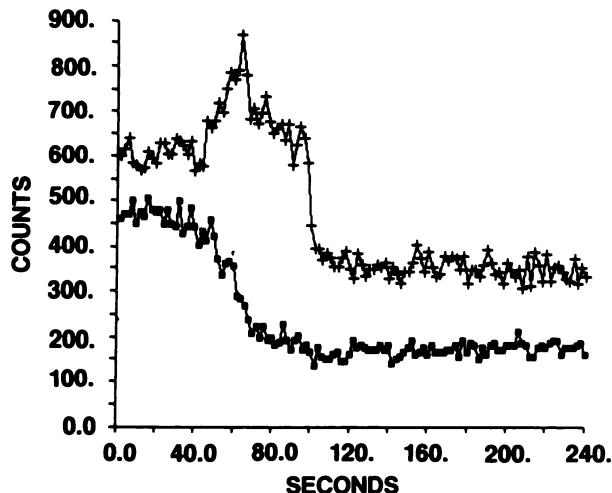


FIGURE 4
Sigmoid colon and rectal emptying curves showing initial movement of activity from sigmoid colon (■-■-■) into rectum, before prompt evacuation of rectum (+--+)

of emptying slower (1.0 ± 0.1 ml labeled aluminum magnesium silicate/sec) than it was in the other 20 patients ($p < 0.01$). In these three patients, inefficient neorectal emptying was associated with frequent passage of small stools and impaired continence.

The efficiency of evacuation in the seven healthy controls was similar to the ileal pouch patients (controls, $60 \pm 6\%$; ileal pouch patients, $57 \pm 3\%$; $p > 0.05$); however, the pattern of evacuation differed. In the control group, labeled aluminum magnesium silicate first moved from the sigmoid colon into the rectum, which distended and then evacuated (Fig. 4), whereas in the patients the distal ileum and pouch emptied as a common chamber. The median evacuation time for controls was 40 sec compared with 20 sec for ileal pouch patients.

The maximum total dose of radiation that could have been experienced by a subject undergoing neorectal scintigraphy was determined as the radiation expo-

TABLE 3
Neorectal Scintigraphy-Dosimetry

Organ	Minimum* mrem	Maximum† mrem
Rectal or neorectal	32.5	780
Ovaries	4.5	108
Small intestine	2.3	56
Bladder	1.7	41
Bone marrow	1.3	31
Testes	0.5	11
Total body	0.5	14

* Minimum exposure, based on 1 mCi ^{99m}Tc residing in neorectum for 15 min.

† Maximum exposure, based on 1 mCi ^{99m}Tc residing in neorectum for 6 hr.

sure resulting from 1 mCi ^{99m}Tc residing in the neorectum (or rectum) for 6 hr. The maximum total body radiation dose resulting from this exposure would be 14 mrem (Table 3). However, as all the subjects evacuated within 15 min of isotope insertion, the actual dose received was considerably less, and in most subjects was close to the estimated minimum radiation exposure (Table 3).

To estimate possible absorption of ^{99m}Tc from the neorectum, six patients had a 24-hr urine collection following the scan. An aliquot of the collection was counted for ^{99m}Tc activity and the total activity excreted over 24 hr determined. The prescanning sample of labeled aluminum magnesium silicate was recounted and the total activity of ^{99m}Tc instilled was recalculated. From these data, the percentage absorption and urinary excretion of ^{99m}Tc were determined. Only $0.6 \pm 0.2\%$ of the ^{99m}Tc inserted into neorectum was excreted in the urine.

DISCUSSION

Conventional radiographic techniques provide clear definition of rectal anatomy and can be used to determine anorectal angulation and perineal descent (12). Several innovative variations of dynamic barium proctography have been reported, including the use of various contrast media that closely simulate normal stool consistency (13–15). Barium studies of the neorectum following ileal pouch-anal anastomosis have shown that the length of the pouch efferent limb (16) and the acuteness of pouch angulation (17) are important anatomic features of the “S” ileal pouch that determine efficiency of pouch evacuation. There are, however, two important disadvantages of barium “pouchography”; it is associated with substantial pelvic radiation, and it does not quantify emptying.

The scintigraphic technique described provides sufficient anatomic detail to identify the neorectal pouch, the prepouch distal ileum, and the efferent limb of an “S” pouch when one is present. Moreover, it quantifies the rate and efficiency of neorectal emptying with minimal radiation exposure. Irrigation of the ileal pouch or use of an enema following the scan could have reduced the total radiation exposure even further.

Neorectal scintigraphy appears to be a useful addition to the investigative procedures available for assessing neorectal motor function following ileal pouch-anal anastomosis. The technique may also prove useful for assessing rectal motor function among patients after other colorectal operations.

FOOTNOTES

- [†] Veegum-Ruger Chemical Co., Irvington, NJ.
- [‡] Beckman 310 System, Beckman Inc., Irvine, CA.
- [§] GE-500A, General Electric, Inc., Milwaukee, WI.
- [¶] A², Medical Data Systems, Inc., Ann Arbor, MI.

ACKNOWLEDGMENTS

This work was supported in part by USPHS Grants TWO 3501, AM18278 and AM34988, the Dublin University Travelling Scholarship in Surgery, and the Mayo Foundation.

REFERENCES

1. Ravitch MM, Sabiston DC Jr: Anal ileostomy with preservation of the sphincter. *Surg Gynecol Obstet* 84:1095–1099, 1947
2. Martin LW, LeCoultrre C, Schubert WK: Total colectomy and mucosal proctectomy with preservation of continence in ulcerative colitis. *Ann Surg* 186:477–480, 1977
3. Heppell J, Pemberton JH, Kelly KA, et al: Ileal motility after endorectal ileo-anal anastomosis. *Surg Gastroenterol* 1:123–127, 1982
4. Telander RL, Perrault J: Colectomy with rectal mucosectomy and ileoanal anastomosis in young patients: Its use for ulcerative colitis and familial polyposis. *Arch Surg* 116:623–629, 1981
5. Parks AG, Nicholls RJ, Belliveau P: Proctocolectomy with ileal reservoir and anal anastomosis. *Br J Surg* 67:533–538, 1980
6. Utsunomiya J, Iwama T, Imajo M, et al: Total colectomy, mucosal proctectomy and ileoanal anastomosis. *Dis Colon Rect* 23:459–466, 1980
7. Peck DA: Rectal mucosal replacement. *Ann Surg* 191:294–303, 1980
8. Fonkalsrud EW: Endorectal ileal pullthrough with lateral ileal reservoir for benign colorectal disease. *Ann Surg* 194:761–766, 1981
9. Nicholls RJ, Pescatori M, Motson RW, et al: Restorative proctocolectomy with a 3 loop ileal reservoir for ulcerative colitis and familial adenomatous polyposis. *Ann Surg* 199:383–388, 1984
10. Martindale W: *The Extra Pharmacopoeia*, 28th edition, Reynolds JEF, ed. London, The Pharmaceutical Press, 1982, p 949
11. Taylor BM, Cranley B, Kelly KA, et al: A clinicophysiological comparison of ileal pouch-anal and straight ileoanal anastomosis. *Ann Surg* 198:462–468, 1983
12. Preston DM, Lennard-Jones JE, Thomas BM: The balloon proctogram. *Br J Surg* 71:29–32, 1984
13. Kerremans R: Cine radiography of the ano-rectal system. In *Morphological and Physiological Aspects of Anal Continence and Defaecation*, Brussels, Editions Arscia SA, 1969, pp 91–120
14. Bunt TJ, Pakiam I, Dragstedt LR: The psyllium colloid contrast enema: A method for evaluating anal sphincteric continence. *Am J Proctol Gastroenterol Colon Rectal Surg* 33:30–32, 1982
15. Phillips SF, Edwards AW: Some aspects of anal continence and defecation. *Gut* 6:396–406, 1965
16. Pescatori M, Manhire A, Bartram CI: Evacuation pouchography in the evaluation of ileoanal reservoir function. *Dis Colon Rect* 26:365–368, 1983
17. Lindquist K, Liljeqvist L, Sellberg B: The topography of ileoanal reservoirs in relation to evacuation patterns and clinical functions. *Acta Chir Scand* 150:573–579, 1984