
Iodine-131 Metaiodobenzylguanidine Scintigraphy of Carcinoid Tumors

Jerome M. Feldman, Russell A. Blinder, Kathryn J. Lucas, and R. Edward Coleman

Departments of Medicine and Radiology, Duke University Medical Center; and The Durham VA Medical Center, Durham, North Carolina

Iodine-131 metaiodobenzylguanidine (^{131}I MIBG) is concentrated in pheochromocytomas and can be detected by external imaging. We administered ^{131}I MIBG to 23 patients with carcinoid tumors to determine if it would be useful in scanning patients with these tumors. The carcinoid tumors of 14 of the 23 patients (61%) were visualized. Iodine-131 MIBG was concentrated most avidly by tumors of midgut origin (ileum, cecum); it was concentrated less avidly by some tumors of foregut origin (pancreas, stomach); it was not significantly concentrated by other tumors of foregut origin (bronchus). We conclude that ^{131}I is a useful imaging agent for carcinoid tumors.

J Nucl Med 27:1691-1696, 1986

The guanethidine analog iodine-131 metaiodobenzylguanidine (^{131}I MIBG) is adequately concentrated in pheochromocytomas and adrenal medullary hyperplasia for scintigraphic images of the abnormal localization to be made (1,2). We recently demonstrated that ^{131}I MIBG is also concentrated in normal platelets by a neuronal-pump mechanism (3). This platelet uptake raised the possibility that ^{131}I MIBG might be useful for visualizing other tumors which have a neuronal pump mechanism, such as carcinoid tumors. While this study was in progress Fischer et al. reported that one patient with a carcinoid tumor whom they evaluated with ^{131}I MIBG had adequate tumor uptake for visualization of hepatic metastases (4). In this report we describe 25 studies with ^{131}I MIBG performed on 23 patients with carcinoid tumors of diverse anatomic origin.

PATIENTS AND METHODS

Subjects

Twenty-three patients (14 men and nine women) ranging in age from 33 to 80 yr (mean age 60 yr) were evaluated. All of the patients had biopsy proven carcinoid tumors with the origin of the primary tumor noted in Tables 1 and 2. The carcinoid tumors were of foregut origin (bronchus, pancreas, stomach) in nine patients

and midgut origin (ileum, cecum) in 14 patients (5). The patients collected a 24-hr urine sample in a plastic bottle that was kept at 1°C.

With the exception of Patients 13, 14, and 22, all of the patients had evidence of increased serotonin production as manifested by increased urinary excretion of serotonin, or its principal metabolite 5-hydroxyindoleacetic acid (5-HIAA). Patients 2, 16, 17, 19, 20, and 21 had disproportionately higher urinary serotonin than 5-HIAA excretion indicating that they had atypical carcinoid tumors that were secreting more 5-hydroxytryptophan than serotonin (6).

Patients with bouts of facial flushing or diarrhea were defined as having the carcinoid syndrome. The presence of tumor in liver, lymph nodes, bone, or primary tumor was established by appropriate tests or procedures, such as chest roentgenograms, chest or abdominal computed tomography (CT), liver-spleen radionuclide imaging, bone roentgenograms, bone radionuclide imaging, surgery, or postmortem examination.

METHODS

After receiving a detailed explanation of the proposed studies, the patients signed an institutional consent form. To block the uptake of free ^{131}I by the patient's thyroid, therapy with saturated solution of potassium iodide one drop three times a day was started on the day prior to administration of ^{131}I MIBG and continued for 1 wk. The patients then received 500 μCi (18.5 MBq) of ^{131}I MIBG intravenously. Scintiscans of the

Received Sept. 30, 1985; revision accepted Apr. 4, 1986.
For reprints contact: Jerome M. Feldman, MD, Box 2963,
Duke University Med. Ctr., Durham, NC 27710.

TABLE 1
Characteristics of Patients with Midgut Carcinoid Tumors

Patient no.	Origin of tumor	Carcinoid syndrome	5-HIAA (normal 2-8) mg/24 hr	Serotonin (normal 50-220) µg/24 hr	Tumor present/[¹³¹ I]MIBG uptake in tumor				Intensity of [¹³¹ I]MIBG uptake
					Liver	Lymph nodes	Bone	Primary tumor	
1	Ileum	Yes	48	100	Yes/Yes	Yes/No	No/No	No/No	3
2	Ileum	Yes	239	2,000	Yes/Yes	Yes/No	No/No	Yes/No	3
3	Ileum	Yes	162	233	Yes/Yes	No/No	No/No	No/No	3
4	Ileum	Yes	92	55	Yes/Yes	No/No	Yes/No	Yes/No	3
5	Ileum	Yes	180	98	Yes/Yes	Yes/No	No/No	Yes/No	3
6	Ileum	Yes	270	254	Yes/Yes	No/No	No/No	No/No	3
7	Ileum	No	13	174	Yes/Yes	No/No	No/No	No/No	3
8	Ileum	Yes	9	581	Yes/Yes	Yes/No	No/No	Yes/No	3
9	Ileum	Yes	32	369	No/No	Yes/Yes	No/No	No/No	3
10	Cecum	Yes	42	228	No/No	Yes/Yes	Yes/No	Yes/No	3
11	Ileum	Yes	44	342	Yes/No	Yes/Yes	No/No	No/No	3
12	Ileum	No	23	72	No/No	Yes/No	No/No	No/No	0
13	Ileum	No	2	80	Yes/No	No/No	No/No	No/No	0
14	Ileum	No	3	18	No/No	No/No	No/No	No/No	0

* At surgery patient had small carcinoid implants (<0.5 cm) in the peritoneum.

anterior and posterior chest, abdomen, and pelvis were performed 24 and 48 hr after receiving the [¹³¹I]MIBG. Each image was obtained for 100,000 counts or 20 min, whichever comes first. Thus, each image took from 10 to 20 min.

With the exception of the five patients with bronchial carcinoid tumors, technetium-99m sulfur colloid ([^{99m}Tc]SC) liver examinations with computer subtraction were performed at the time of the 48 hr [¹³¹I]MIBG scans. As [¹³¹I]MIBG is concentrated to some extent in normal liver, we found it helpful to subtract the [^{99m}Tc]SC images from the [¹³¹I]MIBG images to better define tumor deposits in the liver. The counts in a normal area of the [^{99m}Tc]SC study were normalized to the same counts per pixel in the normal area in the [¹³¹I]MIBG study.

Two nuclear medicine physicians, one of whom was

unaware of the patients' histories, graded [¹³¹I]MIBG uptake on a scale of 0 (no uptake) to three (intense uptake). Although all of the patients also had transmission computed tomography (CT) of the abdomen, in some cases the study was done 1 to 2 mo before or after the scintiscans.

Measurements of urinary excretion of 5-hydroxyindoleacetic acid (5-HIAA) and serotonin were performed using a spectrophotometric method and a radioenzymatic method, respectively (7).

RESULTS

In 10 of the 14 (71%) of patients with carcinoid tumors of midgut origin, adequate [¹³¹I]MIBG was concentrated by carcinoid tumor in liver or lymph glands

TABLE 2
Characteristics of Patients with Foregut Carcinoid Tumors

Patient no.	Origin of tumor	Carcinoid syndrome	5-HIAA (normal 2-8) mg/24 hr	Serotonin (normal 50-220) µg/24 hr	Tumor present/[¹³¹ I]MIBG uptake in tumor				Intensity of [¹³¹ I]MIBG uptake
					Liver	Lymph nodes	Bone	Primary tumor	
15	Pancreas	Yes	35	197	Yes/Yes	No/No	No/No	Yes/Yes	2
16	Pancreas	No	63	4,280	Yes/Yes	No/No	No/No	Yes/No	1
17	Stomach	Yes	81	7,155	Yes/Yes	Yes/No	No/No	Yes/No	1
18	Stomach	No	11	29	Yes/No	Yes/No	No/No	No/No	0
19	Bronchus	Yes	124	1,294	Yes/No	No/No	No/No	Yes/No	0
20	Bronchus	No	80	53,738	No/No	No/No	Yes/No	Yes/No	0
21	Bronchus	No	57	33,953	No/No	No/No	Yes/No	Yes/No	0
22	Bronchus	No	3	170	No/No	Yes/No	Yes/No	No/No	0
23	Bronchus	No	10	178	No/No	No/No	No/No	Yes/No	0

* Pulmonary metastases also present without [¹³¹I]MIBG uptake.

to satisfactorily visualize the carcinoid tumor in scintiscans (Table 1). In Patients 1 through 8 the abnormal [¹³¹I]MIBG uptake occurred in the liver; in Patients 9 through 11 it occurred in the lymph nodes. The hepatic metastases of Patients 1 through 8 were successfully imaged with both [¹³¹I]MIBG and [^{99m}Tc]SC (Fig. 1). Patients 11 and 13 had several hepatic metastases <2 cm in diameter seen at laparotomy. These small tumor deposits, however, were not visualized on the [¹³¹I]MIBG studies, [^{99m}Tc]SC liver-spleen scans, or abdominal CT.

We do not have direct verification that the extrahepatic concentration of [¹³¹I]MIBG seen was in lymph nodes. However, this is most likely, for carcinoid tumors invariably first metastasize to regional lymph nodes (5). These probable lymph node metastases were successfully imaged with [¹³¹I]MIBG in Patients 9 through 11. In Patient 10 the [¹³¹I]MIBG uptake was located in the cervical area. Although no nodes were palpable in the cervical area of Patient 10 at the time of the scan, 1½ yr prior to this study, biopsy demonstrated carcinoid tumor in cervical lymph nodes in this area of the patient's neck.

In Patients 9 and 11 the nodes successfully imaged were located in the abdomen. The celiac nodes of Patient 11 were noted on both the [¹³¹I]MIBG scan and the abdominal CT scan. Although the mesenteric nodes of Patient 9 noted on [¹³¹I]MIBG scan were initially not noted on abdominal CT, they were seen after attention was directed to this area by the positive [¹³¹I]MIBG scan (Fig. 2). The abdominal CT of Patient 2 suggested that enlarged lymph nodes were present in the mesentery and porta hepatis; however, these lymph nodes were not visualized on the [¹³¹I]MIBG study. In three other patients, who had lesser degrees of lymph node involvement detected at surgery, abnormal lymph nodes were not appreciated on [¹³¹I]MIBG or abdominal CT scan.

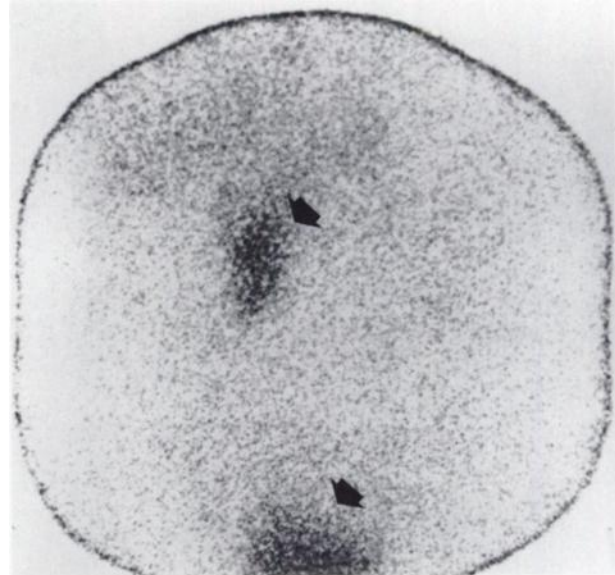


FIGURE 2
Anterior [¹³¹I]MIBG scintiscan performed 48 hr after Patient 9 received injection. Although patient has had diarrhea and flushing for 9 yr since his primary ileal carcinoid tumor was resected, there is no abnormal [¹³¹I]MIBG concentrated in his liver. Upper arrow shows [¹³¹I]MIBG is concentrated in tumor-bearing mesenteric lymph nodes; lower arrow shows [¹³¹I]MIBG excreted in bladder.

Patient 4 had a small area of probable metastatic carcinoid tumor in one thoracic vertebra noted on magnetic resonance imaging and Patient 10 had microscopic foci of carcinoid on an iliac crest bone marrow aspiration. Neither patient showed [¹³¹I]MIBG uptake in bone. None of the five patients with primary tumors present in the ileum or cecum showed [¹³¹I]MIBG uptake in the primary tumor.

The tumor was successfully imaged in only three of nine (33%) patients with foregut carcinoid tumors (Ta-

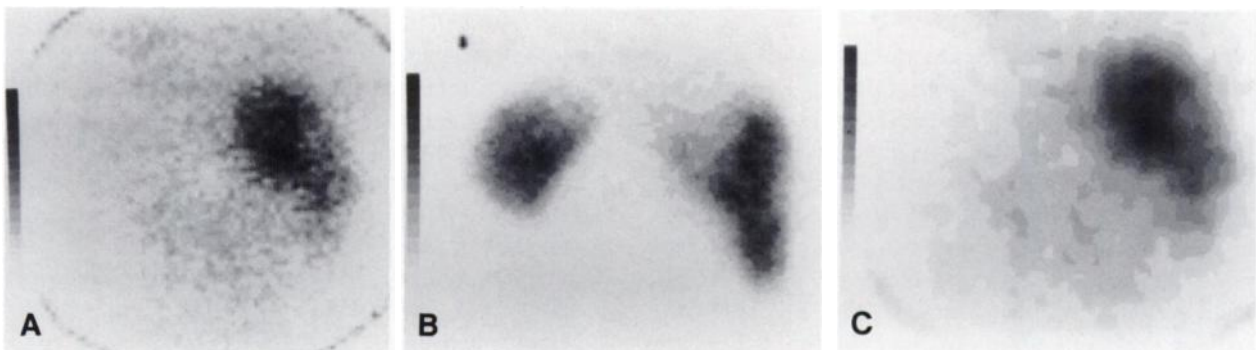


FIGURE 1
A: Computer acquired posterior [¹³¹I]MIBG image performed 24 hr after administration of agent to Patient 1. Iodine-131 MIBG is concentrated in large metastatic tumor in liver. B: Computer acquired posterior [^{99m}Tc]SC scan performed 10 min after i.v. administration of agent to Patient 1. Decreased activity is noted in upper portion of liver containing large metastatic tumor. C: Computer acquired posterior image of Patient 1 obtained by subtracting normalized [^{99m}Tc]SC image from [¹³¹I]MIBG image. Iodine-131 MIBG is clearly localized to large metastatic tumor in liver

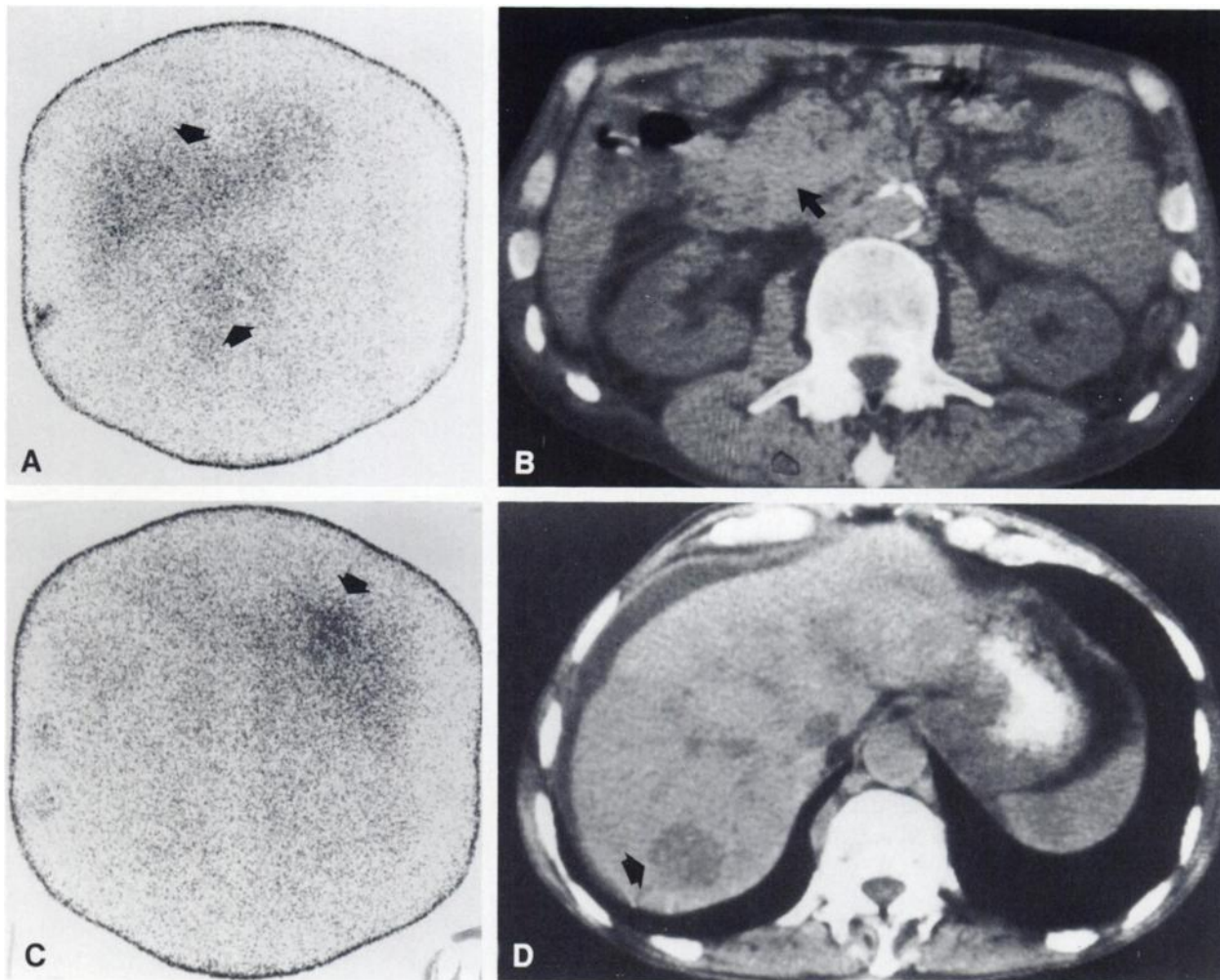


FIGURE 3

A: Anterior [^{131}I]MIBG scintiscan performed 48 hr after Patient 15 received isotope injection. Upper arrow shows normal [^{131}I]MIBG uptake in anterior region of liver; lower arrow shows abnormal ^{131}I uptake in primary carcinoid tumor located in head of pancreas. B: Abdominal CT scan performed on patient 15. Arrow shows carcinoid tumor located in head of pancreas. C: Posterior [^{131}I]MIBG scintiscan performed 48 hr after Patient 15 received isotope injection. Arrow shows abnormal [^{131}I]MIBG uptake in metastatic tumor in posterior region of liver. D: Abdominal CT performed on Patient 15. Arrow shows hypodense hepatic metastases that was imaged in Fig. 3C

ble 2). The primary pancreatic carcinoid tumor and the metastatic deposits in the liver of patient 15 were demonstrated by [^{131}I]MIBG and abdominal CT scans (Fig. 3). Only the metastatic deposits in the liver were imaged with [^{131}I]MIBG in Patients 16 and 17; at postmortem examination 1 mo after the [^{131}I]MIBG scan the primary gastric carcinoid tumor and the abdominal lymph nodes of Patient 17 were <1 cm in diameter. Despite the presence of primary bronchial carcinoid tumors as well as carcinoid tumor in liver, lymph nodes, and bone, positive uptake was not obtainable in any of the five patients with bronchial carcinoid tumors.

Three years prior to resection of his ileal carcinoid tumor, Patient 7 had an adenocarcinoma of the sigmoid colon resected; 4 yr after resection of his ileal carcinoid tumor this patient received radiation therapy for a

squamous cell carcinoma of the lung. When he developed hepatic metastases 2 yr after developing carcinoma of the lung, it was not clear which of the three primary tumors was responsible. The intense [^{131}I]MIBG uptake in the hepatic metastases suggested that carcinoid tumor was present in his liver. After percutaneous needle biopsy demonstrated that the hepatic metastases were from carcinoid tumor, a course of dacarbazine antineoplastic therapy was started.

Disagreement in the rating of [^{131}I]MIBG uptake by the two nuclear medicine physicians occurred in only one case and the blinded reader's rating was used. The final column in Table 1 shows that all of the carcinoids of midgut origin which gave positive scans were rated 3 (intense). The final column in Table 2 shows that the three carcinoids of foregut origin that had uptake were

rated as one or two. One gastric carcinoid tumor and all five bronchial carcinoid tumors were rated 0.

DISCUSSION

Iodine-131 MIBG is an agent that can be used to image a variety of endocrine tumors, such as pheochromocytoma (1,2) neuroblastoma (8,9) and medullary carcinoma of the thyroid (10,11). Studies with cultured bovine adrenal medullary cells demonstrate that [¹³¹I]MIBG and norepinephrine are taken into cells by both a sodium dependent and a sodium independent process (12). It is likely that the sodium dependent—or neuronal-pump uptake—is the more important process for concentrating [¹³¹I]MIBG in adrenergic cells for diagnosis and therapy because the uptake process in cultured bovine adrenal medullary cells (13) and human platelets (3), is inhibited by tricyclic antidepressants. In addition to pheochromocytomas, neuroblastomas, medullary carcinoma of the thyroid, and carcinoid tumors, a variety of other tumors are thought to arise from neural crest cells and thus may also have a neuronal pump mechanisms in their cell membrane. These tumors, which are referred to as APUDOMAS (amine precursor uptake and decarboxylation), produce a variety of polypeptide hormones, such as gastrin, insulin, glucagon, vasoactive intestinal peptide, or pancreatic polypeptide (14). It would certainly be worthwhile to determine if these other tumors might also concentrate [¹³¹I]MIBG in a similar manner to the APUDOMAS evaluated already.

We are not certain why [¹³¹I]MIBG was not taken up by the carcinoid tumors of some of the patients we evaluated. In many cases the tumor nodules were too small to be resolved by the imaging techniques. As normal tissue such as liver also concentrates [¹³¹I]MIBG, there are limitations of the target to background radioactivity with [¹³¹I]MIBG. Because each image already takes 10 to 20 min, it is difficult to further lengthen this imaging time. Iodine-123 has better radiation dosimetry per μCi administered than ¹³¹I. As there is also greater sensitivity of gamma cameras to ¹²³I than to ¹³¹I emissions, the images of pheochromocytomas obtained with [¹²³I]MIBG may detect some of the carcinoid tumors that we failed to detect with [¹³¹I]MIBG.

The present study indicates that the midgut carcinoid tumors (ileum, cecum) concentrate the [¹³¹I]MIBG more readily than foregut carcinoid tumors (pancreas, stomach, bronchus). A number of biologic differences between fore and midgut carcinoid tumors have been described previously. Foregut carcinoid tumors metastasize to bone, secrete 5-hydroxytryptophan rather than serotonin, and produce the ectopic ACTH syndrome much more frequently than midgut carcinoid tumors (5). One might speculate that bronchial carcinoid tumors are unable to concentrate [¹³¹I]MIBG because they

lack a neuronal pump mechanism; however, at the present time there is no data to confirm or reject this hypothesis.

It is interesting to compare our observations on the use of [¹³¹I]MIBG in patients with metastatic carcinoid tumors with the more extensive experience with this compound in patients with metastatic pheochromocytomas. Adequate [¹³¹I]MIBG for scintiscanning was concentrated in the tumor of 26 of 30 patients with malignant pheochromocytomas (16). However, because [¹³¹I]MIBG is excreted by the kidney, abdominal CT was more effective in localizing pheochromocytomas in the renal hilus than [¹³¹I]MIBG scans (16). The authors of this study point out that there is a complementary role for CT and [¹³¹I]MIBG scans in the diagnosis of malignant pheochromocytomas (17). Further experience may indicate that this may also be the case in the diagnosis of metastatic carcinoid tumors.

Occasional patients may develop the carcinoid syndrome from midgut tumors in the absence of hepatic metastases (18). Because the primary midgut carcinoid tumor is usually small, superior mesenteric arteriograms may be needed to localize the tumor prior to surgery (18). Since we were able to identify carcinoid tumor in lymph nodes with [¹³¹I]MIBG, it may also be possible to identify some primary carcinoid tumors with this compound. In this report, however, we successfully imaged the primary tumor only in Patient 15. This may be because the primary carcinoid tumors had been resected in many of our patients. In addition, one can speculate that the large amount of [¹³¹I]MIBG uptake in the extensive hepatic metastases of our patients may have obscured the uptake of this compound by their small primary tumor.

Larger doses of [¹³¹I]MIBG have been administered to five patients with metastatic pheochromocytomas to deliver therapeutic amounts of radiation to the tumor (19). Two of these patients had a worthwhile clinical response to this therapy. Although the percentage of pheochromocytomas that are malignant ranges from 1% to 13%, all midgut carcinoid tumors must be considered at least potentially malignant (20). In addition, carcinoid tumors occur substantially more frequently than pheochromocytomas. Thus, it will be worthwhile to determine if [¹³¹I]MIBG might deliver effective radiation therapy to metastatic carcinoid tumors.

ACKNOWLEDGMENTS

The authors thank W. H. Beierwaltes of University of Michigan for supplying the [¹³¹I]MIBG and Carolyn Newman for helping to prepare the manuscript.

This work was supported by the Veterans Administration, NIH Comprehensive Cancer Center Core Support Grant (5-P-30-CA 14236), NIH Training Cancer Grant (5T32-HL07503), NIH General Clinical Research Centers Program RR-30, and the Johnny M. Gossett Carcinoid Research Fund.

REFERENCES

1. Shapiro B, Copp JE, Sisson JC, et al: Iodine-131 metaiodobenzylguanidine for the locating of suspected pheochromocytoma: Experience in 400 cases. *J Nucl Med* 26:576-585, 1985
2. McEwan AJ, Shapiro B, Sisson JC, et al: Radioiodobenzylguanidine for the scintigraphic location and therapy of adrenergic tumors. *Semin Nucl Med* 15:132-153, 1985
3. Feldman JM, Frankel N, Coleman RE: Platelet uptake of the pheochromocytoma-scanning agent (¹³¹I)-metaiodobenzylguanidine. *Metabolism* 33:397-399, 1984
4. Fischer M, Kamanabroo D, Sonderkamp H, et al: Scintigraphic imaging of carcinoid tumors with ¹³¹I-metaiodobenzylguanidine. *Lancet* 2:165, 1984
5. Grahame-Smith DG: *The Carcinoid Syndrome*, London, William Heinemann Medical Books LTD, 1972
6. Feldman JM: Serotonin metabolism in patients with carcinoid tumors: Incidence of 5-hydroxytryptophan secreting tumors. *Gastroenterology* 75:1109-1114, 1978
7. Feldman JM: Increased dopamine production in patients with carcinoid tumors. *Metabolism* 34:255-260, 1985
8. Treuner J, Feine V, Niethammer D, et al: Scintigraphic imaging of neuroblastoma with (¹³¹I) m-iodobenzylguanidine. *Lancet* 1:333-334, 1984
9. Geatti O, Shapiro B, Sisson JC, et al: Iodine 131 metaiodobenzylguanidine scintigraphy for the location of neuroblastoma; preliminary experience in ten cases. *J Nucl Med* 26:736-742, 1985
10. Endo K, Shiomi K, Kasagi K: Imaging of medullary thyroid cancer with ¹³¹I-MIBG. *Lancet* 2:233, 1984
11. Connell JMC, Hilditch TE, Elliott A: ¹³¹I-MIBG and medullary carcinoma of the thyroid. *Lancet* 2:1273-1274, 1984
12. Jaques S Jr, Tobes MC, Sisson JC, et al: Comparison of the sodium dependency of uptake of meta-iodobenzylguanidine and norepinephrine into cultured bovine adrenomedullary cells. *Molec Pharm* 26:539-546, 1984
13. Tobes MC, Jaques S Jr., Wieland DM, et al: Effect of uptake—one inhibitors on the uptake of norepinephrine and metaiodobenzylguanidine. *J Nucl Med* 26:897-907, 1985
14. Welbourn RB, Manolas KJ, Khan O, Galland RB: Tumors of the neuroendocrine system (APUD cell tumors—apudomas). *Curr Prob Surg* 21:1-73, 1984
15. Lynn MD, Shapiro B, Sisson JC, et al: Portrayal of pheochromocytoma and normal human adrenal medulla by m-[¹²³I]iodobenzylguanidine: Concise communication. *J Nucl Med* 25:436-440, 1984
16. Shapiro B, Sisson JC, Lloyd R, et al: Malignant pheochromocytoma. *Clin Endocrinol (Oxf)* 20:189-203, 1984
17. Francis IR, Glazer GM, Shapiro B, et al: Complementary roles of CT and ¹³¹I-MIBG scintigraphy in pheochromocytoma. *Am J Roentgenol* 141:719-725, 1983
18. Feldman JM, Jones RS: Carcinoid syndrome from gastrointestinal carcinoids without liver metastasis. *Ann Surg* 196:33-37, 1982
19. Sisson J, Shapiro B, Beierwaltes WH, et al: Treatment of malignant pheochromocytoma with a new radiopharmaceutical. *Trans Assoc Am Phys* 96:209-217, 1983
20. Dow CJ, Palmer MK, O'Sullivan JP, et al: Malignant pheochromocytoma: Report of a case and a critical review. *Br J Surg* 69:338-340, 1982