

Localization of Technetium-99m DTPA in Neurofibroma

TO THE EDITOR: Technetium-99m diethylenetriamine-pentaacetic acid (^{99m}Tc]DTPA) is used for routine central nervous system and renal imaging. Normally, there is no significant uptake or retention of ^{99m}Tc]DTPA in any other organ of the body besides the urinary tract (1). It is not uncommon for ^{99m}Tc]DTPA to demonstrate lesions outside the central nervous system and urinary tract; however, this localization is transient and is related to the blood-pool activity. Prolonged retention or active localization is rare. The pathologic conditions where ^{99m}Tc]DTPA localization has been reported are uterine leiomyoma (2), soft-tissue sarcoma (3), splenic inflammation (4), inflammatory bowel disease (5), active Graves' ophthalmopathy and pretibial myxedema (6) and breast cancer (7). Recently there has been a report of ^{99m}Tc]DTPA localization in the soft-tissue lesions of neurofibromatosis (8). The following describes a child in whom

there was accumulation of ^{99m}Tc]DTPA in a neurofibroma.

The patient was an 8-yr-old girl with history of neurofibromatosis. She presented with a rapidly growing mass in the lumbosacral region. A smaller mass (neurofibroma) was resected from the same area 4 yr ago. Physical examination revealed multiple cafe-au-lait spots throughout the body. There was a large soft, nontender subcutaneous mass over the lower back extending into the left buttock. The skin over the mass was somewhat discolored. Computed tomography and magnetic resonance imaging showed extension of the mass into the sacral canal; however, the neurological examination was within normal limits. A ^{99m}Tc]DTPA scan was obtained because of urinary frequency. Early images showed progressively increasing accumulation of the radiotracer in the subcutaneous mass (Fig. 1). The 2-hr delayed images showed persistent retention of the radioactivity in the mass (Fig. 2). The renal function was normal. Total-body imaging did not show any other site of abnormal accumulation of ^{99m}Tc]DTPA. The mass was excised and histologically was

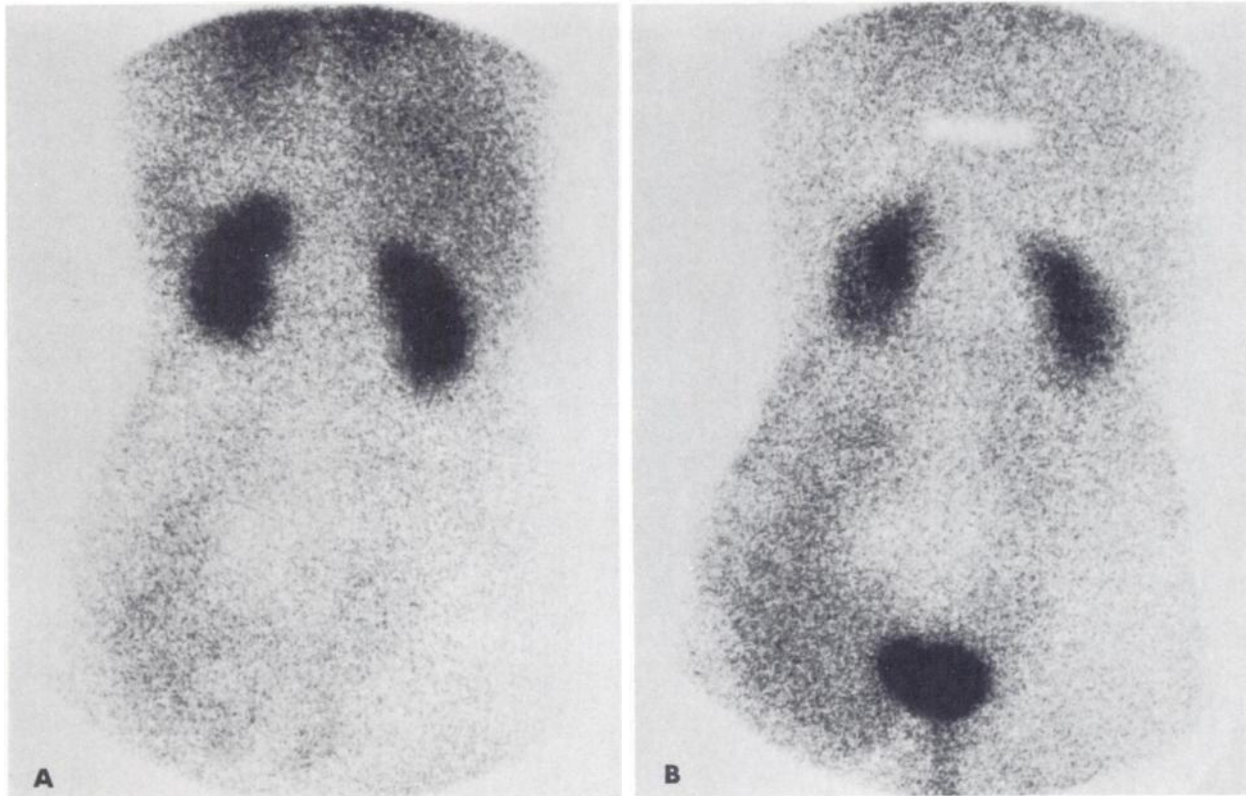


FIGURE 1
A and B are supine posterior images of abdomen obtained at 3 and 20 min after i.v. injection of ^{99m}Tc]DTPA. At 3 min uptake of radiotracer is seen in lower back mass as well as other blood pools (liver, spleen, heart, etc.). By 20 min (B) blood-pool activity has cleared but the uptake in mass has increased. Central "cold" area just above urinary bladder is produced by compression mass against spine in that region

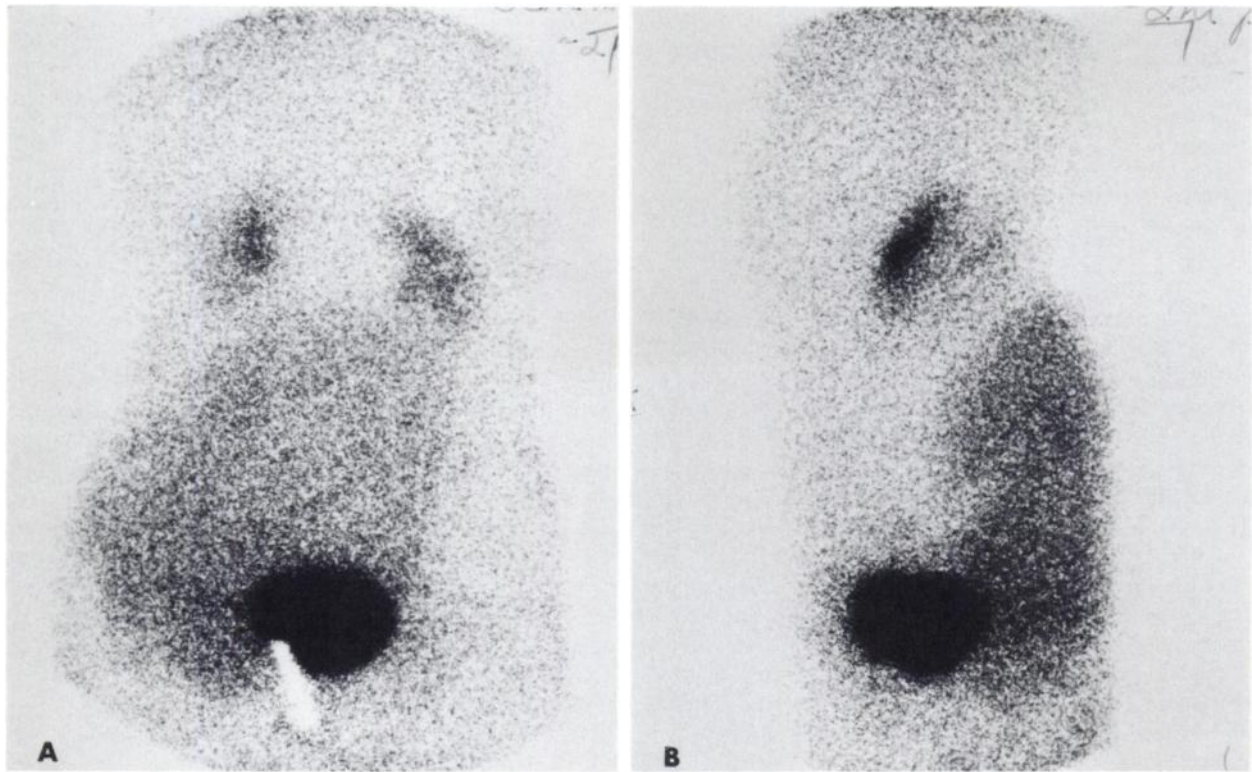


FIGURE 2

A and B, respectively, are posterior and left lateral images obtained 2 hr after injection. Abnormal accumulation of radioactivity has persisted and on lateral views is shown clearly to be superficial (in mass)

recurrent neurofibroma.

It is unusual for [^{99m}Tc]DTPA to have prolonged retention in lesions other than those seen in the central nervous system or in the urinary tracts. In our patient the only urinary tract abnormality that may be considered in the differential diagnosis is urine leak. The appearance of radiotracer in the mass even before the beginning of the excretion should rule out that possibility. Also, the left lateral image (Fig. 2B) clearly shows the collection of the radioactivity to be extremely posterior.

The mechanism of localization of [^{99m}Tc]DTPA in the neurofibroma is not clear. The initial appearance of the radioactivity is most likely due to the blood-pool phenomenon. The possible explanations for the retention of [^{99m}Tc]DTPA in the mass include poor venous drainage, extravasation within the mass due to altered capillary permeability, binding of the radiotracer to an abnormal protein or another unknown substance, and active uptake by the rapidly proliferating tumor tissue. Increased capillary permeability leading to extravasation appears to be the most attractive hypothesis; however, there is no definite proof.

References

1. McAfee JG, Gagne G, Atkins HL, et al: Biological distribution and excretion of DTPA labeled with Tc-99m and In-111. *J Nucl Med* 20:1273-1278, 1979
2. Lunia S, Lunia C, Philip PK: Accumulation of Tc-99m-

- DTPA in uterine myoma. *Clin Nucl Med* 5:272-273, 1980
3. Tyler JL, Powers TA: Tc-99m DTPA uptake in soft tissue sarcoma. *Clin Nucl Med* 7:357-358, 1982
4. Pedell L, Fink-Bennett D: Technetium-99m DTPA splenic uptake. *J Nucl Med* 22:798-799, 1981
5. Kadir S, Strauss HW: Evaluation of inflammatory bowel disease with 99mTc-DTPA. *Radiology* 130:443-446, 1979
6. Alevizaki-Harhalaki M, Alevizaki C, Georgiou E, et al: Increased Tc-99m DTPA uptake in active Graves' ophthalmopathy and pretibial myxedema. *J Nucl Med* 24:174-176, 1983
7. Cuschieri A, Hutchinson F, Neill GDS: Scintiscanning of the breast with 99mTc-diethylene triamine penta-acetic acid—A prospective blind evaluation. *Br J Surg* 68:147-149, 1981
8. Mandell GA, Herrick WC, Harcke HT, et al: Localization of neurofibromas by scanning with technetium-99m diethylene triamine-penta acetic acid (Tc-99m DTPA). *J Nucl Med* 26: P10, 1985 (abstr)

Aslam R. Siddiqui
James Whitcomb Riley
Hospital for Children
Indianapolis School of Medicine
Indianapolis, Indiana