
Evaluation in Femoral Neck Fracture Scintimetry: Modes of Region of Interest Selection and Influence on Results

Sven Holmberg, Laszlo Mesko, Björn Strömqvist, and Karl-Göran Thorngren

Departments of Orthopaedics and Nuclear Medicine, Danderyd University Hospital; and Department of Orthopaedics, Lund University Hospital, Sweden

Different sized ROIs within the femoral head and different modes of calculation were used in [^{99m}Tc]MDP scintimetry after femoral neck fracture. In preoperative scintimetry, correction for increased trochanteric uptake gave the best discrimination, whereas in postoperative scintimetry the direct ratio fractured/intact femoral head was superior. The change in ROI size had little influence.

J Nucl Med 26:353-356, 1985

For prognostic assessment after femoral neck fracture, scintimetry has been proven increasingly useful since the introduction (1) of technetium-labeled compounds. Most previous studies have used visual (scintigraphic) evaluation (2-5). Quantitative technetium uptake determination (scintimetry) after hip fracture was introduced in 1980 by Bauer et al. (6) and has since proven superior to visual evaluation (7-9). In the postoperative evaluation after femoral neck fracture, a ratio has usually been formed between the fractured and nonfractured side using determinations from regions of interest (ROIs) within the femoral heads (7). In a study of preoperative scintimetry for femoral neck fracture (9) an increased uptake distal to the fracture was found and compensated for in the ratio. The present study was undertaken with the intention to study the relationship between various ways of evaluating the pre- as well as postoperative activity within the femoral head after fracture of the femoral neck in order to facilitate the comparison between various investigations. The uptake in normal hips was also determined.

MATERIALS AND METHODS

Each patient was given an i.v. injection of 340-370

MBq technetium-99m methylene diphosphonate ([^{99m}Tc]MDP). Detailed antero-posterior images of the pelvis, including the upper third of both femurs, were recorded 3-5 hr after injection. A gamma camera* with a parallel-hole collimator connected to a dedicated computer system† was used to allow storage of the images for display and analysis.

Preoperative scintimetry investigations of 32 fresh femoral neck fractures from the recent study by Holmberg and Thorngren (9) were scrutinized. Twenty-seven of the investigations were performed in females, five in males. The mean age of the patients was 78 yr (range 52-91 yr). Seven of the patients had a fracture dislocation corresponding to Gardens Stage I, five to Stage III, and 20 to Stage IV.

In these preoperative scintimetries, ROIs were selected over the femoral head and trochanteric region in two different ways. Square regions, large enough to contain the whole of the femoral head as described by Holmberg and Thorngren (9), were chosen as well as smaller ROIs contained within the femoral head as described by Strömqvist et al. (8). Uptake per picture element was determined and a ratio obtained taking into consideration the increased uptake of the trochanteric region on the fractured side, $A \times D/B \times C$ where A = fractured femoral head; B = unfractured femoral head; C = fractured trochanter; and D = unfractured trochanter. These calculations with trochanteric compensation (T) were made for the larger (ratio TL) as well

Received Sept. 17, 1984; revision accepted Jan. 22, 1985.

For reprints contact: Sven Holmberg, Dept. of Orthopaedics, Danderyd Hospital, S-18288 Danderyd, Sweden.

TABLE 1
Relation Between Various Ratios in Femoral Neck Fracture Scintimetry Indicated with Correlation Matrix for Regression Analysis Showing Correlation Coefficients*

Item	Ratio TL	Ratio TS	Ratio UL	Ratio US
Ratio TL	1.000	—	—	—
Ratio TS	0.946	1.000	—	—
Ratio UL	0.776	0.769	1.000	—
Ratio US	0.778	0.770	0.958	1.000

* Femoral head ratios calculated with trochanteric compensation (T) or uncompensated (U) on values from large (L) or small (S) ROIs.

as the smaller (ratio TS) ROIs and the uncompensated (U) uptake ratio A/B was made comparing the femoral head on the fractured side to that on the intact side (ratio UL for large regions and ratio US for small regions) as described by Strömqvist (7).

From the material of postoperative scintimetric investigations presented by Strömqvist (7), 32 separate scintimetric images were selected where age, sex, and fracture displacement were matched to the material of preoperative scintimetries described above. In these scintimetries small ROIs were selected and uptake ratios determined with (TS) and without (US) taking the trochanteric uptake increase into consideration.

To determine the uptake in femoral heads not frac-

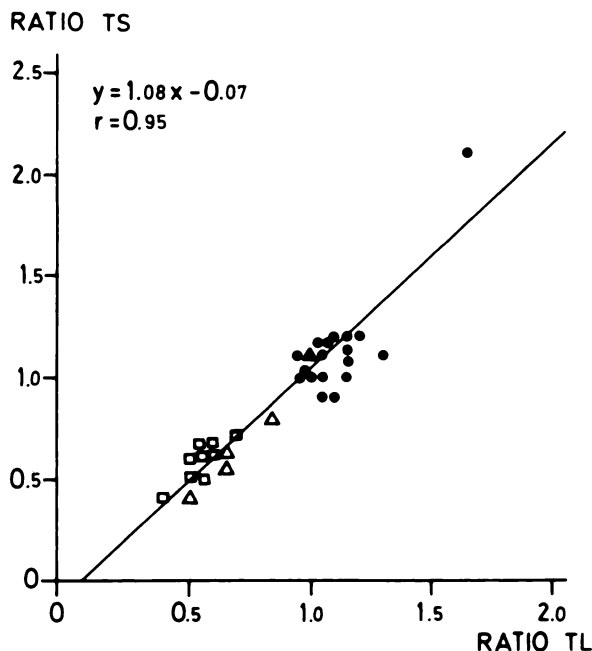


FIGURE 1
Correlation of ratio TL and ratio TS in preoperative scintimetry study. T = Calculation with trochanteric compensation; L = large and S = small ROI. (●) Uneventful healing; (▲) Early redisplacement; (△) Nonunion; (□) Segmental collapse

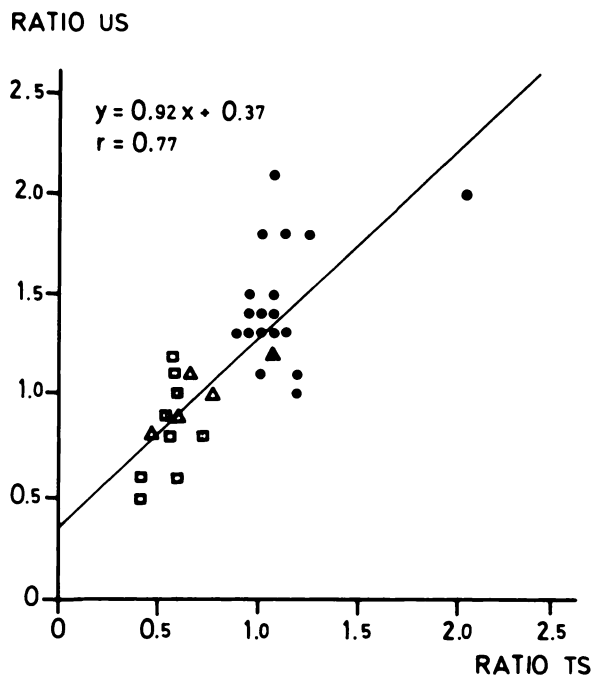


FIGURE 2
Correlation of ratio TS and ratio US in preoperative scintimetry study. T = Calculation with and U = without trochanteric compensation; L = large and S = small ROI. For explanation of symbols see Fig. 1

tured or diseased, ten images were taken in association with a scintigraphic examination of other parts of the patients' skeleton. Regions of interest and ratio determination were performed as for the preoperative scintimetries.

RESULTS

Preoperative scintimetry

When the two different sizes for the ROIs were compared for the same way of calculation (ratio TL compared with ratio TS, Fig. 1 and ratio US compared with UL, Fig. 3), a very high correlation coefficient above 0.95 was found. This indicates that the extent of the area within the femoral head does not influence the numerical evaluation. When the two different ways of calculation were compared for the small ROI (ratio TS, compared with ratio US, Fig. 2) a less pronounced but still high correlation was found ($r = 0.77$) indicating that the mode of calculation had some influence on the ratio in these preoperative scintimetries. This was also found for the large ROIs and the further addition to the mode of calculation of different sizes for the ROIs in the comparison did not change the correlation coefficient as shown in the correlation matrix for all the different ratio combinations (Table 1). Using the regression equations it is possible to transform between the ratios (Figs. 1 to 3). For prognostic purpose the highest discrimination

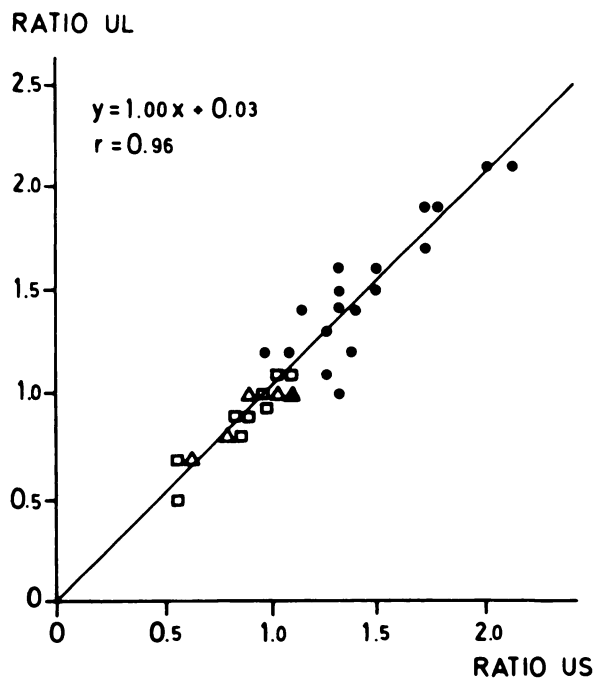


FIGURE 3
Correlation of ratio US and ratio UL in preoperative scintimetry study. For explanation of symbols see Figs. 1 and 2

between cases with good and bad outcome was found with the mode of calculation including correction for trochanteric uptake (Figs. 1 and 3).

Postoperative scintimetry

For the postoperative scintimetries the correlation between ratio US and ratio TS was low (Fig. 4). For

prognostic purpose the highest discrimination between cases with good and bad outcome was found with the mode of calculation without correction for trochanteric uptake. For ratio US the border between favorable and unfavorable prognosis lay just above 1.0 while no such distinct border could be found when using ratio TS in the postoperative scintimetry values (Fig. 4).

Scintimetry of normal hips

Calculated with trochanteric compensation, the ratio between scintimetric femoral head uptake from right compared with left femoral head was 1.05 ± 0.08 (mean \pm s.d.) and from left compared with right it was 0.96 ± 0.07 . The corresponding femoral head ratio calculated without trochanteric compensation was 1.03 ± 0.04 (right compared with left) and 0.98 ± 0.03 (left compared with right).

Thus, in the scintimetries performed on unfractured hips a somewhat larger but insignificant ($p > 0.05$) variation of 7.6% (s.d. in relation to mean value) was seen when the trochanteric compensation was used. Without compensation for trochanteric uptake the variation was 3.5%. Taking into consideration the possibility that either the right or left femoral neck might be fractured, the range (mean \pm s.d.) for the ratio as determined with the larger ROI would be 0.89–1.13 with trochanteric compensation and 0.94–1.06 without trochanteric compensation.

DISCUSSION

An early prognosis of the long-term outcome after femoral neck fracture can be made by determining the femoral head circulation through [^{99m}Tc]MDP scin-

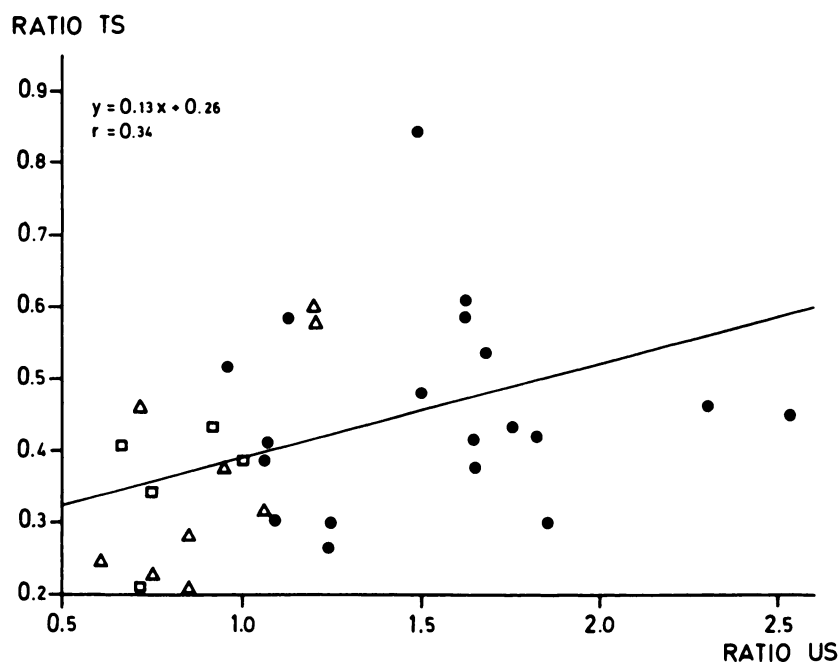


FIGURE 4
Correlation of ratio US and ratio TS in postoperative scintimetry study. For explanation of symbols see Figs. 1 and 2

timetry. An individual prognostic information can thus be given the patient. After osteosynthesis, cases with predicted uneventful healing can then be left without hip controls whereas those prone for complications, e.g., pseudarthrosis or femoral head necrosis can be checked regularly with early intervention if symptoms appear. In centers practicing primary hemiarthroplasty after femoral neck fractures, a preoperative scintimetry should be mandatory, otherwise many vital femoral heads are erroneously replaced.

In preoperative scintimetries after femoral neck fracture, an increased scintimetric uptake in the surrounding bone tissue has been observed (7-9), and this may be a probable explanation as to why external radiotracer determination yields higher values than biopsy determination in femoral neck fracture, as shown recently by Strömqvist et al. (10). In accordance with this observation, the calculations including correction for trochanteric uptake were found to be of best prognostic discrimination, in spite of the fact that the measurement precision decreased when further ROIs were introduced as shown by the scintimetry of normal hips. After osteosynthesis, on the other hand, the operative trauma has inflicted hyperemia in the penetrated bone tissue which gives a much higher scintimetric uptake than that observed in surrounding bone preoperatively after femoral neck fracture. The uptake in the trochanteric region has been shown to remain elevated for several years after femoral neck fracture with the highest value at 4 mo postoperatively (8). This explains why the best prognostic outcome in postoperative scintimetry was found with the ratio between the femoral head uptake without correction for trochanteric uptake. The investigated variation in size of the ROI did not change the results.

In conclusion, for scintimetry after femoral neck fractures, the correction for trochanteric uptake is recommended in preoperative but not in postoperative scintimetry.

FOOTNOTES

* General Electric Maxi.

† Gamma-11.

ACKNOWLEDGMENT

The investigation was supported by the Swedish Medical Research Council (Project 17 X-2031).

REFERENCES

1. Subramanian G, McAfee JG: A new complex of ^{99m}Tc for skeletal imaging. *Radiology* 99:192-196, 1971
2. D'Ambrosia RD, Riggins R, Stadalnik R, et al: Vascularity of the femoral head. *Clin Orthop* 121:143-148, 1976
3. Meyers MH, Telfer N, Moore TM: Determination of the vascularity of the femoral head with technetium 99m-sulphur-colloid. *J Bone Joint Surg* 59A:658-664, 1977
4. Greiff J, Lanng S, Höilund-Carlson PF, et al: Early detection by ^{99m}Tc -Sn-pyrophosphate scintigraphy of femoral head necrosis following medial femoral neck fractures. *Acta Orthop Scand* 51:119-125, 1980
5. Turner JH: Post-traumatic avascular necrosis of the femoral head predicted by preoperative technetium-99m antimony-colloid scan. *J Bone Joint Surg* 65A:786-797, 1983
6. Bauer G, Weber DA, Ceder L, et al: Dynamics of technetium-99m methylenediphosphonate imaging of the femoral head after hip fracture. *Clin Orthop* 152:85-92, 1980
7. Strömqvist B: Femoral head vitality after intracapsular hip fracture. *Acta Orthop Scand* 54 (Suppl 200):1-71, 1983
8. Strömqvist B, Brismar J, Hansson LI, et al: Technetium-99m-methylenediphosphonate scintimetry after femoral neck fracture—A three-year follow-up study. *Clin Orthop* 182:177-189, 1984
9. Holmberg S, Thorngren K-G: Preoperative ^{99m}Tc -MDP scintimetry of femoral neck fractures. *Acta Orthop Scand* 55:430-435, 1984
10. Strömqvist B, Brismar J, Hansson LI, et al: External and biopsy determination of preoperative Tc-99m femoral-head labeling in fracture of the femoral neck. *J Nucl Med* 25:854-858, 1984