

DIAGNOSTIC NUCLEAR MEDICINE

Bone and Liver Images in Medullary Carcinoma of the Thyroid Gland:  
Concise Communication

Donald G. Johnson, R. Edward Coleman, Thomas A. McCook, Janet K. Dale, and Samuel A. Wells

*Duke University Medical Center, Durham, North Carolina*

**Thirty-four patients with surgically documented medullary carcinoma of the thyroid (MCT) and elevated serum calcitonin levels had Tc-99m phosphate bone and/or Tc-99m sulfur colloid liver images for suspected metastases. Liver images demonstrated metastatic lesions in nine of 32 patients (28%). Bone images were positive for metastases in eight of 30 patients (27%). Four of these eight abnormal bone studies detected only skeletal lesions, two demonstrated only extraosseous metastases, and two showed both kinds. Of 18 patients with both radionuclide bone studies and skeletal radiographs, four demonstrated skeletal metastases, and lesions were recognized on both examinations. This study demonstrates that radionuclide bone and liver images frequently detect metastatic lesions in patients with MCT and elevated serum calcitonin levels, and that some nonskeletal metastases in patients with this tumor display an unusual affinity for bone-seeking radiotracers.**

**J Nucl Med 25: 419-422, 1984**

Medullary carcinoma of the thyroid (MCT) is a tumor arising from the thyroid parafollicular cells, and secretes the polypeptide hormone calcitonin. MCT accounts for 5-10% of all thyroid malignancies, is often familial, and frequently appears in young patients. Because the tumor is aggressive and metastasizes early, the treatment of choice is total thyroidectomy followed by careful clinical and biochemical follow-up. After surgical removal of the thyroid and local disease, elevation of serum calcitonin in a patient together with local disease, indicates the presence of metastases even though the patient may be asymptomatic (1). Radionuclide bone and liver-spleen scintigrams have been used in our institution to delineate metastatic disease in these patients with abnormal basal or stimulated calcitonin levels.

The purpose of this study was to determine the frequency of metastatic lesions detected by radionuclide bone and liver studies in postoperative MCT patients with elevated serum calcitonin levels.

Received July 5, 1983; revision accepted Nov. 3, 1983.

For reprints contact: Donald G. Johnson, MD, Dept. of Radiology, Box 3808, Duke University Med. Ctr., Durham, NC 27710.

METHODS

Thirty-four patients with surgically proven MCT who were followed at our medical center from 1968 to 1981 had liver-spleen studies and/or bone images. Every patient had previous total thyroidectomy and had elevated basal or stimulated serum calcitonin. The ages ranged from 7 to 66 yr (mean of 35.1); there were 16 females and 18 males. Nine patients had sporadic MCT. In the others the disease was familial and the MCT was a component of one of the multiple endocrine neoplasia Type II syndromes (2).

Liver-spleen studies were performed in 32 patients following intravenous administration of 3-5 mCi of Tc-99m sulfur colloid. Fifteen patients had several (from one to seven) liver-spleen images. Bone scintigraphy was performed in 30 patients 2 to 3 hr after intravenous administration of ~20 mCi of a Tc-99m phosphate radiopharmaceutical. Ten patients had multiple bone studies. Skeletal radiographs of symptomatic areas or of areas found abnormal on bone images were available for review in 18 of the 30 patients with radionuclide bone studies.

**TABLE 1. LOCATION OF METASTATIC LESIONS DETECTED BY BONE IMAGES**

| Case number | Age at diagnosis | Sex    | Skeletal metastases   |   | Extrasosseous metastases  |
|-------------|------------------|--------|---|---|---|
|             |                  |        | Bone scintigram   | Skeletal radiographs  |   |
| 1           | 53               | Male   | Fourth and eleventh thoracic and second lumbar vertebrae    | Diffuse lytic lesions throughout thoracic and lumbar spine      | None  |
| 2           | 44               | Male   | Right ilium, right scapula, and several left posterior ribs | Lytic lesions corresponding to abnormal areas on bone images    | None  |
| 3           | 51               | Male   | Widespread axial and appendicular                           | Widespread, mixed lytic and blastic lesions                     | None  |
| 4           | 37               | Male   | Left anterior first rib and right orbit                     | Lytic left first rib lesion. Skull and sinus radiographs normal | None  |
| 5           | 46               | Male   | Multiple anterior ribs and seventh thoracic vertebra        | Not available   | Liver   |
| 6           | 39               | Male   | Both iliac crests   | Not obtained. (Pelvic radiographs 18 mo earlier were normal.)   | Liver   |
| 7           | 19               | Female | None  | No abnormal calcification in region of extrasosseous uptake     | Liver and left cervical nodes                                     |
| 8           | 18               | Male   | None  | No abnormal calcification in region of extrasosseous uptake     | Right cervical node, bilateral hilar nodes, and mediastinal nodes |

Liver-spleen studies were considered positive for metastases when well-defined focal liver or spleen defects increased in size on serial examinations. In only one patient was a single liver-spleen study interpreted as being positive for hepatic metastases: he was 21 yr old and had no history of liver disease, but multiple, well-circumscribed, photon-deficient regions were present within his liver. The presence of hepatomegaly, liver inhomogeneity, or splenomegaly were not interpreted as representing metastases.

Skeletal abnormalities on bone scintigrams were considered to represent metastatic foci if (a) the abnormalities were substantiated and suggestive of metastases on skeletal radiographs, (b) the abnormalities were in a region removed from areas typically affected by traumatic or degenerative abnormalities and were multiple, or (c) the abnormal areas progressed in size or number when sequential bone images were obtained.

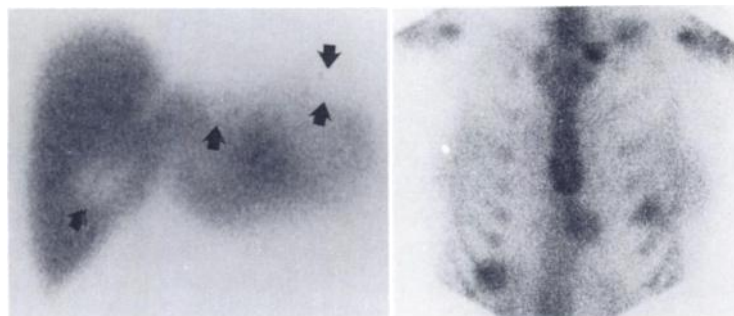
#### RESULTS

Liver-spleen images demonstrated metastatic foci in nine of the 32 patients (28%). Eight patients had liver

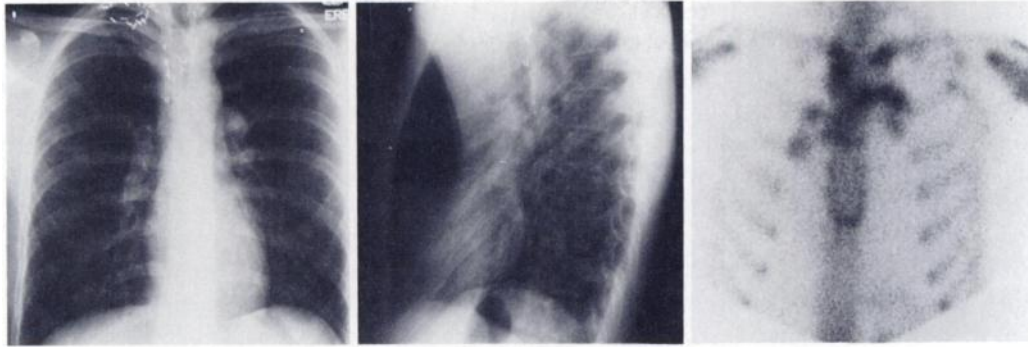
metastases and one had splenic metastatic disease verified on sequential images.

Metastatic disease was present in eight of the 30 patients (27%) who had bone scintigrams (Table 1). Although skeletal metastases were present in six patients, two other patients demonstrated the presence of the bone-seeking agent within liver or lymph-node metastases without skeletal abnormalities (Figs. 1 and 2). Four patients showed definite uptake of the bone-seeking tracer by nonskeletal metastases. Lesions were not biopsied in any of these four patients. The liver lesions were presumed to be metastases because of progressive abnormality on serial liver scintigrams. Also, all three patients with abnormal focal accumulation noted in the region of the liver on bone image had corresponding photon-deficient lesions in the liver. Mediastinal and hilar-node metastases were suspected by radiographic criteria, and cervical-node metastases were established by clinical criteria.

Eighteen patients with bone images had skeletal radiographs available for correlation. Four patients demonstrated metastases, and abnormalities were present



**FIG. 1.** Multiple liver metastases in 19-yr-old woman. Anterior scintiphoto shows 3 well-defined regions of decreased activity (arrows), including one high in lateral segment of left lobe. Anterior bone image of thorax and abdomen shows abnormal tracer accumulation in 3 metastatic liver lesions, also metastases in lymph nodes in left supraclavicular fossa.



**FIG. 2.** Metastases to mediastinal nodes in 18-yr-old man. PA and lateral chest radiographs demonstrate hilar and mediastinal adenopathy in spite of previous extensive surgery. Anterior bone scintigram shows abnormal tracer accumulation in mediastinal nodes.

on both radionuclide and radiographic examinations in all patients. In one patient, however, a right orbital lesion detected by bone study was not detectable on radiographs of the skull and sinuses, although another lesion in the same patient was present on both examinations.

Of the 34 patients in this study, 11 had positive bone or liver-spleen studies. Six of these 11 were sporadic, and five were familial. See Table 2 for further data regarding image findings with respect to time course and family history.

#### DISCUSSION

Medullary carcinoma of the thyroid is a malignant neoplasm that secretes the peptide hormone calcitonin. Elevation of this substance in the blood heralds the presence of MCT, and indeed, patients who have either elevated basal calcitonin or abnormal response to known provocative agents, such as pentagastrin or calcium gluconate, should be considered to have tumor (1-4). Therefore, imaging studies may not be necessary to es-

tablish the initial diagnosis of this disease. Also, these patients frequently have a positive family history, since MCT may be a component of multiple endocrine neoplasia syndrome Type II (MEN-II), a hereditary disease transmitted in an autosomal dominant fashion and consisting of the triad of MCT, pheochromocytoma(s), and parathyroid abnormalities (2).

Localization of widespread disease, or delineation of recurrent disease following thyroidectomy, may be difficult on clinical grounds alone, since some thyroidectomized patients have calcitonin excess but no clinical disease (5). Radionuclide liver-spleen and bone studies have been advocated as screening tests in the management of these patients (6,7), since the major sites of distant metastases are lung, liver, and bone (5,7). However, the frequency of abnormalities detected by these two radionuclide procedures in patients with MCT and elevated serum calcitonin levels has not been previously addressed.

The present study is retrospective and makes no attempt to determine the accuracy of liver-spleen and bone

**TABLE 2. SCINTIGRAPHIC FINDINGS WITH RESPECT TO DISEASE COURSE AND FAMILY HISTORY**

| Case number | Family history | Age at diagnosis | Sex    | Time course* |              |
|-------------|----------------|------------------|--------|--------------|--------------|
|             |                |                  |        | Bone image   | Liver image  |
| 1           | S <sup>†</sup> | 53               | Male   | 6            | 21           |
| 2           | S              | 44               | Male   | 16           | 28           |
| 3           | S              | 51               | Male   | At diagnosis | 33           |
| 4           | S              | 37               | Male   | At diagnosis | —            |
| 5           | S              | 46               | Male   | At diagnosis | 21           |
| 6           | F              | 39               | Male   | At diagnosis | At diagnosis |
| 7           | S              | 19               | Female | 50           | 61           |
| 8           | F <sup>‡</sup> | 18               | Male   | At diagnosis | —            |
| 9           | F              | 12               | Male   | —            | 32           |
| 10          | F              | 21               | Female | —            | At diagnosis |
| 11          | F              | 52               | Female | —            | At diagnosis |

\* Time (months) from initial diagnosis for development of positive image.

<sup>†</sup> S = sporadic.

<sup>‡</sup> F = familial.

studies but, rather, determines how often these radionuclide procedures revealed metastatic disease in post-operative patients with biochemical evidence of recurrent or residual disease. Our study found that each of these procedures detects metastatic disease in approximately 30% of the patients. Thus, these tests are useful in defining metastatic disease to the liver and skeleton in this patient population.

We have found radionuclide bone and liver studies useful in the management of patients with MCT. In those who have not yet undergone thyroidectomy, the management of the primary lesion is relatively conservative if liver or bone scintigrams are positive; segmental thyroidectomy is performed rather than radical neck dissection, which may be carried out if no distant metastatic disease is suspected. Although elevated calcitonin values before surgery have been shown to be useful in establishing extent of disease (8), biochemical parameters cannot locate the site(s) of metastasis. Similarly, elevated calcitonin values following surgery may be seen in patients without residual or recurrent disease (9); radionuclide bone and liver studies may be useful in following such patients. Finally, bone and liver scintigraphy provide prognostic information, since patients who develop metastatic disease following thyroidectomy have a poorer prognosis (10).

Of eight patients with liver metastases, three demonstrated the presence of bone-seeking tracer activity corresponding to the areas of abnormality on liver image (see Fig. 1), and another patient demonstrated bone-tracer activity in mediastinal and hilar lymph-node metastases (see Fig. 2). The propensity for extraosseous metastases to accumulate bone seekers may be related to the known tendency of the tumor to undergo calcification, since radiographically detected calcification of the primary tumor and metastatic foci is common in patients with MCT (7,11,12). Amyloid is frequently found in association with MCT (13), and bone-imaging agents are avidly taken up in amyloid deposits (14), which may also explain the predisposition for this tumor to be seen on bone scintigrams.

Eighteen patients had bone images and skeletal radiographs, of which four were found to have metastases to bone. Every lesion identified on skeletal radiographs was also identified on the bone scintigram. Thus it appears that both examinations are not necessary.

We note that six of the nine patients with sporadic MCT had positive bone images, compared with only three of the 25 patients with familial MCT. This probably relates to the earlier diagnosis and treatment of patients with a known family history, before the disease became extensive.

In summary, liver-spleen and bone studies are positive in 28% and 27%, respectively, of patients with known MCT and elevated serum calcitonin levels. Some ex-

traosseous metastatic lesions have an affinity for bone-seeking radiotracers, and physicians interpreting these bone images should be aware of this affinity. Two patients in our study had extraosseous abnormalities without associated skeletal metastatic lesions, and the studies would have been interpreted as normal if uptake of the tracer within soft-tissue metastases had not been noted. Because of the high rate of positive liver and bone scintigrams in patients with known MCT, these studies are useful in the management of these patients. These studies are also used in planning the management of the primary thyroid lesion, since surgery is often more conservative if distant metastases are discovered before thyroidectomy.

#### REFERENCES

1. WELLS SA, BAYLIN SB, LINEHAN WM, et al: Provocative agents and the diagnosis of medullary carcinoma of the thyroid gland. *Ann Surg* 188:139-141, 1978
2. KEISER HR, BEAVEN MA, DOPPMAN J, et al: Sipple's syndrome: Medullary carcinoma, pheochromocytoma, and parathyroid disease. *Ann Intern Med* 78:561-579, 1973
3. ANDERSON RJ, SIZEMORE GW, WAHNER HW, et al: Thyroid scintigram in familial medullary carcinoma of the thyroid gland. *Clin Nucl Med* 3:147-151, 1978
4. WELLS SA, ONTJES DA, COOPER CW, et al: The early diagnosis of medullary carcinoma of the thyroid gland in patients with multiple endocrine neoplasia type II. *Ann Surg* 182:362-370, 1975
5. SIZEMORE GW, CARNEY JA, HEATH H III: Epidemiology of medullary carcinoma of the thyroid gland: A 5-year experience (1971 to 1976). *Surg Clin North Am* 57:633-645, 1977
6. BAYLIN SB: Medullary carcinoma of the thyroid gland: use of biochemical parameters in detection and surgical management of the tumor. *Surg Clin North Am* 54:309-323, 1974
7. MCCOOK TA, PUTMAN CE, DALE JK, et al: Medullary carcinoma of the thyroid: Radiographic features of a unique tumor. *Am J Roentgenol* 139:149-155, 1982
8. WELLS SA, BAYLIN SB, LEIGHT GS, et al: The importance of early diagnosis in patients with hereditary medullary thyroid carcinoma. *Ann Surg* 195:595-599, 1982
9. BECKER KL, SILVA OL, SNIDER RH, et al: The surgical implications of hypercalcitonemia. *Surg Gynecol Obstet* 154:897-908, 1982
10. WELLS SA, ONTJES DA: Multiple endocrine neoplasia type II. *Annu Rev Med* 27:263-268, 1976
11. PEARSON KD, WELLS SA, KEISER HR: Familial medullary carcinoma of the thyroid, adrenal pheochromocytoma and parathyroid hyperplasia: a syndrome of multiple endocrine neoplasia. *Radiology* 107:249-256, 1973
12. WALLACE S, HILL CS, PAULUS DD, et al: The radiologic aspects of medullary (solid) thyroid carcinoma. *Radiol Clin North Am* 8:463-474, 1970
13. FLETCHER JR: Medullary (solid) carcinoma of the thyroid gland. *Arch Surg* 100:257-262, 1970
14. LEE VW, CALDARONE AG, FALK RH, et al: Amyloidosis of heart and liver: Comparison of Tc-99m pyrophosphate and Tc-99m methylene diphosphonate for detection. *Radiology* 148:239-242, 1983