

Tc^{99m} Pertechnetate for Brain Scanning

McAfee, J. G.; Fueger, C. F.; Stern, H. S.; Wagner, H. N., Jr. and Migita, T.^{1,2}

Baltimore

Element No. 43, the metal technetium, "the artificial one", was discovered by Segré in 1937. This element was so named because it does not exist in nature. All of its nuclides are radioactive. Together with manganese and rhenium it forms group VII A of the periodic table of elements, and its chemical behavior is similar to rhenium (1, 5). Similarities have been noted in the biological behavior between pertechnetate ions and the halogens, which form group VII B of the periodic table. Concentration of pertechnetate in the thyroid of animals was demonstrated by Baumann (2). In 1963, the gamma emissions of the nuclide Tc^{99m} were first used clinically for visualization of the liver by scintillation scanning, following administration and hepatic localization of the parent nuclide molybdenum Mo^{99} (19, 20) Harper *et al* (10) first administered Tc^{99m} parenterally for scintillation scanning of the thyroid gland and later for the localization of brain tumors. Since January, 1964, we have used this material routinely for brain scanning, because of its ideal physical characteristics. The short physical half-life of six hours, the absence of beta emission, and the gamma emission of 140 kev permitted the administration of large amounts of radioactivity (1 to 10 mc) without excessive irradiation of the patient. Because of the higher counting rates obtained, the statistical variations in count rate were minimized, and the technique of brain scanning was much improved compared with older agents such as I^{131} serum albumin and Hg^{203} or Hg^{197} chlormerodrin.

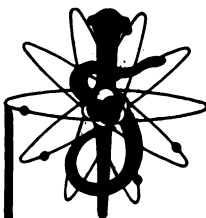
In this paper, the applicability of Tc^{99m} pertechnetate as an agent for brain scanning, the tissue distribution in animals, and man, and the relative merits of oral vs intravenous modes of administration are discussed.

MATERIAL

The Mo^{99} - Tc^{99m} generator is supplied by the Brookhaven National Laboratory on a regularly scheduled basis (3). 100 or 200 mc quantities of Mo^{99} are adsorbed on a 10 gm chromatographic alumina column in a small, disposable lucite tube. Maximum growth of radioactivity of the daughter Tc^{99m} occurs in

¹From the Departments of Radiology and Radiological Science, The Johns Hopkins Schools of Medicine, Hygiene and Public Health.

²This work was supported by USPHS Grant No. GM-10548.



23 hours. With daily elution of the column, approximately 80 per cent of the radioactivity of the parent Mo^{99} is eluted as Tc^{99m} . Because the physical half-life of Mo^{99} is 2.7 days, each column may be used over a period of about 10 days. Since January, 1964, the radiochemical purity of the Mo^{99} generators has been greatly improved. The contaminants molybdenum Mo^{99} , ruthenium Ru^{103} , and iodine I^{131} are now present in negligible concentrations (17).

The addition of a small column of Dowex-50-X-8 cation exchange resin to the lower end of the generator has reduced or eliminated from the eluate the stable sodium and aluminum oxide from the alumina column.

PREPARATION OF RADIOACTIVE MATERIAL FOR INTRAVENOUS INJECTION

The Mo^{99} - Tc^{99m} generator is mounted on a laboratory stand behind a shield of lead and lead-glass bricks for protection of the laboratory personnel. Each morning, the column is eluted with 20 ml 0.1 N HCl. Only 3 per cent of the total Tc^{99m} activity is eluted with the first 5 ml, but 95 per cent is eluted from 5 to 20 ml. A preliminary elution of 8 to 10 ml is discarded from each generator after arrival, to eliminate radiocontaminants. The HCl reagent is prepared with pyrogen-free water suitable for intravenous injection.

The eluate is neutralized by slow titration with 1 N NaOH (also prepared with pyrogen-free water) until the pH is within the range of 6 to 8, measured with pH paper. The neutralized solution is slightly hypotonic, has an approximate volume of 22 ml and the eluted radioactivity may range from 20 to 100 mc of Tc^{99m} , depending on the age of the column.

Radioassay must be carried out routinely prior to human use. This may be accomplished within two or three minutes, using a large well-type ionization chamber and electrometer,¹ by comparison with a 10 mc standard of Co^{57} . This method avoids the necessity of making an accurate dilution of the eluate each day for comparison with a weak Co^{57} standard in a well scintillation counter. The dilution method of assay, however, should be used initially for intercalibration of the ion chamber (17). The assay with the ionization chamber should be within 2 per cent of the assay with a scintillation counter. Calibration with a Lauritsen electroscope, using a radium standard, is unsatisfactory, since the assays of technetium are approximately 30 per cent too high with this method.

The material is sterilized by autoclaving in a rubber capped 30 cc vial at 260° F at a pressure of 121 psi for 15 minutes. Alternatively, the material may be more quickly sterilized by transfer from one sterile, disposable polypropylene syringe to another through a Millipore filter.² Despite the fact that the technetium is carrier-free, negligible amounts of radioactivity become adsorbed to syringes, glassware, waxed paper cups, etc. compared with carrier-free radioiodine.

Preceding the intravenous injection of 10 mc of Tc^{99m} , the patient is given,

¹NE 014 beta-gamma ionization chamber and NE 503A electrometer D. C. amplifier. General Radiological, Ltd., Nuclear Engineering Division, Middlesex, England.

²Swinny hypodermic adapter or microsyringe filter holder with autoclaved HA type filter (mean pore size .45 μ), Millipore Filter Corp., Bedford, Mass.

by mouth, 200 mgm of potassium perchlorate dissolved in water. A second dose of potassium perchlorate should be given approximately eight hours later, since this drug, when used therapeutically, has been administered at 8-hour intervals (7). On the day following administration, the blood levels of radioactivity are so low that additional doses of perchlorate are unnecessary.

PREPARATION OF MATERIAL AND METHOD OF ORAL ADMINISTRATION


The reagents used when the technetium is given orally need not be sterile or pyrogen-free. The molybdenum generator is eluted with 20 ml of 0.1 N HCl without subsequent neutralization. Following radioassay, the vial of pertechnetate is placed in a lead pig behind a lead shield, ready for use.

The patient must be in the fasting state, and no food should be ingested for at least two hours following the oral administration. Potassium perchlorate (200 mgm) is dissolved in two ounces of tap water in a waxed paper cup and flavored with 1/2 oz of syrup of wild cherry. Finally, 10 mc of the Tc^{99m} solution are added, the solution stirred, and the patient instructed to drink the material through a straw. Immediately thereafter, the patient is given three ounces of tap water that has been added to the cup for rinsing. The patient is then asked to drink one ounce of sodium bicarbonate solution (3 gms completely dissolved in tap water). The total volume of fluid ingested is therefore 6½ ounces. A second dose of potassium perchlorate is administered on the evening following administration. The perchlorate is given chiefly for the suppression of gastric secretion of pertechnetate. The bicarbonate is given to temporarily neutralize the gastric acidity and to suppress the reduction of pertechnetate ions.

TECHNIQUE OF BRAIN SCANNING

In Harper's original technique (10), brain scanning was begun immediately following the intravenous injection of the Tc^{99m} pertechnetate. In this series, the scanning procedure was carried out between one and three hours following administration, because the blood levels were more stable during this interval than during the immediate postinjection period.

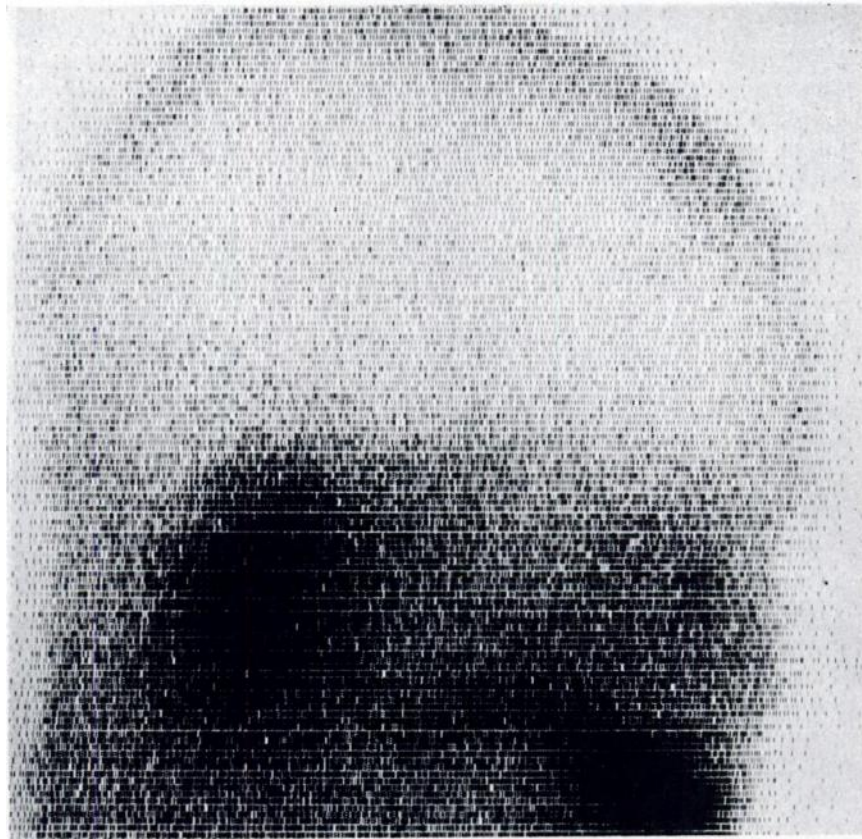With I^{131} albumin, the technique of scanning with a three-inch diameter NaI (Tl) crystal with a 19 hole focusing collimator has become standardized at many centers. Following an intravenous dose of 5.5 μ c/kg body weight, the average count rate over the temporal muscle is approximately 600 cpm and 150 to 300 cpm over normal brain areas. A linear scanning speed of six inches per minute and an index spacing of 3/16 of an inch for each scan line are ordinarily used (0.9 minutes/sq in of scanning area). Somewhat lower count rates are found three to five hours following the intravenous injection of Hg^{203} chlormerodrin, in doses of 11 μ c/kg body weight. By employing Tc^{99m} pertechnetate in doses of 10 mc, and the same scintillation crystal and collimator, the count rates are increased by a factor of eight to ten following an oral administration, and by a factor of 12 to 15 following an intravenous injection. The linear scanning speed may therefore be increased to 48 to 96 inches/minute; the total scan-



ning time can thus be greatly decreased while maintaining the same counting statistics. Alternatively, a combination of improved counting statistics and an increase in linear scanning speed by a factor of two or four may be obtained. When scintillation crystals five or eight inches in diameter are employed for scanning with Tc^{99m} pertechnetate, the sensitivity of detection may be increased further by factors of three and seven, respectively. Thus, both the required scanning time, and the counting statistics may be greatly improved simultaneously with a reduction in patient irradiation dosage.

RESULTS

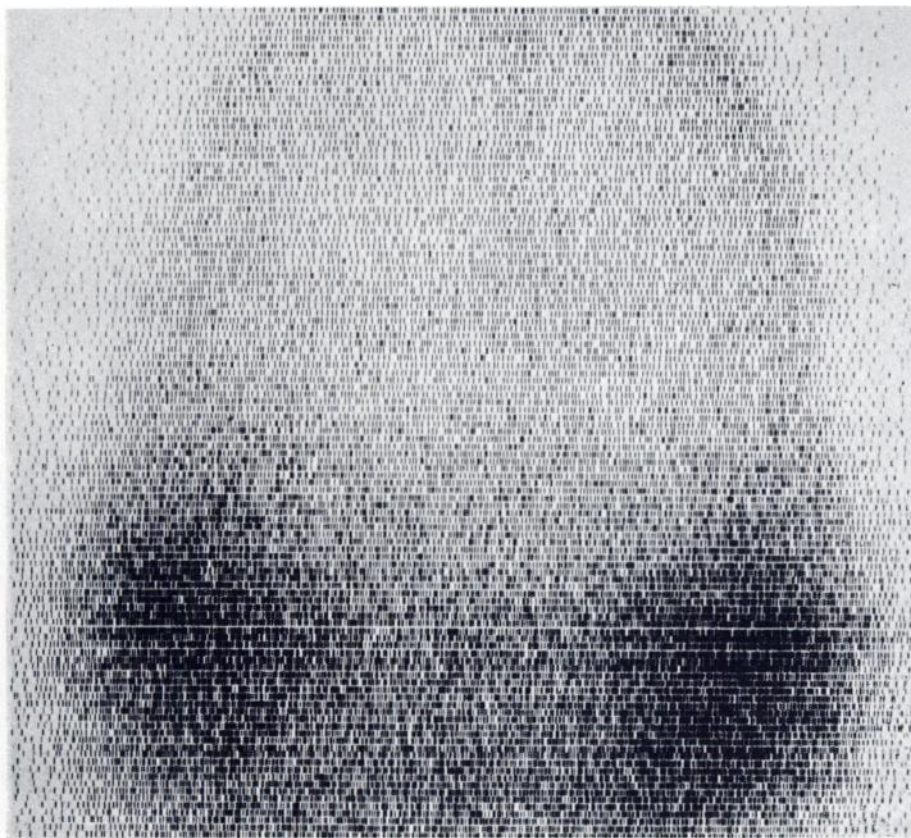
Brain scans using Tc^{99m} pertechnetate and an eight-inch diameter sodium iodide crystal are shown in Fig. 1. With this scanning agent, the vascular anatomical structures of the skull are more clearly seen than with previous agents, because of the higher levels of radioactivity in the bloodstream. These structures include the peripheral activity due to the vascularity of the scalp and superior sagittal sinus, the temporal muscle activity, the lateral dural sinus in the upper



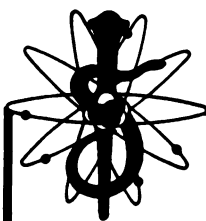
A

portion of the posterior fossa and the superficial cerebral veins close to the vertex. Additional areas of localized activity may be seen normally in the lower portion of the Sylvian fissure, probably due to the superficial middle cerebral vein, and in an area posteroinferior to the pineal gland, perhaps due to the junction of the inferior sagittal sinus, vein of Galen, and straight sinus. These two areas of normal activity were not observed with the older scanning agents. In addition, areas of extremely high activity are observed in the salivary and lacrimal glands. High activity is seen throughout the oral cavity due to the technetium concentration in saliva.

Clinical experience with this new agent to date is limited. Over a six-month interval from January through June, 1964, 137 brain scans were performed with pertechnetate on 133 patients, 52 by oral administration and the remainder by intravenous injection. Adequate followup was available on 121 of these patients. There were 22 proven intracranial tumors in this group—the brain scans correctly localized 16 of these; five were negative, and one was technically unsatisfactory. The overall diagnostic accuracy of 73 per cent is comparable to a figure of 71.5 per cent for a much larger series performed with other agents reported



B



previously. Moreover, no marked difference in diagnostic accuracy has been noted in comparative scans between I^{131} albumin and Hg^{203} chlormerodrin (15, 16). The five tumors that were missed by scanning in the present series included a grade I temporal astrocytoma, a purely cystic craniopharyngioma, a spongioblastoma of the optic chiasma, one instance of multiple metastases and one cerebello-pontine angle meningioma. An additional six patients had presumptive clinical evidence of intracranial tumors with positive brain scans and cerebral angiograms, but no histological proof.

Ten patients out of 133 had positive brain scan patterns due to nonneoplastic organic lesions. This incidence of 7.5 per cent is higher than in the previous series (14) (5%). These abnormalities included four instances of acute cerebrovascular accident, and one instance each of gross encephalomalacia, subdural hematoma, post-traumatic brain damage, meningocephalitis, radioactive gold seed hypophysectomy and one frontal lobe seed implantation for heat induction. Early in this series, there were six false-positive interpretations in patients whose subsequent work-up showed no evidence of organic brain disease. The areas of increased radioactivity in these cases were minimal, and in retrospect, were due

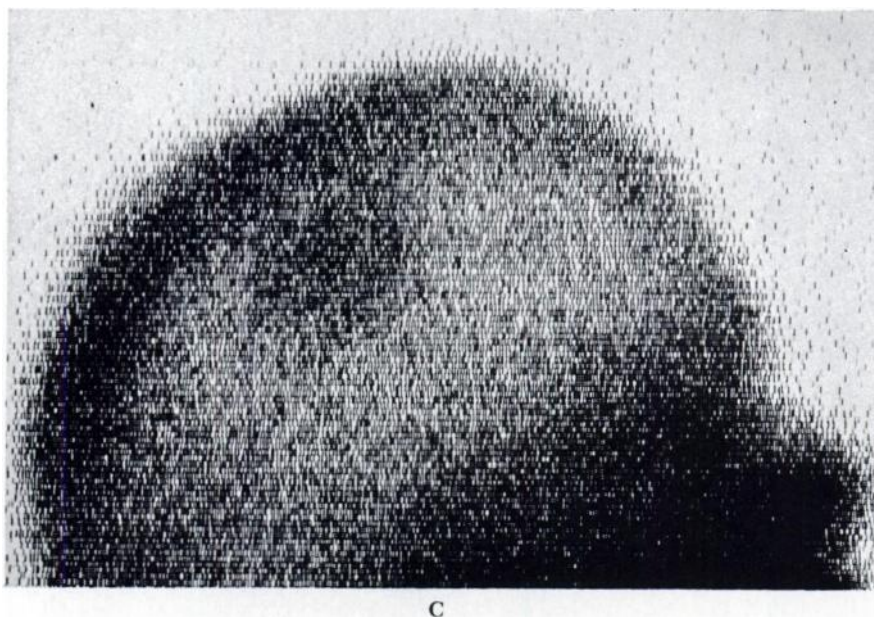


Fig. 1. Brain scans with Tc^{99m} pertechnetate

(A and B)—Lateral and posterior projections after IV dose, show no abnormality except burr-hole activity in superior frontal region. Note relatively uniform appearance of normal brain area achieved with average count rate of 45,000 cpm, well defined peripheral vascularity of skull, and marked activity in parotid and lacrimal glands, and oral cavity.

(C)—Lateral view one hour after oral dose, shows abnormal localized activity in parietal area due to a falx meningioma. Studies performed with 8-inch diameter crystal scanner, linear scanning speed 48 inches per minute.

merely to prominent superficial cerebral veins close to the superior sagittal sinus, usually parietal, or to deep vascular structures posteroinferior to the pineal gland. Later in the series, these errors in interpretation were avoided.

BIOLOGICAL FATE OF Tc^{99m} PERTECHNETATE IN MAN

The tissue distribution and/or excretion of Tc^{99m} pertechnetate was studied in 23 patients and triplicate studies were performed on six healthy male volunteers. Following an oral or intravenous dose of 10 mc, the excretion could be followed for a period of only 72 hours, because of the rapid radioactive decay.

The gastrointestinal absorption and tissue distribution of the labeled pertechnetate is similar in many respects to Iodide I^{131} . It becomes concentrated in the thyroid, salivary glands, and gastric mucosa. Like iodide (4), pertechnetate is most likely secreted by the mucoid cells of the gastric glands, and not by the peptic or oxyntic cells; the gastric secretions therefore probably do not closely



Fig. 2. Abdominal scan three hours following intravenous injection of Tc^{99m} pertechnetate shows high concentrations in stomach and duodenal loop, and even higher concentration in left colon.

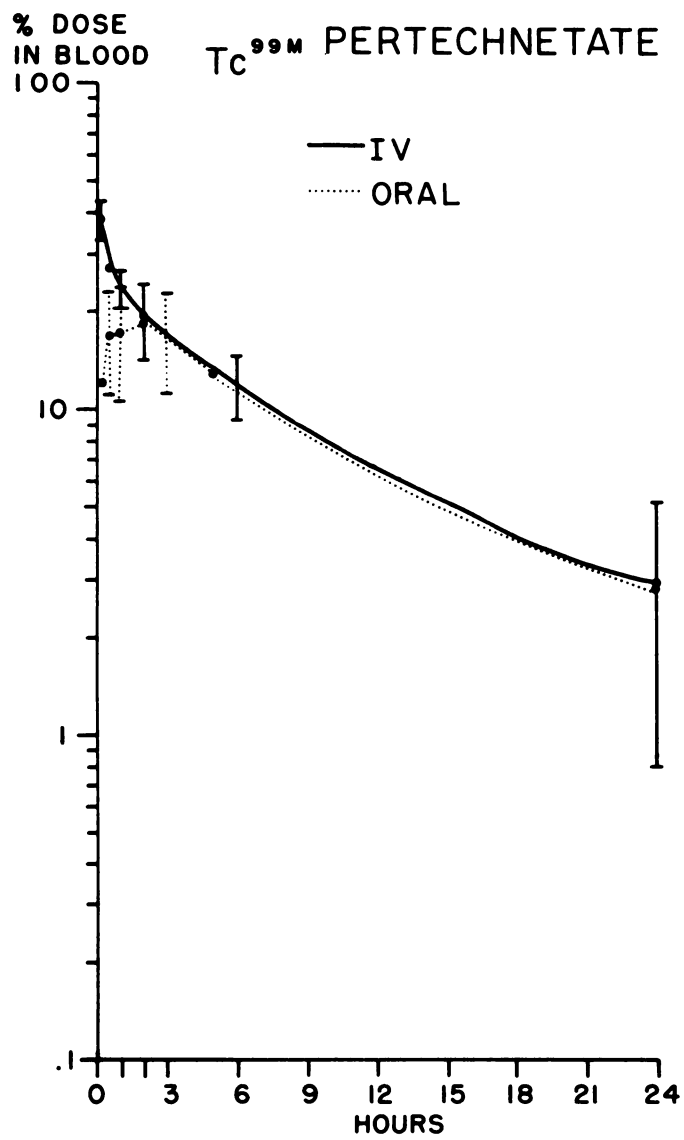
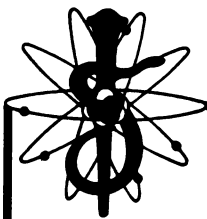
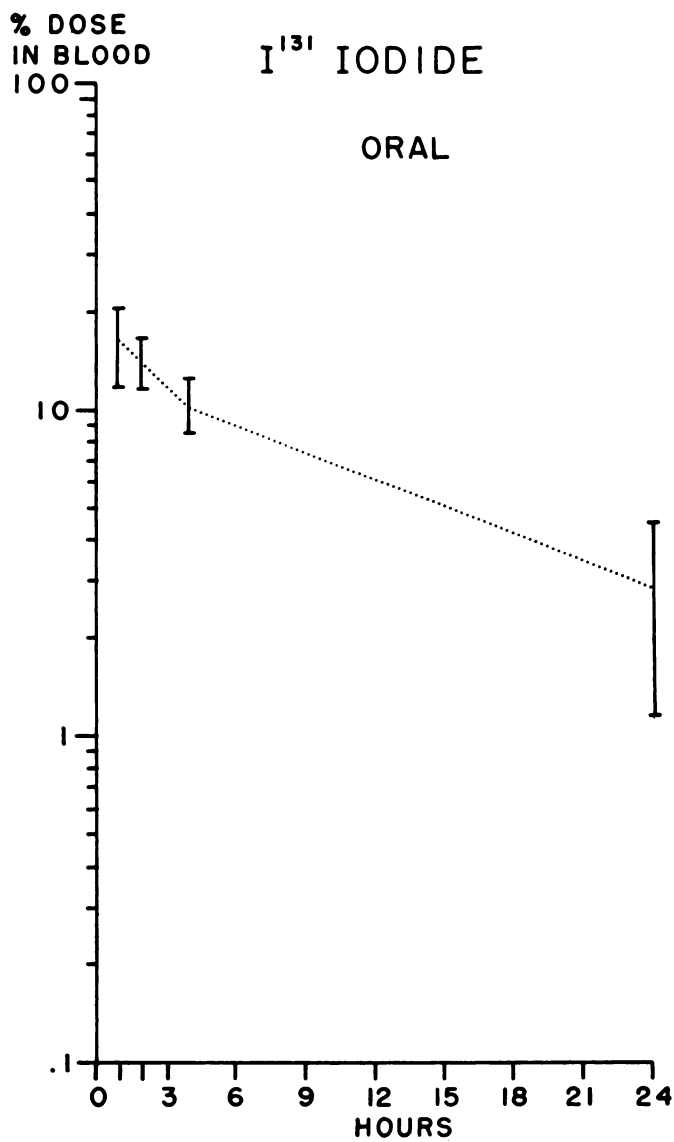
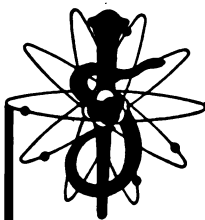


Fig. 3, A



B

**Fig. 3. Comparison of blood levels following administration (corrected for physical decay).
 (A)— Tc^{99m} pertechnetate, intravenously (10 patients) and orally (13 patients).
 (B)— I^{131} iodide orally (five subjects)
 Blood volumes were calculated as seven per cent of the total body weight. Mean values \pm one standard deviation.**



parallel chloride secretions. A fraction of the gastric and salivary secretion is reabsorbed in the small bowel, and subsequently excreted by the kidneys.

The thyroid uptake of this material is maximal one to two hours after administration. Three to four per cent of the administered dose is present within the gland at this time, as measured by external counting. The technetium is then released from the gland, unchanged, as pertechnetate and at 24 hours, the uptake level falls to approximately 0.5 per cent to one per cent of the dose (correcting for radioactive decay). Higher thyroid uptake levels occur at one to two hours in hyperthyroidism (10).

A comparison of the blood levels of radioactivity between intravenous and oral doses of labeled pertechnetate is shown in Fig. 3A (levels corrected for radioactive decay). After intravenous administration, the level falls rapidly at first, reaching half the 10 minute level in two hours. The subsequent biological half-times vary from five to seven hours. The first effective half-time in the bloodstream is therefore $1\frac{1}{2}$ hours, and the subsequent effective half-times about $3\frac{1}{2}$ hours. The fall in blood level after intravenous administration may be approximated by a power function only during the first three hours. After an oral dose of labeled pertechnetate in the fasting state, the maximal blood levels occur between one and three hours. The levels after the third hour are similar to those following an intravenous dose. Poor gastrointestinal absorption and resultant low blood levels have been observed in the postprandial state, in seriously ill patients, and in an estimated 10 per cent of normal individuals. If blood levels sufficiently high for brain scanning are not reached within one hour after an oral dose, they will not occur later. If aluminum oxide from the molybdenum generator is not removed by a cation exchange resin, it may adsorb the technetium and prevent satisfactory gastrointestinal absorption. In Fig. 3B, it is apparent that the blood levels following the oral administration of I^{131} iodide are similar to those of pertechnetate.

Of the total Tc^{99m} pertechnetate activity circulating in the bloodstream one hour after injection, an average of 30 per cent is contained in the red cell fraction and 70 per cent in the plasma. This relative plasma content, however, frequently varies from 40 to 85 per cent. The proportion of the radioactivity in the plasma compared to the red cell fraction tends to fall between one and 24 hours after administration. At 24 hours, 50 to 93 per cent of the total blood activity may be contained in the red cell fraction (average 24%). The pertechnetate is freely diffusible into and out of red blood cells, as demonstrated by serial washings in physiological saline. As measured by phosphotungstic acid precipitation, an average of 75 per cent of the plasma activity is protein bound. The pertechnetate is apparently not tightly bound to the protein, since only 25 to 35 per cent of the plasma activity will pass through anion exchange resins, and at least 40 per cent is dialyzable against distilled water. By descending paper chromatography in 85 per cent methanol, approximately two-thirds of the plasma radioactivity remains at the origin and hence is protein bound. Compared with other labeled substances which have been used for brain scanning (12), such as Hg^{203} chlormerodrin, both the level and degree of binding of pertechnetate to plasma proteins is relatively low.


The effective half-life of labeled pertechnetate was assessed in four individuals by external scintillation counting over various organs for 24 hours and correlated with the effective half-times determined from multiple blood samples. The results in two individuals for oral and intravenous administrations are illustrated in Figs. 4A and B, respectively. Regardless of the mode of administration, the highest counting rates are observed over the stomach and second highest rates over the liver. For both the liver and stomach, the first effective half-times are two hours and the subsequent half-times vary from five to seven hours. When these gastric counting rates are corrected for physical decay, the activity remains essentially constant after the first hour. Hence, there is an apparent equilibrium between the rate of gastric concentration of pertechnetate, and the passage of the gastric secretion into the small bowel.

A fraction of the gastrointestinal pertechnetate is reabsorbed, but a considerable fraction accumulates in the large bowel and is excreted in the feces. In this respect, it differs from iodide, which undergoes complete intestinal absorption. An abdominal scan three hours following the intravenous administration of Tc^{99m} pertechnetate (Fig. 2) reveals the high levels of radioactivity within the stomach and duodenal loop, and even higher levels within the splenic flexure and descending colon. The *in vivo* count rate over the thyroid gland closely follows that of the parotid glands (Fig. 4). The count rates over all other organs tend to merely reflect the levels of radioactivity in the bloodstream.

Following oral administration in nine subjects, the average urinary excretion was four per cent at three hours and 25 per cent at 24 hours, three per cent during the second 24 hours, and one per cent during the third 24 hour period (total 29 %). In 12 intravenous administrations, the average urinary excretion at three hours was 12 per cent; at 24 hours, 27 per cent; during the second 24 hours, four per cent; during the third 24 hour period, two per cent (total 33%). In different individuals, however, the urinary excretion varied from 15 to 50 per cent in the first 24 hours, and 15 to 58 per cent total for 72 hours. It would appear that the rate of urinary excretion of pertechnetate is a direct reflection of the plasma concentration.

The total fecal excretion over a three day interval was even more variable than urinary excretion. Although laxatives were given, not all of the radioactivity within the large bowel could be recovered for assay. The fecal excretion following intravenous injections varied from 10 to 45 per cent of the administered radioactivity. With an oral administration, 30 to 55 per cent of the administered activity was recovered in the stools. For the intravenous administration, the total radioactivity recovered in both urine and feces in three days averaged 50 per cent of the administered dose (range 28 to 68 %). In contrast, following oral administration, an average of approximately 70 per cent of the administered radioactivity was recovered in the stools and urine (range 39 to 88 %).

Duplicate studies in six volunteers indicated that the fraction of administered radioactivity excreted in the feces could not be reduced significantly by the oral administration of perchlorate along with the radioactive pertechnetate.



The influence of perchlorate on both fecal and urinary excretion, however, should be subjected to further study.

The possibility that pertechnetate may concentrate in the mucosa of the uterine cervix, similar to radioiodine (4) has not been investigated as yet.

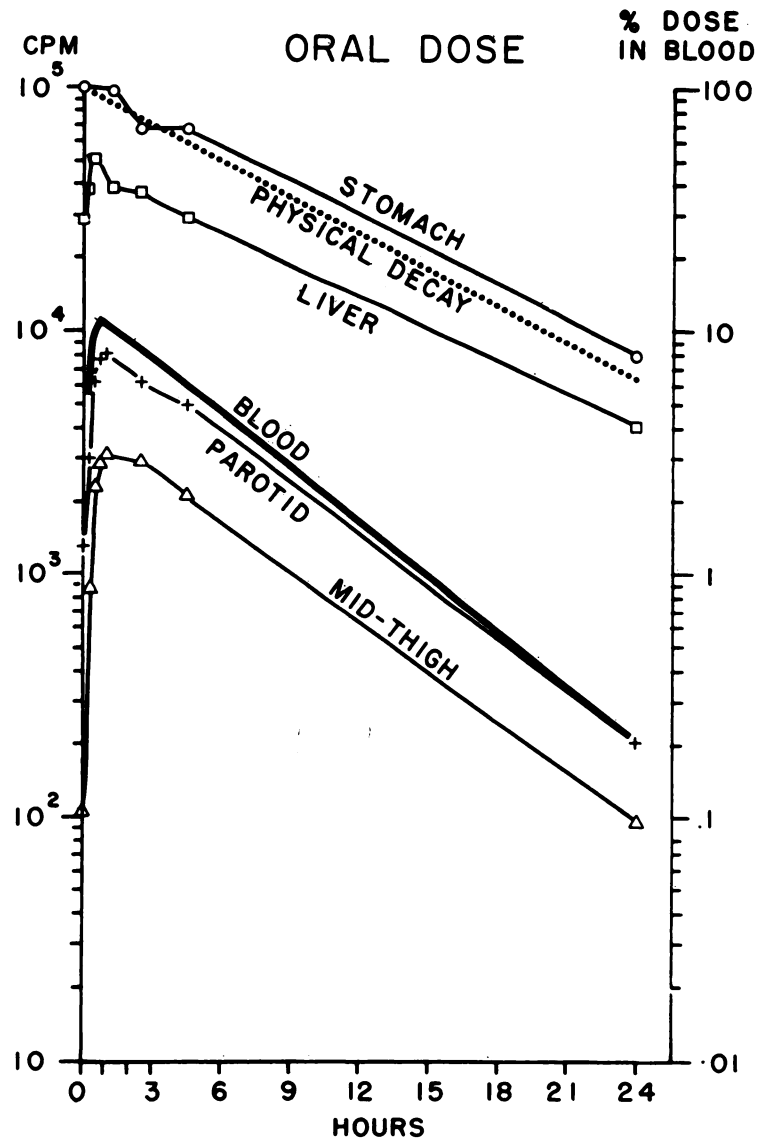


Fig. 4, A

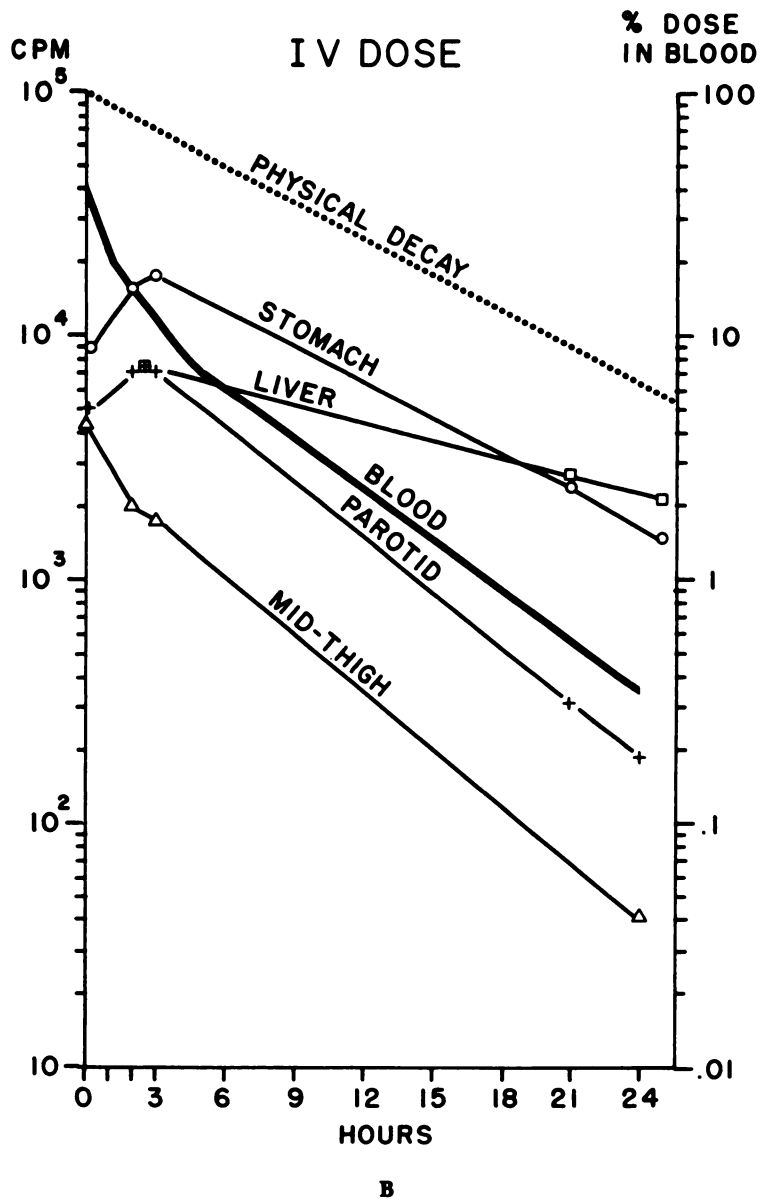
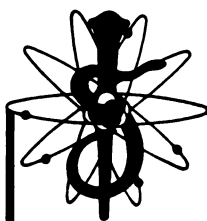


Fig. 4. Effective half-times of Tc^{99m} for (A) oral dose, vs (B) intravenous dose in two normal subjects, as determined by external scintillation counting and multiple blood samples.



BIOLOGICAL FATE OF Tc^{99m} PERTECHNETATE IN ANIMALS

In a metabolic study of Tc^{95} and Tc^{96} in rats (6), 73 per cent of the intramuscular dose was recovered in the urine and 15 per cent in the feces after one day. In another study (9), at 48 hours, 80 per cent was recovered in the urine and 12 per cent in the feces. From four to eight days, 98 per cent or more of the injected radioactivity could be accounted for in the urine and feces. At 48 hours, the highest concentration was found in the gastrointestinal tract, with lesser amounts in the skin, kidney and liver. At eight days, the only tissues containing measureable amounts of residual activity were the skin, kidney and liver. It is possible that the skin radioactivity, like that of radioiodide (4) is peculiar to rats and not present in other species.

In our laboratory, Tc^{99m} pertechnetate has been found less volatile than either radioiodine or radiomercury *in vitro*. In white mice, negligible amounts of injected radiotechnetium were lost in the expired air over a 24-hour period.

The organ with the highest level of pertechnetate in white mice was the stomach (10-12 % of the administered dose/1 % body weight). Ten per cent of the injected dose was found within the organ and its contents from one to three hours following intravenous injection, and 14 per cent at six hours. The fraction of the injected radioactivity in the small bowel increased from 2 to 6 per cent from 1 to 6 hours and in the large bowel, from 2 to 9 per cent. The administration of perchlorate decreased the gastric concentration of pertechnetate in the stomach and contents by a factor of four, but had little effect on the bowel content. It is likely that some secretion of pertechnetate occurs in the small bowel, analogous to iodide (4).

In 106 57C black mice with transplantable ependymomas, the tumor and tissue concentration levels were measured from one to 24 hours following intravenous injection or oral administration of Tc^{99m} pertechnetate. The tumor-to-brain concentration ratios were similar to those obtained previously with radiomercury-labeled chlormerodrin, but were not as high as for I^{131} labeled serum albumin. Thus, the tumor concentrations of radiopertechnetate range from 0.5 to 1 per cent of the dose/1 per cent body weight and the brain concentration 0.06 per cent at one hour, falling to 0.03 per cent at three hours. The tumor-to-brain concentration ratio for pertechnetate ranged from 15:1 to 29:1 (average 22:1). In comparison (12), the tumor concentrations of Hg^{203} chlormerodrin were 0.4 to 0.7 per cent of the dose/1 per cent body weight and the brain concentration 0.02 per cent; the tumor-to-brain concentration ratios of chlormerodrin ranged from 22:1 to 29:1. For pertechnetate, no significant difference in tumor-to-brain concentration was demonstrated between oral vs intravenous administration. Somewhat higher concentration ratios were obtained at three hours compared with one hour, because of the fall in brain concentration. Tc^{99m} in a reduced chemical state (probably TcO_3) has proven to be a good radioactive label for serum albumin (14). Tc^{99m} albumin, however, appeared to be completely unsatisfactory for brain tumor localization, because high tumor-to-brain ratios did not occur before physical decay.

RADIATION DOSIMETRY OF Tc^{99m} PERTECHNETATE

Tc^{99m} pertechnetate is one of the few radioisotopes used in medicine which is truly "carrier-free." Ten millicuries of this radionuclide represent just less than 10^{-11} grams of technetium; therefore, the possibility of chemical toxicity can be completely excluded. The only factors to be considered in the clinical use of Tc^{99m} are (1) radiation dosage and (2) pyrogen reactions. Because of the short physical half-life of six hours, it is not feasible to carry out routine pyrogen testing; therefore, the preparation of material for intravenous injection must be carried out with great care.

Tc^{99m} decays by isomeric transition to Tc^{99} , a pure beta emitter with a half-life of 2.1×10^5 years. When Tc^{99m} has decayed completely, 10 mc become only 0.5 pc Tc^{99} . Therefore, the contribution of Tc^{99} to the radiation dose may be completely ignored. In the following dosage considerations, it has been assumed that the contaminants, Mo^{99} , Ru^{103} , and I^{131} are present in negligible quantities.

The radiation dosage levels from Tc^{99m} pertechnetate orally and intravenously have been considered in detail by Smith (18). Using the biological excretion and distribution data described in the previous section, it has been calculated that the total body radiation dose from 10 mc Tc^{99m} in a 70 kg man is only 0.11 rads, (assuming a biological half-life of three days, I-gamma 0.56 r/mc/hr at 1 cm and E_{β} 14 kev). This compares favorably with a total body dose of approximately 0.4 rads for 375 μ c I^{131} albumin intravenously, and a total body dose of 0.18 rads for 750 μ c Hg^{203} chlormerodrin (15).


The radiation dose delivered to the thyroid (unblocked by Lugol's iodine or perchlorate) was estimated by Harper (10) to be one rad/10 mc Tc^{99m} pertechnetate. This dose was much less than the estimated 150 rads/100 μ c of I^{131} in the form of iodide (8).

The calculated radiation dose to the blood is no higher than the total body dose. For comparison, the dose delivered to the bloodstream from 375 μ c I^{131} albumin intravenously is approximately two rads.

Following intravenous injection of 10 mc Tc^{99m} pertechnetate, the estimated dose to the gastric mucosa is 0.4 rads (assuming 10% of the administered dose is concentrated in the stomach, and biological $T \frac{1}{2}$ = physical $T \frac{1}{2}$, g factor for stomach = 3). For an oral dose of similar activity in 250 cc of solution, an additional 0.4 rads for the direct irradiation of the gastric mucosa from the ingested material must be added (assuming a gastric emptying half-time of 30 minutes). The estimated total gastric dose from oral administration of 10 mc is therefore 0.8 rads. This compares favorably with a gastric dose of 2.1 rads for 100 μ c of I^{131} iodide (8).

The radiation dose to the liver from the same activity of Tc^{99m} pertechnetate is about 0.7 rads (assuming from animal data that 3.7% of the administered activity is contained in a 1,700 gm liver, g factor = 70, biological $T \frac{1}{2}$ = physical $T \frac{1}{2}$).

The "critical organ" which receives the highest radiation dosage from an administration of Tc^{99m} perchlorate is the large bowel, regardless of the mode of administration. Using a revised version of the ICRP model of the gastroin-



testinal tract (11), the mucosa of the large intestine receives an estimated 2.1 rads/10 mc orally (assuming 50% of the dose is excreted in the feces). For an intravenous dose of similar magnitude, the dose is probably one-half to two-thirds of the oral value, depending on the variable fractions of radioactivity excreted in the urine and feces. In the event that gastrointestinal absorption should completely fail to take place following an oral dose, the dose to the mucosa of the large bowel would become double the above value. This dosage received by the "critical organ" is small compared with the renal dose of 165 rads from 750 μc Hg^{203} chlormerodrin, or 13 rads from 750 μc Hg^{197} chlormerodrin (15).

The gonadal radiation dose for both males and females should ordinarily not exceed the total body dose. Using McIntyre's criteria (13) for maximum irradiation of the right ovary, the dose could attain a level as high as one rad if no absorption of pertechnetate occurred in the gastrointestinal tract after an oral administration, and if the entire gastrointestinal activity became concentrated in a single fecal bolus 3.7 cm away.

CONCLUSIONS

In a series of 133 patients $\text{Tc}^{99\text{m}}$ pertechnetate produced significantly better brain scans technically than the older agents I^{131} albumin or Hg^{203} chlormerodrin. Although clinical experience with this agent is still limited, it would appear that certain tumors frequently missed with older agents, such as low grade astrocytomas and suprasellar cysts, may be missed also with pertechnetate. The concentrations of this material in transplantable gliomas and normal brain tissues of mice were similar in magnitude to those obtained with the older agents.

The superiority of the labeled pertechnetate appeared to be due entirely to its physical characteristics, i.e. essentially monoenergetic gamma emissions of 140 kev, absence of beta emission, and short physical half-life of six hours. These characteristics permitted the administration of relatively large doses of 10 mc and a significant reduction in the procedure time; yet the radiation doses were kept below the levels obtained with other agents.

The radioactive preparation is easily obtained on a daily basis from a commercially available $\text{Mo}^{99}\text{-Tc}^{99\text{m}}$ generator. In this laboratory, the intravenous mode of administration is preferred over the oral, although both methods of administration have been tried. The intravenous method produces more consistent results, somewhat higher count rates with the same amounts of radioactivity administered, and slightly lower fractions of the administered radioactivity are excreted in the feces. The oral route, however, may be preferred at other institutions when immediate sterilization of the radioactive material cannot be carried out conveniently. By the oral route, satisfactory gastrointestinal absorption can be obtained in approximately 90 per cent of all patients. Furthermore, with oral administration, pyrogen-free reagents need not be used, and the volume of the eluate is not critical.

It is hoped that in the near future the use of this radionuclide can be further simplified by the development of an automatically timed elutor-titrator.

ACKNOWLEDGEMENT

The authors wish to acknowledge the technical assistance of Miss Ilse Zolle, Mrs. Julia Buchanan, and Mr. James Langan.

REFERENCES

1. ANDERS, E.: Radiochemistry of Technetium. Nuclear Science Series, National Academy of Science (NAS-NS 3021), Subcommittee on Radiochemistry, 1960. Available from Office of Technical Services, Dept. of Commerce, Washington 25, D. C.
2. BAUMANN, E. J.; SEARLE, N.; YALOW, A. A.; SIEGLE, E. AND SEIDLIN, S. M.: Filtration of seventh group elements by thyroid studied with radioactive isotopes. (abstract) *Int. Physiol. Congr.* 19:194, 1953.
3. Processed isotopes available from Brookhaven National Laboratory, Hot Laboratory Division, BNL, 1960; Revised Manual, 1964.
4. BROWN-GRANT, K.: Extrathyroidal iodide concentrating mechanisms. *Physiol. Rev.* 41:189, 1961.
5. COLTON, R. AND PEACOCK, R. D.: An outline of technetium chemistry. *Quarterly Reviews* 16:299, 1962.
6. DURBIN, P. W.; SCOTT, K. G. AND HAMILTON, J. G.: Distribution of radioisotopes of some heavy metals in rat. *Univ. Calif. Pub. Pharmacol.* 3:1, 1957.
7. GODLEY, A. F. AND STANBURY, J. B.: Preliminary experience in treatment of hyperthyroidism with potassium perchlorate. *J. Clin. Endocrinol.* 14:70, 1954.
8. HALNAN, K. E.: Metabolism of biologically important radionuclides. V. Metabolism of radioiodine and radiation dosage in man. *Brit. J. Radiol.* 37:101, 1964.
9. HAMILTON, J. G.: Univer. of Cal. Radiation Laboratory Medical and Health Physics Quarterly Report. UCRL-98, 1948.
10. HARPER, P. B.; BECK, R.; CHARLESTON, D. AND LATHROP, K. A.: Optimization of a scanning method using Tc^{99m} . *Nucleonics* 22:50, January, 1964.
11. HAYES, R. L.; CARLTON, J. E. AND BUTLER, W. R., JR.: Radiation dose to human intestinal tract from internal emitters. *Health Physics* 9:915, 1963.
12. LONG, R. G.; MCAFEE, J. G. AND WINKELMAN, J.: Evaluation of radioactive compounds for external detection of cerebral tumors. *Cancer Research* 23:98, 1963.
13. MACINTYRE, W. J.; CRESPO, G. G. AND CHRISTIE, J. H.: Use of radioiodinated (I-131) iodipamide for cardiovascular scanning. *Am. J. Roent.* 89:315, 1963.
14. MCAFEE, J. G.; STERN, H. S.; FUEGER, G. F. AND HOLTZMAN, G. B.: Tc^{99m} labelled serum albumin for scintillation scanning of placenta and other vascular structures. (In preparation)
15. MCAFEE, J. G. AND FUEGER, G. F.: Value and limitations of scintillation scanning in diagnosis of intracranial tumors. "Scintillation Scanning in Clinical Medicine," edited by Quinn, J. L., III, W. B. Saunders Co., Philadelphia, 1964.
16. MEALEY, J.; DEHNER, J. R. AND REESE, I. C.: Clinical comparison of two agents used in brain scanning. *JAMA* 189:260, 1964.
17. SMITH, E. M.: Properties, uses, radiochemical purity and calibration of Tc^{99m} . To be published, *J. Nuc. Med.*
18. SMITH, E. M.: Dosimetry of Tc^{99m} . In preparation.
19. SORENSEN, L. B. AND ARCHAMBAULT, M.: Visualization of liver by scanning with Mo^{99} (Molybdate) as tracer. *J. Lab. & Clin. Med.* 62:330, 1963.
20. SORENSEN, L. B. AND ARCHAMBAULT, M.: Preliminary physiological studies of molybdenum (Mo^{99}) in liver scanning. *Radiology* 82, 2:318, February, 1964.