

Pulmonary Gallium-67 Uptake in Amiodarone Pneumonitis

W. J. van Rooij, S. C. van der Meer, E. A. van Royen, N. van Zandwijk, and J. I. Darmanata

Academic Medical Centre, Amsterdam, Netherlands

Three patients are presented suffering from interstitial pneumonitis caused by amiodarone. Pulmonary Ga-67 uptake occurred in all three. There appeared to be a discrepancy between the scintigraphic and radiographic findings in two patients. Gallium-67 lung scintigraphy may offer an early, sensitive indicator for amiodarone pneumonitis.

J Nucl Med 25: 211–213, 1984

Amiodarone hydrochloride is widely used in Europe for the treatment of ventricular or supraventricular arrhythmias and angina pectoris. In the United States, it is currently undergoing clinical trials. Several side effects of this benzofuran derivative have been described, e.g., bluish skin discoloration, corneal microdeposits, both hypo- and hyperthyroidism, and bone-marrow depression (1–4).

Recently a number of articles have been published describing patients suffering from interstitial pneumonitis probably induced by amiodarone therapy (3–6). Gallium-67 accumulation has been described in various forms of pneumonitis induced by drugs such as nitrofurantoin (7) and bleomycin (8). We describe here three cases of amiodarone-induced pneumonitis in which abnormal pulmonary Ga-67 uptake was demonstrated.

METHODS

Scintigraphy was performed 48 hr after intravenous injection of 2 mCi of Ga-67 citrate (with 20% window settings on the photopeaks at 93, 184, and 296 keV). Anterior and posterior views of the chest were obtained. From computer stored data, Ga-67 accumulation was quantified around hili and lungs (9) and counts per pixel per min per mCi were obtained.

CASE REPORTS

Case 1. A 59-yr-old man with Wolff-Parkinson-White syndrome and tachycardia had been treated with amiodarone since March 1978. One year later he presented with progressive dyspnea and persistent cough. In the right lung a chest radiograph demonstrated two areas with an interstitial reticular pattern. Perfusion lung scintigraphy was normal, but a Ga-67 study showed an area of increased uptake in the right lung at the level of the hilus (Fig. 1a). Since no basis was found for the interstitial lung changes, an adverse reaction to amiodarone was considered and the drug was discontinued. Within a few weeks his symptoms regressed; the

chest radiograph showed considerable improvement, and no Ga-67 uptake in the right lung was observed. To confirm the diagnosis of amiodarone pneumonitis, the patient was rechallenged with the drug and in 7 wk the identical complaints returned. Although the chest radiograph remained unchanged, the Ga-67 images now revealed an area of increased uptake in the left lung (Fig. 1b). After discontinuation of the drug again, regression of symptoms occurred and the Ga-67 lung images were essentially normal (Fig. 1c).

Case 2. A 56-yr-old man was treated with amiodarone for persistent angina pectoris after myocardial infarction and coronary by-pass surgery. After 9 wk of therapy he developed dyspnea, cough, and subfebrile temperature. Chest radiograph showed areas with a "ground glass" pattern bilaterally, and scattered sites of segmental collapse predominantly in the lower lung fields. Amiodarone pneumonitis was suspected. The Ga-67 lung images showed a diffuse increase in Ga-67 uptake (Fig. 2a). Quantitative values of lung and hilar uptake were found well above twice the normal range (Table 1). Amiodarone was discontinued, and although his chest radiograph improved, his clinical condition did not. Repeated Ga-67 lung scintigraphy showed a shift of the radioactivity to the upper lung fields. Because of the severe dyspnea, corticosteroid therapy was started (prednisolone 40 mg daily) and he improved markedly. After 3 wk of therapy, Ga-67 images and radiographs of the chest were normal (Fig. 2b, Table 1). Corticosteroid therapy was reduced gradually, but when the dose was lowered to 30 mg daily, symptoms of dyspnea recurred. Again Ga-67 scintigraphy revealed uptake in both lungs, but the chest radiograph remained normal (Fig. 2c, Table 1).

Case 3. A 69-yr-old man was treated with amiodarone for persistent angina following two myocardial infarctions. After 2 yr on amiodarone therapy he presented with progressive dyspnea and general malaise of several months' duration. The chest radiograph showed a diffuse fine interstitial pattern in the right lower lobe, and amiodarone pneumonitis was suspected. The Ga-67 lung study showed a diffuse, slightly increased uptake (mean activity 18 cpm/pixel/mCi) with a focus of marked activity in the right lower lobe (Fig. 3a). When the amiodarone was withdrawn, his clinical condition improved, and the chest radiograph showed regression. Three months later a Ga-67 lung study was normal (apart from some residual activity at the right base), as were the quantitative values (Fig. 3b).

Received Apr. 29, 1983; revision accepted Sept. 22, 1983.

For reprints contact: E. A. van Royen, MD, Dept. of Nuclear Medicine, Academic Medical Centre, Meibergdreef 9, 1105 AZ Amsterdam.

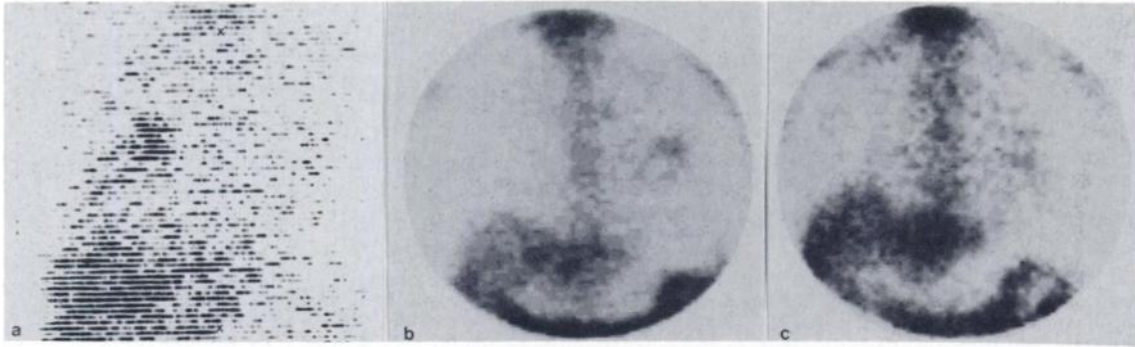


FIG. 1. Case 1: Ga-67 lung scintigrams, (anterior view): (a) focus in R lung while on amiodarone treatment; (b) focus in L lung after re-challenging with amiodarone; (c) almost complete disappearance of L focus after subsequent withdrawal.

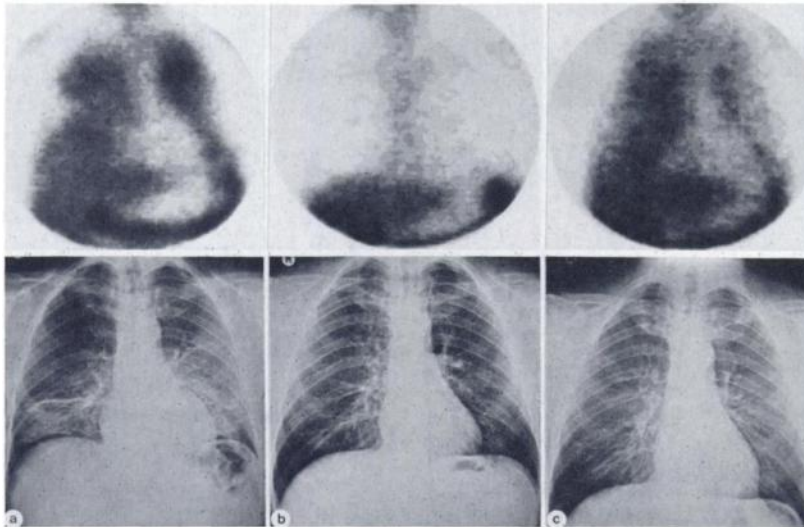


FIG. 2. Case 2: Anterior Ga-67 lung scintigrams (above) and chest radiographs (below): (a) intense diffuse Ga-67 activity on amiodarone treatment; radiographs shows ground-glass pattern and segmental collapse in both lungs; (b) after instigation of prednisolone treatment (40 mg daily), Ga-67 image and radiographs become normal; (c) after reduction of prednisolone dosage, Ga-67 uptake is intense, but radiograph is unchanged.

DISCUSSION

Gallium-67 is accumulated in the chest in malignancies and in inflammatory processes of various kinds. Sarcoidosis is one of the best-known examples of pathological Ga-67 uptake in interstitial lung diseases. In this condition the quantitative Ga-67 uptake is

considered an indicator of the extent of the disease (10-12).

Our three patients suffering from amiodarone pneumonitis all had pathological pulmonary Ga-67 uptake. A different type of reaction was observed between Patients A and C on the one hand, and Patient B on the other. Whereas Patients A and C showed focal lung changes and Ga-67 uptake after prolonged (months) exposure to amiodarone, a massive reaction and diffuse uptake

Days after withdrawal of amiodarone:	3	17	34	110	
Prednisolone (mg/day):	0	0	40	30	
Left lung	34	29	14	19	(15)
Right lung	37	33	15	19	(17)
Left hilus	33	28	17	23	(18)
Right hilus	39	43	16	26	(19)

* In cpm/pixel per mCi dose, means of anterior and posterior views. Parentheses show normal mean values (Ref. 9).

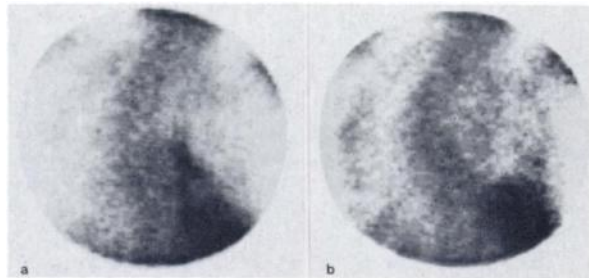


FIG. 3. Case 3: Posterior Ga-67 lung scintigram (note marked scoliosis); (a) intense Ga-67 activity in R lower field above liver while on amiodarone; quantitative uptake elsewhere in lungs slightly increased; (b) disappearance of lesion after withdrawal, with some residual activity at right base; normalization of quantitative values in rest of lungs.

occurred in Patient B relatively shortly after institution of the amiodarone therapy. In the last case discontinuation did not result in an improvement, and prolonged corticosteroid therapy was necessary to induce normalization. A minor reduction of the dose after 3 mo caused a rapid reappearance of abnormal Ga-67 uptake. Amiodarone is accumulated in body tissues and released with an extremely long half-time of about 28 days. Therefore, the immediate recurrence of activity of the disease in Patient B might have been related to high levels of the drug still present.

Nevertheless, it remains a puzzling finding that discontinuation in Patients A and C did cause an immediate improvement while large amounts of amiodarone must also have been present in these patients. This indicates considerable variation of the clinical picture among patients. Similar acute and chronic types of reaction have also been described for nitrofurantoin-induced lung disease (7). A striking discrepancy between radiographic and scintigraphic findings was noticed. Increased Ga-67 uptake could be demonstrated in radiographically normal areas and vice versa in patients A and B. The sensitivity of the Ga-67 image in comparison with the radiographs was not noticeable in Patient B: recurrence of clinical symptoms after lowering of corticosteroid therapy was accompanied by recurrence of intense Ga-67 uptake, whereas chest radiographs remained unchanged. This absence of correlation between radiographic findings and the clinical condition of the patient has also been observed in bleomycin-induced pulmonary disease (8).

Determination of quantitative uptake was especially helpful in Patients B and C. In Patient B corticosteroid therapy could be guided by the intensity of the uptake, whereas in Patient C the subtle, diffusely increased lung activity was apparent only after quantitative analysis.

In our opinion, patients on amiodarone treatment who develop pulmonary dyspnea should receive both chest radiographs and Ga-67 lung scintigraphy in view of the observed discrepancies. Obviously other possible causes of Ga-67 accumulation should not be disregarded since our finding is not specific for amiodarone pneumonitis.

ACKNOWLEDGMENTS

We are indebted to Prof. D. Westra, Department of Radiology, for his critical evaluation of the radiographs; to Mrs. E. Busemann-Sokole for her review of the manuscript, and to Mr. C. M. van Hunnik for the photographic reproductions.

REFERENCES

1. VOS AK, VAN RAMSHORST AGS, CROSFELD JCM, et al: A peculiar cutaneous pigmentation from cordarone. *Dermatologica* 145:297-303, 1972
2. BURGER A, DINICHERT D, NICOD P, et al: Effects of amiodarone on serum triiodothyronine, reverse triiodothyronine, thyroxin and thyrotropin; a drug influencing peripheral metabolism of thyroid hormones. *J Clin Invest* 58:255-259, 1976
3. WRIGHT AJ, BRACKENRIDGE RG: Pulmonary infiltration and bone marrow depression complicating treatment with amiodarone. *Br Med J* 284:1303, 1982
4. HEGER JJ, PRYSTOWSKY EN, JACKMAN WM, et al: Amiodarone, clinical efficacy and electrophysiology during long-term therapy for recurrent ventricular tachycardia or ventricular fibrillation. *N Engl J Med* 305:539-545, 1981
5. ROTMENSCH HH, LIRON M, TUPILSKI M, et al: Possible association of pneumonitis with amiodarone therapy. *Am Heart J* 100:412-413, 1980
6. VAN ZANDWIJK N, DARMANATA JI, DÜREN DR, et al: Amiodarone pneumonitis. *Eur J Respir Dis* 64:313-317, 1983
7. ROSENOW EC: The spectrum of drug-induced pulmonary disease. *Ann Int Med* 77:977-999, 1972
8. RICHMAN SD, LEVENSON SM, BUNN PA, et al: ⁶⁷Ga accumulation in pulmonary lesions associated with bleomycin toxicity. *Cancer* 36:1966-1972, 1975
9. VAN UNNIK JG, VAN ROYEN EA, ALBERTS C, et al: A method of quantitative ⁶⁷Ga scintigraphy in the evaluation of pulmonary sarcoidosis. *Eur J Nucl Med* 8:351-353, 1983
10. ALBERTS C, VAN DER SCHOOT JB, GROEN AS: Ga-67 scintigraphy as an index of disease activity in pulmonary sarcoidosis. *Eur J Nucl Med* 6:205-212, 1981
11. LINE BR, HUNNINGHAKE GW, KEOGH BA, et al: Gallium-67 scanning to stage the alveolitis of sarcoidosis: Correlation with clinical studies, pulmonary function studies and bronchoalveolar lavage. *Am Rev Resp Dis* 123:440-446, 1981
12. ALBERTS C, VAN DER SCHOOT JB, VAN DAATSelaar JJ, et al: ⁶⁷Ga scintigraphy, serum lysozyme and angiotensin-converting enzyme in pulmonary sarcoidosis. *Eur J Resp Dis* 64:38-46, 1983

Eastern Great Lakes Chapter Society of Nuclear Medicine Annual Meeting

May 4-5, 1984

Niagara Falls

Niagara Falls, New York

The Annual Meeting of the Eastern Great Lakes Chapter of the Society of Nuclear Medicine will be held May 4-5, 1984 in the Niagara Hilton at Niagara Falls, New York. The program will include submitted papers, invited presentations, and exhibits.

The Scientific Program Committee invites submission of abstracts from members and nonmembers of the Society of work to be considered for presentation at the meeting.

The program has been approved for 10 hours of AMA Category 1 credit. VOICE credits will be available for technologists.

Requests for further information and/or abstracts of 300 words or less should be submitted before March 31, 1984 to: A.A. Driedger, M.D., Ph.D., Dept. of Nuclear Medicine, Victoria Hospital, 375 South Street, London, Ontario, N6A 4G5; (519)432-5241, ext. 529.