

Pelvic Extramedullary Hematopoiesis

Jeno I. Sebes, James D. Massie, Thomas J. White III, and Alfred P. Kraus

University of Tennessee Center for the Health Sciences, Memphis, Tennessee

Extramedullary hematopoiesis is an infrequent cause of thoracic masses. Extrathoracic locations are even less common. We have studied two patients, one with suspected pelvic neoplasm, with technetium-99m sulfur colloid marrow image and transmission computerized tomography. This noninvasive evaluation established the diagnosis of pelvic extramedullary hematopoiesis in both. We recommend a similar diagnostic approach in patients with chronic anemia or other predisposing disease, presenting with a pelvic or abdominal mass.

J Nucl Med 25: 209-210, 1984

Extramedullary hematopoiesis (EMH), a well-recognized response to compensate for insufficient red-cell formation, results in expansion of hematopoietic mass. While EMH is occasionally found in chronic anemia (1) it is also described in lymphoma, Hodgkin's disease, leukemia, myelofibrosis, and disseminated carcinoma (2). The most common and easily detectable site of extramedullary hematopoiesis is the posterior mediastinum. Liver and spleen are less commonly involved. It has also been found in lymph nodes, thymus, thyroid, lung, pleura, renal hilum, appendix, retroperitoneal space, dura mater, and falx cerebri (1). In 1945, Ask-Upmark (3) reviewed three cases in which pelvic EMH simulated neoplasm between the sacrum and rectum. Two were found at autopsy and one at surgery. Since then, there have been no reported cases of pelvic EMH. During the last 6 mos, we have encountered two patients, one homozygous for sickle cell anemia and one with thalassemia intermedia, both having pelvic extramedullary hematopoiesis. In addition to routine radiographic evaluation, both were studied by radionuclide bone-marrow imaging and transmission computerized tomography (TCT).

CASE REPORTS

Case 1. A 46-yr-old woman with the diagnosis of sickle cell anemia since age 17 yr, was admitted with dyspnea and draining leg ulcers. Though anemic since childhood, she had not required transfusions. Since the age of 9 yr, she had been treated for recurrent leg ulcers, and was repeatedly hospitalized for sickle cell cardiomyopathy. Following diagnosis of hemolytic streptococcal gangrene of the left leg, a fasciotomy was performed. Radiographs of the chest showed cardiomegaly with changes of congestive heart failure, and two distinct bilateral posterior mediastinal masses. A Tc-99m sulfur colloid marrow image showed increased radionuclide uptake in the area of the posterior mediastinal mass, but unexpectedly there was a large area of similar uptake in the presacral region, extending somewhat to the left of the midline

(Fig. 1). A TCT image showed a 4 × 6 × 6 cm pelvic mass in the same area, consistent with EMH (Fig. 1, lower right).

Case 2. A 35-yr-old black woman with previously diagnosed thalassemia intermedia presented to the gynecologic service with a pelvic mass. She had had three previous aborted pregnancies and had been hospitalized twice for high-output cardiac failure. A pelvic mass displacing the rectum anteriorly was shown by excretory urogram and barium enema. A Tc-99m sulfur colloid marrow study showed striking uptake in the pelvic mass (Fig. 2) and bilateral lobulated peravertebral chest masses. Transmission computerized tomographic examination confirmed the pelvic and mediastinal masses with density of 55 HU. In spite of the radiologic diagnosis of extramedullary hematopoiesis, a laparotomy was performed and a firm, red pelvic mass measuring 7 × 5 × 4 cm was found and biopsied. Pathology confirmed EMH.

DISCUSSION

The pathogenesis of EMH is still debated. Ask-Upmark first described heterotopic erythropoietic marrow tissue in intercostal veins found at autopsy, and suggested an embolic or metastatic origin (3). He suggested that posterior mediastinal EMH resulted from venous stasis aided by negative intrathoracic pressure. Proponents of this "marrow embolization" theory (2,3) cite tomographic evidence of clear separation of the masses from adjacent vertebrae and ribs. Later reports suggest that thoracic masses are extruded from the bone marrow of ribs and vertebral bodies through areas of bone lysis because of increased medullary marrow pressure (4). Recent TCT investigations of thoracic EMH demonstrated actual herniation or extrusion of marrow from these sites, supporting the "extrusion" theory (4,5). On the other hand, Shaver and Clore (6) did not find TCT evidence of bone erosions in their cases of posterior mediastinal EMH. Neither of our cases demonstrates strong evidence for this theory either, since no structural changes were observed in the vertebral bodies or the sacrum. The role of negative intrathoracic pressure in the production of mediastinal EMH is doubtful. Certainly in the pelvis, negative pressure is not involved in production of EMH, since intraabdominal and pelvic pressures are positive.

Received June 8, 1983; revision accepted Sept. 7, 1983.

For reprints contact: J. I. Sebes, MD, Dept. of Radiology, UTCHS, 865 Jefferson Ave., Memphis, TN 38163.

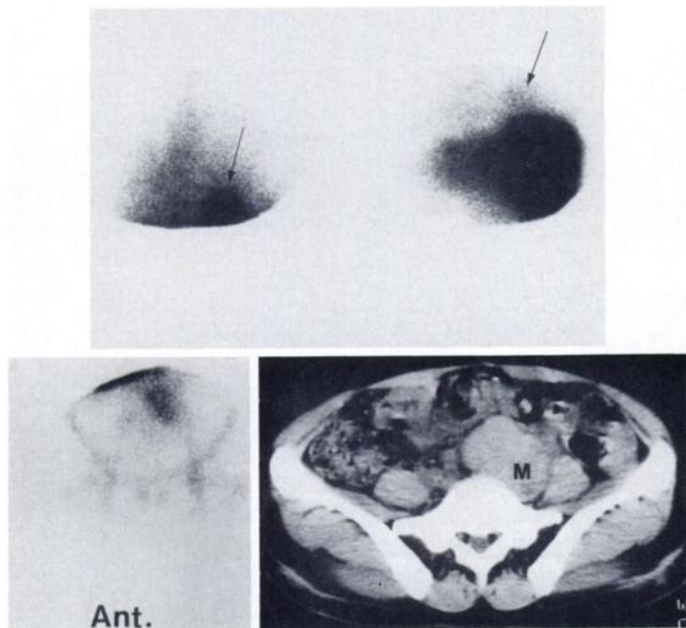


FIG. 1. Posterior Tc-99m SC image at lung base with (left) and without (right) liver excluded (upper). Both images demonstrate abnormal focus of sulfur colloid uptake at site of thoracic EMH (arrows). Anterior pelvic Tc-99m SC image (lower left). Uptake of radionuclide by pelvic mass. TCT image (lower right). Large presacral mass (M) extending somewhat to left of midline.

Several agents—including iron-52, iron-59, indium-111 trichloride, and technetium-99m sulfur colloid (Tc-99m SC)—may be used for radionuclide marrow imaging (7,8). Of these, however, Tc-99m SC is the most convenient to use and most satisfactorily imaged. Tc-99m SC, trapped by the RE cells rather than the erythropoietic cells, has been used to image sites of EMH (7,8). Such a technique is possible because in the normal and many pathologic states, distribution of RE cells and erythropoietic sites is quite similar (9). Known exceptions include aplastic anemia and postirradiation states (8). Therefore, both sites of skeletal marrow hematopoiesis and EMH may be detected with Tc-99m SC marrow imaging.

It is important to recognize that EMH may occur in the pelvis. This diagnosis should be suspected in patients with predisposing disease or evidence of mediastinal EMH, who have pelvic or retroperitoneal masses. In this clinical setting, marrow images may allow a specific diagnosis of pelvic EMH.

One may be confident that extraskelatal foci of Tc-99m SC uptake indicate hematopoietic sites accompanied by RE cells. A conceivable pitfall might be the rare pelvic or accessory spleen, which would be expected to accumulate Tc-99m SC as well. Splenic tissue could easily be identified with Tc-99m-labeled red blood cell imaging. Either entity, of course, requires no intervention. However, since Harnsberger (9) reported a single case of abdominal EMH that failed to take up either Tc-99m SC or indium-111 chloride, TCT studies can be helpful. Because TCT numbers (HU units) 35-70 usually represent iron, such values indicate the presence of blood products (10).

ACKNOWLEDGMENT

This work was supported in part by U.S. Public Health Service Grant HL15169.

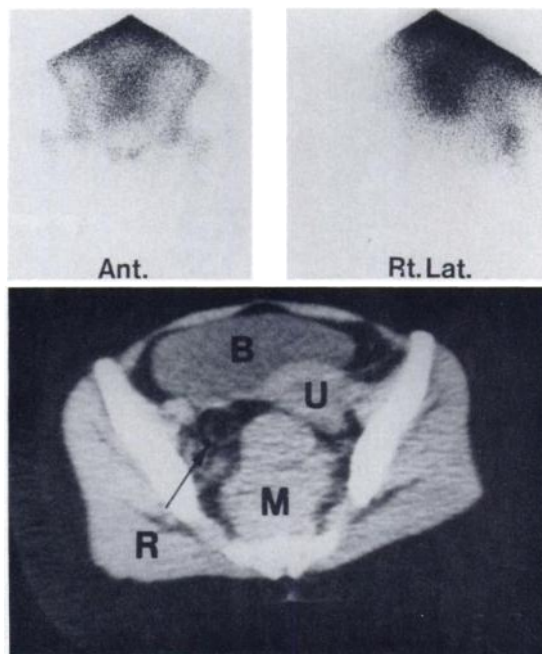


FIG. 2. Left anterior and right lateral Tc-99m SC pelvic images (upper). Large pelvic mass showing marked radionuclide uptake inferior focus of activity on right lateral view is greater trochanter of right femur. Liver and spleen are partially shielded. Pelvic TCT image (lower). Large lobulated presacral mass (M) displacing rectum (arrow) anteriorly and laterally. Uterus (U) is to right of midline between urinary bladder (B) and mass (M).

REFERENCES

1. SEIDLER RC, BECKER JA: Intrathoracic extramedullary hematopoiesis. *Radiology* 83:1057-1059, 1964
2. PAPAVALIOU CG: Intrathoracic marrow heterotopia presenting as tumor-like masses. A new radiological entity. New York Excerpta Medica Foundation. 1967, 603-608
3. ASK-UPMARK E: Tumors simulating intrathoracic heterotopia of bone marrow. *Acta Radiol* 26:425-440, 1945
4. LAWSON JP, ABLOW RC, PEARSON HA: The ribs in thalassemia. II. The pathogenesis of the changes. *Radiology* 140:673-679, 1981
5. LONG JA, DOPPMAN JL, NIENHUIS AW: Computed tomographic studies of thoracic extramedullary hematopoiesis. *J Comput Assist Tomogr* 4:67-70, 1980
6. SHAVER RW, CLORE FC: Extramedullary hematopoiesis in myeloid metaplasia. *Am J Roentgenol* 137:874-876, 1981
7. STEBNER FC, BISHOP CR: Bone marrow scan and radioiron uptake of an intrathoracic mass. *Clin Nucl Med* 7:86-87, 1982
8. BROWN JL, PAQUALET JR, TETALMAN MR: Intrathoracic extramedullary hematopoiesis. Appearance of ^{99m}Tc sulfur colloid marrow scan. *Am J Roentgenol* 134:1254-1255, 1980
9. HARNBERGER HR, DATZ FL, KNOCHEL JQ, et al: Failure to detect extramedullary hematopoiesis during bone-marrow imaging with indium-111 or technetium-99m sulfur colloid. *J Nucl Med* 23:589-591, 1982
10. LEE JK, SAGEL SS, STANLEY RJ: *Computed Body Tomography*. New York, Raven Press, 1983, p 189