

38. BRONSTEIN BR, STEELE GD, JR, ENSMINGER W, et al: The use and limitations of serial plasma carcinoembryonic antigen (CEA) levels as a monitor of changing metastatic liver tumor volume in patients receiving chemotherapy. *Cancer* 46:266-272, 1980
39. KLEE GG, GO VLW: Serum tumor markers. *Mayo Clin Proc* 57:129-132, 1982
40. BRAUNSTEIN GD, VAITUKAITIS JL, CARBONE PP, et al: Ectopic production of human chorionic gonadotrophin by neoplasms. *Ann Int Med* 78:39-45, 1973
41. WU S-Y, GREEN WL: Triiodothyronine (T₃)-binding immunoglobulins in a euthyroid woman: effects on measurement of T₃ (RIA) and on T₃ turnover. *J Clin Endocrinol Metab* 42:642-652, 1976

Intraoperative Scintigraphic Localization of a Gastrointestinal Bleeding Site

Christopher J. Palestro, Kodendera S. DuLeep, Alan H. Richman, and Carl J. Collica

Norwalk Hospital, Norwalk, Connecticut

We present a case report of intraoperative scintigraphic localization of an active gastrointestinal bleeding site in a 65-yr-old female who had repeatedly negative endoscopy and angiography.

J Nucl Med 25: 1209-1211, 1984

Gastrointestinal bleeding, even when clinically massive, generally occurs intermittently (1); in order for invasive procedures, such as endoscopy and angiography to be successful, the patient must be actively bleeding at the time of the study. Recently, scintigraphy of gastrointestinal bleeding with Tc-99m sulfur colloid or Tc-99m-tagged red cells has proven to be an accurate and effective method for the detection and localization of upper and lower gastrointestinal bleeding (2,3). We present a case report of intraoperative scintigraphic location of an active GI bleeding site.

CASE REPORT

A 65-yr-old female, with a 3-wk history of melena and a hemoglobin of 4.5 g, received seven units of packed red blood cells and one unit of fresh-frozen plasma; however, her hemoglobin and hematocrit continued to drop slowly and her stools remained heme-positive. A barium enema and upper GI series were unremarkable. Endoscopy demonstrated a duodenal ulcer but no discrete bleeding site. A tagged-red-cell study was performed (4) but no evidence of active bleeding was noted on the first day of the study. On the following day the study was repeated, and a focus of radioactivity was observed in the left upper quadrant of the abdomen (Fig. 1). Sequential imaging over the next 4 hr showed movement of the radionuclide into the right lower quadrant (Fig. 2), indicating that the bleeding originated in the small bowel and not in the colon. Celiac, superior mesenteric, and inferior mesenteric arteriography were found normal. An exploratory laparotomy was not revealing. Multiple enterotomies and intraoperative en-

doscopies were performed, extending from the ligament of Treitz to the ileocecal valve, but no bleeding site was found. The patient was stable for approximately 48 hr following surgery but then began passing tarry stools; her hemoglobin dropped from 10 to 8 g. The tagged-RBC study was repeated and was virtually identical to the initial study, again demonstrating active intermittent bleeding in the left upper quadrant, presumably in mid jejunum. Repeat arteriograms and upper endoscopy to the ligament of Treitz were negative.

At a second operation, an attempt was made scintigraphically to locate the bleeding site more precisely with an uncollimated

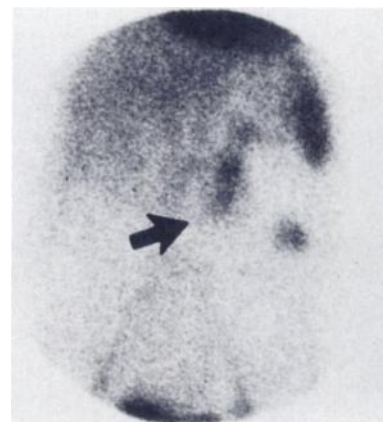

FIG. 1. Anterior image of abdomen showing abnormal radionuclide accumulation in left upper quadrant. Note anteriorly displaced left kidney (arrow) medial to bleeding site. LPO image confirmed location of left kidney, which was displaced by large photon-deficient region confirmed on angiography to be cyst.

Received Mar. 16, 1984; revision accepted June 1, 1984.

For reprints contact: Christopher J. Palestro, MD, Section of Nuclear Medicine, Norwalk Hospital, Norwalk, CT 06856.

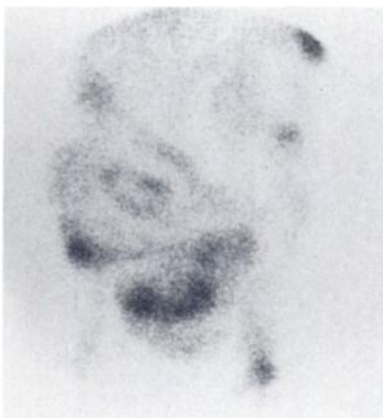


FIG. 2. Anterior image of abdomen performed 4 hr after image in Fig. 1. Note small-bowel radioactivity in right lower quadrant.

Geiger-Müller probe, but no discrete focus of significantly elevated radioactivity could be discerned. During surgery as much of the small bowel as possible was imaged sequentially with a portable

gamma camera. The most intense tracer concentration was found in the proximal 50 cm of small bowel, with a discrete focus of radioactivity approximately 10 cm distal to the ligament of Treitz (Fig. 3) and only minimal activity remained near the ileocecal valve (Fig. 4). The first 50 cm of small bowel distal to the ligament of Treitz was resected. Examination revealed extensive blood clots and three submucosal hemorrhagic foci, each ~1 mm in diameter, four cm proximal to the most intense focus of radioactivity. The microulcerations were felt by the pathologist to be the cause of the patient's GI bleeding, although their cause could not be ascertained. The patient had an uneventful recovery, was discharged approximately 1 wk later, and has remained stable over the past 4 mo.

DISCUSSION

The search for a bleeding site in the gastrointestinal tract can be an arduous task. Angiography can identify areas of gastrointestinal bleeding only when hemorrhage is actively occurring at greater than 1 ml per minute (5-7). Tc-99m RBC imaging offers a prolonged opportunity (up to 24 hr) to monitor patients with gastrointestinal bleeding, and bleeding sites of as little as 5 ml have

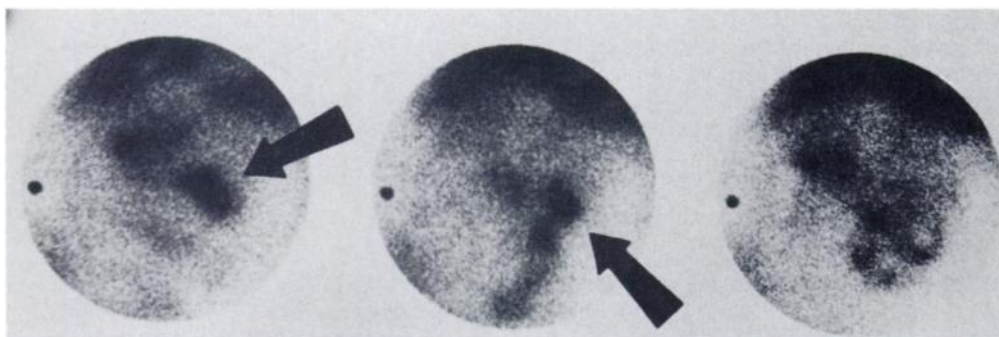


FIG. 3. Sequential intraoperative images of small bowel, each 90 sec: arrows indicate most intense focus of radioactivity. Left, first 25 cm of small bowel; center, 25-75 cm; right, 75-150 cm.

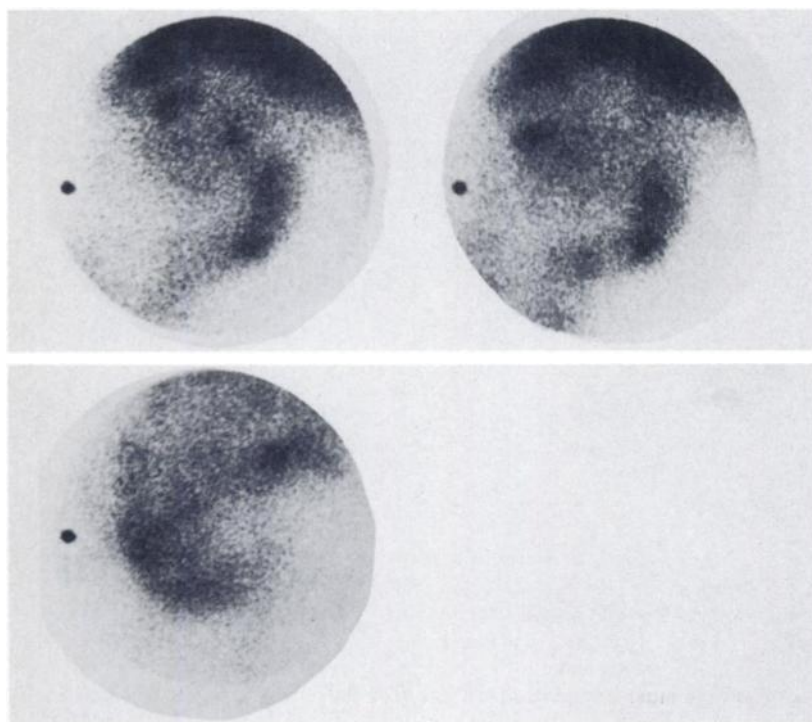


FIG. 4. Sequential 90-sec intraoperative images of small bowel. Activity continued to decrease distally: top left, 150-250 cm; top right, 250-350 cm; bottom, 350 cm to ileocecal valve.

been detected by this method (8). Unfortunately the scintigraphic study suffers from poor anatomic resolution and an inability to locate a bleeding site precisely, especially in the small bowel; however, as this case demonstrates, the more anatomically detailed but less sensitive studies such as endoscopy and angiography may be negative.

Faced with an inability to locate the bleeding site in this patient, the clinicians had two alternatives, resection of the entire jejunum or, resection of segments of the jejunum in multiple operative procedures until the bleeding site was removed. Since neither alternative was desirable, we attempted a radiotracer intraoperative procedure. A survey meter was used first in an effort to locate the bleeding site; however, the very sensitive directional response, relatively low efficiency for the 140-keV photon of technetium, and the radiation exceeding the maximum count rate capability of the instrument in several areas prevented the localization of the most intense focus of activity, presumably the bleeding site, with certainty. In addition, radiation from internal blood vessels and organs contributed to the total count rate and consequently the survey meter's maximal response may not have been at the actual bleeding site.

A small collimated scintillation probe would be an improvement over the uncollimated instrument that we used. Its responses would be less directional; perhaps the maximum count rates obtained would not exceed the maximum capability of the instrument. Its relatively low efficiency for the 140 keV photon of technetium, however, would still be a problem.

Chambers such as those used in radiation therapy to measure dose rates in the rectum and bladder from therapeutic implants suffer from low sensitivity. An end-window beta probe (eye probe) used for intraocular tumor location has reasonable directionality, but suffers from low efficiency due to its thin nonmetallic window (9). A clear advantage that the imaging device has over nonimaging probes is that the various structures themselves can be identified and separated from one another.

We are cognizant of the drawbacks of intraoperative scintigraphy, which include contamination (radioactive and septic) of the operative suite and the patient as well as the possibility that the patient may not have bled actively during the operation. In addition, just moving the small bowel around under the camera may have displaced radioactive blood away from the site of ex-

travasation. In fact, much of what we imaged was undoubtedly clotted blood within the bowel lumen. As scintigraphically demonstrated, however, the intensity of activity decreased dramatically beyond the first 50 cm of jejunum, so we considered that the bleeding site was probably within the proximal segment. We believe that intraoperative scintigraphic search for a gastrointestinal bleeding site may provide a valuable guide to surgical management.

REFERENCES

1. SOS TA, LEE JG, WIXSON D, et al: Intermittent bleeding from minute to minute in acute massive gastrointestinal hemorrhage: Arteriographic demonstration. *Am J Roentgenol* 131:1015-1017, 1978
2. ALAVI A: Scintigraphic demonstration of acute gastrointestinal bleeding. *Gastrointest Radiol* 5:205-208, 1980
3. WINZELBERG GG, MCKUSICK KA, STRAUSS HW, et al: Evaluation of gastrointestinal bleeding by red blood cells labeled in vivo with technetium-99m. *J Nucl Med* 20:1080-1086, 1979
4. MCKUSICK KA, FROELICH JW, CALLAHAN RJ, et al: Tc-99m red blood cells for detection of gastrointestinal bleeding: Experience with 80 patients. *Am J Roentgenol* 137:1113-1118, 1981
5. BEST EB, TEAFORD AK, RADER FH, et al: Angiography in chronic recurrent gastrointestinal bleeding: A nine year study. *Surg Clin North Am* 59:811-829, 1979
6. BAR AH, DELAURENTIS DA, PARRY CE, et al: Angiography in the management of massive lower gastrointestinal tract hemorrhage. *Surg Gynecol Obstet* 150:226-228, 1980
7. ATHANASOULIS CA, WALTMAN AC, NOVELLINE RA, et al: Angiography: Its contribution to the emergency management of gastrointestinal hemorrhage. *Radiol Clin North Am* 14:265-280, 1976
8. SMITH RK, ARTERBURN G: Detection and localization of gastrointestinal bleeding using Tc-99m-pyrophosphate in vivo labelled red blood cells. *Clin Nucl Med* 5:55-60, 1980
9. PACKER S: Ocular tumor localizing radionuclides. In *Handbook Series in Clinical Laboratory Science*, vol 1, CRC Press, Cleveland, Ohio, 1977, pp 72-76

American Board of Science in Nuclear Medicine

June 1, 1985

Houston, Texas

The next examination of the American Board of Science in Nuclear Medicine will be held June 1, 1985, in conjunction with the 32nd Annual Meeting of the Society of Nuclear Medicine.

Specialty areas which may be chosen for the examination include:

- Nuclear Medicine Physics and Instrumentation
- Radiation Protection
- Radiopharmaceutical and Radiochemistry Science
- NMR Physics and Instrumentation
- Nuclear Medicine Computer Science
- Nuclear Medicine Laboratory Science

For further information contact:

Dr. Eugene Vinciguerra, Secretary
 American Board of Science in Nuclear Medicine
 145 W. 58th St., New York, NY 10019
 Tel: (212)757-0520

Completed applications must be received by May 15, 1985