

Gallium-67 Citrate Localization in the Heart Secondary to Constrictive Pericarditis with Myocardial Fibrosis

Albert J. Moreno, Jerry M. Brown, Melvin J. Spicer, Hernando Mena, and Tommy J. Brown

William Beaumont Army Medical Center, El Paso, Texas

Scintigraphy has demonstrated gallium-67 accumulation within the heart in pericarditis and cardiomyopathies of various kinds. We present a case report of a 63-yr-old man with multisystem disease who showed extensive myocardial uptake of Ga-67 by scintigraphy. At autopsy, constrictive pericarditis with myocardial fibrosis was found. Gallium-67 localization has not been documented previously in myocardial fibrosis accompanying constrictive pericarditis.

J Nucl Med 25: 66-67, 1984

Constrictive pericarditis may mimic a variety of clinical syndromes such as congestive heart failure, the nephrotic syndrome, protein-losing enteropathy, and cirrhosis. Infrequently, constrictive pericarditis may be the sequela of virtually any type of acute pericardial disease (1). Myocardial fibrosis may accompany long-standing constrictive pericarditis (2). We describe a patient with a prolonged medical illness who had abnormal cardiac accumulation of gallium-67 and who was found at autopsy to have severe constrictive pericarditis with myocardial fibrosis.

CASE REPORT

A 63-yr-old man was referred to our hospital with a 1-yr history of progressive weakness, muscle wasting, diarrhea, and malaise. He also had anasarca, especially in the lower extremities, ascites, and cervical and inguinal lymphadenopathy. He had a past history of an 89% gastrectomy for peptic ulcer. He had a history of pericarditis of unknown origin 28 yr previously. He had also been disabled for the last 10 yr from seronegative rheumatoid arthritis. His current medications included an aspirin compound.

The patient was cachectic, afebrile, and normotensive. The neck showed distended jugular veins with prominent V waves. He had a Grade III/VI holosystolic murmur at the lower left sternal border, without radiation. This murmur increased with respirations and was felt to be compatible with tricuspid regurgitation. Ascites and marked pretibial edema were noted.

Pertinent laboratory values included a hematocrit of 30.2%, serum iron of 6 $\mu\text{g}/\text{dl}$ (normal 230-425), serum calcium 7.3 mg/dl (normal 8.5-10.5), serum total protein 4.7 g/dl (normal 6.0-8.5), serum albumin 1.5 g/dl (normal 3.5-5.5), serum urea nitrogen 14 mg/dl (normal 10-26), and serum creatinine 1.0 mg/dl (normal 0.7-1.5). The serum alkaline phosphatase was 236 U/l (normal 30-115), and the serum lactic dehydrogenase was 277 U/l (normal

80-200). Other values included Westergren sedimentation rate 60 mm/hr , free thyroxine index 2.3 (normal 4.4-12.2), T_4 by RIA 1.7 $\mu\text{g}/\text{dl}$ (normal 4.8-12), TSH of 8.1 $\mu\text{IU}/\text{dl}$ (normal $\times 7$), carcinoembryonic antigen (CEA) by RIA 11.3 ng/dl (normal 0-3), circulating immune complex in serum 50 μg AHG equivalents/ dl (normal <30), and no protein in the urine.

An electrocardiogram showed low voltage of the QRS complex and nonspecific T-wave changes. An echocardiogram demonstrated paradoxical septal motion with normal excursion of the posterior wall of the left ventricle. The LV chamber measured 4.7 cm (normal 3-5.6), the left atrium was 4.5 cm (normal 3-4.5), and the RV chamber was 3.3 cm (normal 3.1). Gallium-67 citrate scintigraphy showed increased uptake throughout the heart, including the septum. The RV chamber was prominent (Fig. 1).

The patient died despite intensive efforts to treat his congestive heart failure. Necropsy revealed pulmonary vascular sclerosis, acute pulmonary edema, central hemorrhagic necrosis of the liver, bilateral pleural effusion, ascites (3000 cc of clear fluid), edema of the lower extremities, and a patent gastro-jejunostomy. The heart weighed 750 g. The pericardial space was totally obliterated by dense fibrous tissue, measuring up to 1.5 cm in thickness and

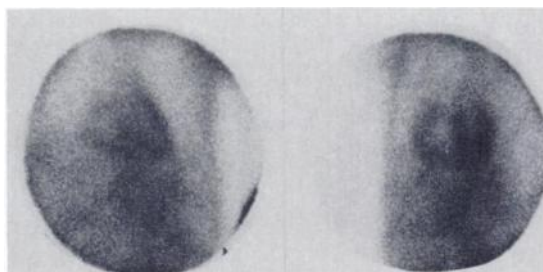


FIG. 1. Scintigrams of anterior chest at 48 hr after injection of 5.2 mCi of gallium-67 citrate. Note abnormal uptake of gallium in both anterior (left) and left anterior oblique (right) views. Septum is readily seen in LAO view.

Received May 26, 1983; revision accepted Aug. 8, 1983.

For reprints contact: Albert J. Moreno, MD, Nuclear Medicine Service, William Beaumont Army Med. Ctr., El Paso, TX 79920.

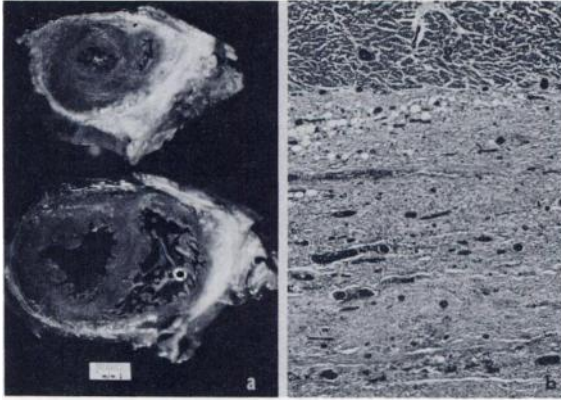


FIG. 2. (a) Dense fibrous tissue is deposited on epicardial surface, encasing heart. (b) Section from left ventricle showing infiltration of pericardial fat by abundant fibroblasts and lymphocytes, with collagen deposition and vascular proliferation. Myocardium is at top (hematoxylin-eosin 60X).

forming adhesions between the two layers of the pericardium (Fig. 2). Foci of inflammatory cells—mainly lymphocytes, histiocytes, and plasma cells—were present within the fibrous tissue and in perivascular spaces. No micro-organisms were identified. The myocardium showed focal fibrosis with foci of inflammatory cells. Mild coronary atherosclerosis was present. The cardiac valves and endocardium were unremarkable. Aside from myocardial fibrosis and constrictive pericarditis, there was no evidence of cardiomyopathy.

DISCUSSION

The scintigrams demonstrate gallium uptake within the inter-ventricular septum, as well as over the left and right free ventricular walls. The intense activity within the septum, equal to that in the other regions of the heart, suggests that the primary site of gallium deposition, at least within the septum, was within the myocardium. Myocardial fibrosis complicating constrictive pericarditis may represent a unique form of cardiomyopathy not previously noted with gallium scintigraphy. The proposed mechanisms for myocardial fibrosis accompanying constrictive pericarditis include subepicardial penetration of a primary pericardial inflammatory process, the simultaneous involvement of myocardium and pericardium by the same pathologic process (x-radiation, collagen vascular disease), impairment of coronary blood flow, or independent constrictive pericarditis and coronary artery disease (2). In our patient, the simultaneous presence of pericardial and myocardial disease may account for the paucity of cardiac findings usually attributable to classical constrictive pericarditis. However, tricuspid regurgitation has rarely been described with constrictive pericarditis (3).

In recent years, a number of inflammatory lesions in the heart have concentrated Ga-67. The list includes acute myocardial infarction (4), bacterial endocarditis (5), and various forms of pericarditis whose causes include nonspecific conditions (6), ma-

lignancy (7), tuberculosis (8), and histoplasmosis (8), myocarditis (9), tumor (10), sarcoidosis (11), and myocardial abscess (12). Presumably Ga-67 localization in constrictive pericarditis with myocardial fibrosis is due to accumulation of the tracer in areas of acute and chronic pericarditis and myocardial fibrosis where there is proliferation of lymphocytes, fibroblasts, and vascularity. It is the binding of Ga-67 to the inflammatory mononuclear leukocytes that may account for the abnormal localization (9).

In summary, constrictive pericarditis with myocardial fibrosis should be considered when Ga-67 concentrates in both pericardium and myocardium. A concurrent cardiomyopathy with pericarditis, however, cannot be ruled out by scintigraphy alone.

ACKNOWLEDGMENT

The opinions or assertions contained herein are the private views of the authors and are not to be construed as official or as reflecting the views of the Department of the Army or the Department of Defense.

REFERENCES

1. CANTWELL JD: *Modern Cardiology*. Boston, Butterworths, 1977, pp 156-157
2. LEVINE HD: Myocardial fibrosis in constrictive pericarditis. Electrocardiographic and pathologic observations. *Circulation* 48:1268-1281, 1973
3. BRAUNWALD E: Valvular heart disease. In *Heart Disease A Textbook of Cardiovascular Medicine*. Braunwald E, ed. Philadelphia, W. B. Saunders Company, 1980, p 1150
4. KRAMER RJ, GOLDSTEIN RE, HIRSHFELD JW JR, et al: Accumulation of gallium-67 in regions of acute myocardial infarction. *Am J Cardiol* 33:861-867, 1974
5. WISEMAN J, ROULEAU J, RIGO P, et al: Gallium-67 myocardial imaging for the detection of bacterial endocarditis. *Radiology* 120:135-138, 1976
6. O'CONNELL JB, ROBINSON JA, HENKIN RE, et al: Gallium-67 citrate scanning for noninvasive detection of inflammation in pericardial diseases. *Am J Cardiol* 46:879-884, 1980
7. SIMPSON AJ: Malignant pericardial effusion diagnosed by combined ⁶⁷Ga-citrate and ^{99m}Tc-pertechnetate scintigraphy. *Clin Nucl Med* 3:445-446, 1978
8. MOINUDDIN M, ROCKETT JF: Gallium imaging in inflammatory diseases. *Clin Nucl Med* 1:271-278, 1976
9. REEVES WC, JACKSON GL, FLICKINGER FW, et al: Radionuclide imaging of experimental myocarditis. *Circulation* 63:640-644, 1981
10. YEH SDJ, BENUA RS: Gallium-67-citrate accumulation in the heart with tumor involvement. *Clin Nucl Med* 3:103-105, 1978
11. TAJIMA T, NAITO T, DOHI Y, et al: Ga-67 and Tl-201 imaging in sarcoidosis involving the myocardium. *Clin Nucl Med* 6:120-121, 1981
12. SPIES SM, MEYERS SN, BARRESI V, et al: A case of myocardial abscess evaluated by radionuclide techniques: Case report. *J Nucl Med* 18:1089-1090, 1977