

CASE REPORTS

[<sup>131</sup>I] Iodocholesterol Scintiscan and a Rare "Functional" Black Adenoma of the Adrenal Cortex

Russell M. Dixon, Lionel M. Lieberman, Howard R. Gould, and Gholam-Reza Hafez

*University of Wisconsin, Madison, Wisconsin*

**A rare functional black adenoma (FBA) of the adrenal cortex was found to be the cause of hypertension and cushingoid features in a 34-yr-old white female. Preoperative studies included [<sup>131</sup>I] iodocholesterol scanning (ICS) of the adrenal glands, which demonstrated the increased release of cortisol from the affected adrenal gland, with the failure of the opposite adrenal gland to record. This is evidence that cortisol was suppressing adrenocorticotropin (ACTH) output by the pituitary gland. This case documents the clinical utility of "functional" imaging techniques in this clinical setting.**

**J Nucl Med 24: 505-507, 1983**

A 34-yr-old white female was initially hospitalized following an episode of aggressive behavior over which she felt she had no control. During hospitalization she had nocturnal supine blood pressure readings of 180/120 and episodes suggestive of catecholamine release. In one of several 24-hr urine samples the metanephrine was slightly elevated. A computerized axial tomogram (ICT) of the abdomen showed a 3-cm mass in the area of the left kidney. She was transferred to our hospital with a presumptive diagnosis of pheochromocytoma.

Except for long-standing (10 yr) obesity and hypertension, the patient had experienced few health problems. With salt restriction and diuretic therapy she had achieved normotension. Over the past year the addition of metoprolol tartrate was required to maintain blood-pressure control. Three months before admission she had discontinued all medications because of cost.

History reported occasional blurring of vision, easy fatigability, hyperhidrosis, and generalized weakness. She reported seemingly unprovoked episodes of anxiety-like symptoms associated with palpitations and chest tightness. Menstrual periods had become irregular over the last 13 mo. A persistent bitemporal headache was an almost daily occurrence since she stopped her antihypertensive medications. Dietary history suggested no relationship between the symptoms and ingestion of cheese, wine, chocolate, beer, bananas, or peanuts. A 5-hr glucose tolerance test several years earlier suggested "carbohydrate intolerance". Since then

she had "from time to time" followed a high-protein, low-carbohydrate diet.

Past medical history was unremarkable except for a fall from a horse and a motor-vehicle accident as a teenager. These were without sequelae. She had two normal pregnancies and deliveries.

Her mother had one kidney removed for unknown reasons; one brother had an episode of renal colic thought to be due to "stones". No family history consistent with multiple endocrine neoplasia syndromes could be obtained.

PHYSICAL EXAMINATION

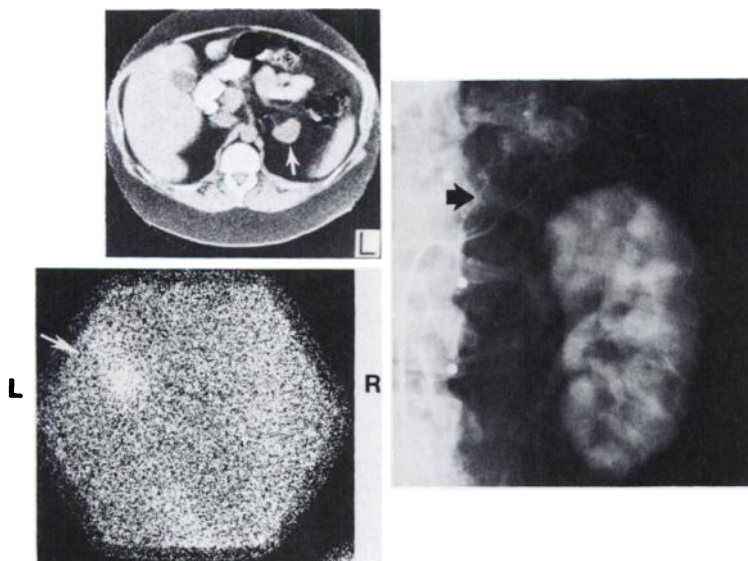
The patient was an obese female in no discomfort, with red cheeks, flushed facies, and a tendency towards truncal fat distribution.

Vitals: Height 5'7"; weight 215 lbs (ideal body weight 135-145 lbs); blood pressure 134/88 supine, 124/94 sitting; pulse 100 supine, 110 sitting; respirations 19/min; no fever.

She had hirsute facies, with dark hair on the upper lip, chin, and in the midline on her lower back. There was no temporal balding. A fat pad was present between the scapulae but lacked the appearance of a true "buffalo hump". Multiple uninjected striae were present on the lower abdomen and upper arms. No changes in skin pigmentation were present. Fundoscopic findings included swelling of both optic discs, several retinal hemorrhages, and A-V nicking. No visual-field defects were found on formal testing. Otherwise the examination of the head, eyes, ears, nose, and throat were normal. The thyroid gland was of normal size and consistency. Breasts, chest, and the cardiovascular system were normal except for a grade II/IV S<sub>4</sub> heart sound heard best along the left sternal

Received Nov. 15, 1982; revision accepted Jan. 27, 1983.

For reprints contact: Russell M. Dixon, MD, Assistant Professor of Endocrinology, Clinical Science Ctr. H4/566, University of Wisconsin Hospital and Clinics, 600 Highland Ave., Madison, WI 53792.



**FIG. 1.** Computerized tomogram of left adrenal gland (left, top). 3-cm mass arising from inferior aspect of left adrenal gland is demonstrated (arrow). Vessel is seen at medial aspect of mass. Normal right adrenal gland was seen at a different level. Posterior adrenal scintiphoto with I-131 iodocholesterol (1.09 mCi + 6 days) (left, bottom). Left adrenal gland is well visualized. No right adrenal gland is noted. This scan is characteristic of left adrenal adenoma, localized to adrenal cortex and suppressing right adrenal gland. Left renal angiogram (right). Large inferior adrenal artery (arising from origin of left renal artery, arrow) supplied hypervascular mass, 4 X 3 cm. No evidence of renal artery stenosis was found.

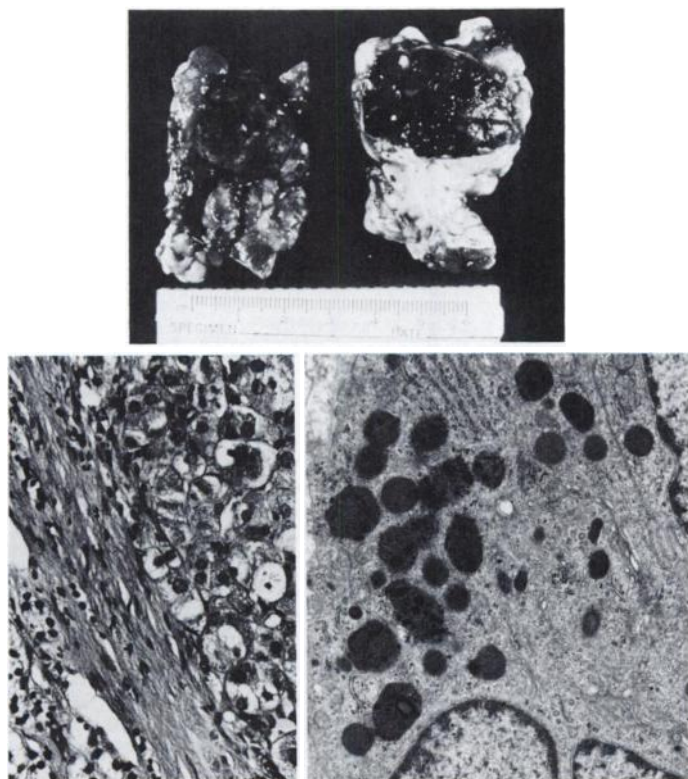
border. There were no surgical scars on the abdomen, no organomegaly, and bowel sounds were normal. A female escutcheon was present. Pelvic and neurological examinations were unremarkable.

**LABORATORY**

A CBC, SMA-12, urinalysis, electrolyte panel, clotting studies, chest radiograph, and ECG were normal except for several low potassium values of 3.3, 3.2 and 3.5 mmole/l and a hematocrit of 32% with hemoglobin of 10.5 g/dl. Thyroid function studies, parathyroid hormone, and calcitonin assays were normal. An intravenous urogram showed normal-sized kidneys with a contour defect in the mid portion of the left kidney suggestive of an infarct.

Duplicated ureters and collecting system were noted on the right. Representative laboratory values from the patient's adrenal status evaluation are shown in Table 1.

The 17-hydroxycorticosteroids (17-OHCS) were slightly elevated, as were the free catecholamine urine values. An overnight dexamethasone (1 mg) test failed to demonstrate a normal suppressed response. The serum ACTH was within normal limits. TCT of the adrenal glands demonstrated a 3-cm mass contiguous with the inferior aspect of the left adrenal gland (Fig. 1). An iodocholesterol scintiscan (ICS) from the sixth postinjection day is shown in Fig. 1. Only the left adrenal is seen, with suppression of the right adrenal, a finding highly suggestive of a left functional adrenocortical-cell adenoma. In Fig. 1C a frame of the angiogram of the left adrenal mass shows a large inferior adrenal artery



**FIG. 2.** Gross specimen (total weight 22 g) (top). Well-demarcated brown pigmented mass measuring 3.0 X 2.2 X 1.0 cm is seen at right. Adjacent sample at left contains normal adrenal tissue, which partially surrounded FBA. Light microscopic study (left). Shows large cells containing brown pigment and an eosinophilic, sometimes foamy, cytoplasm with one or two nucleoli, some of which are pleomorphic and contain prominent nucleolus. Electron microscope study (X 19,250) of left adrenal gland (right). Round, electron-dense inclusions are characteristic of lipofuscin-containing cytoplasmic granules.

**TABLE 1. REPRESENTATIVE PREOPERATIVE LABORATORY VALUES**

Laboratory tests	Patient	Normals
<b>Urine</b>		
17 ketosteroids (mg/24 hr)	5.3	5-15
17 hydroxysteroids (mg/24 hr)	9.2	3.5-7.5
VMA (mg/24 hr)	5.5	up to 10
Free catecholamine (μg/24 hr)	125.00	up to 115
Metanephrine (mg/24 hr)	0.73	up to 1.0
<b>Blood</b>		
Total testosterone (ng/ml)	0.12	0.08-.80
DHEA sulfate (μg/ml)	<0.1	0.11-4.55
ACTH (pg/ml)	25.00	up to 80
Cortisol (μg/ml)	14.3 AM	10-20
	5.9 PM	3-12
Cortisol (μg/dl) following overnight Dexamethasone suppression test (1 mg) (5)	17.2	

supplying 4 by 3 cm hypervascular mass. No evidence of renal artery stenosis was found during this study.

A preoperative diagnosis of adrenal adenoma was made and a left adrenalectomy was performed. Despite preoperative pharmacologic preparation (1) hypertensive episode occurred during manipulation of the 4-cm-diam adrenal mass. This was identified as a black adenoma of adrenal origin (Fig. 2). Electron microscope examination revealed typical features of steroid-producing cells, including prominent smooth and rough endoplasmic reticulum and mitochondria with vesicular cristae. In addition, many of the cells had numerous electron-dense granules of variable size consistent with lipofuscin (2,3). Postoperative management included a period of replacement therapy with hydrocortisone (4). One year after surgery and off medication the patient has remained normotensive, with no progression of her hirsutism. Weight has decreased to 176 lbs.

#### DISCUSSION

Although the patient presented with many symptoms compat-

ible with pheochromocytoma (headache, excessive perspiration, palpitations, tachycardia, chest pains, shortness of breath) she also exhibited features suggestive of early Cushing's syndrome. She had obesity, decreased glucose tolerance, hirsutism, menstrual irregularities, easy bruisability, and edema. Common to both syndromes were symptoms of hypertension, mental status changes, and weakness (5).

Cortisol levels slightly higher than normal suggested by the elevated 24-hr urinary 17-OHCS values—and the clear demonstration of iodocholesterol concentration in the left adrenal mass with suppression of the right adrenal—strongly suggested a left adrenocortical-cell adenoma. Strong confirmatory findings of a left adrenal mass on TCT, and tumor vessels on angiography, emphasize the importance of multiple imaging techniques in the adequate preoperative evaluation of this problem. The "functional" imaging study in this patient produced important information, which determined the appropriate surgical intervention and pre-, peri-, and postoperative management. The rarity of FBA of the adrenal gland in association with Cushing's syndrome is emphasized by the fewer than one dozen described in the literature (6). Other metabolically active tumors of the adrenal cortex have been identified using ICS (7), and this report documents its use in the preoperative evaluation of a FBA. In addition to demonstrating its application in an unusual setting, this case illustrates that "functional" imaging procedures, as exemplified by the ICS, play a major role in the complete pre-, peri-, and postoperative evaluation and management of a patient with suspected adrenal dysfunction.

#### REFERENCES

1. CROUT J, BROWN B: Anesthetic management of pheochromocytoma: The value of phenoxybenzamine and methoxyflurane. *Anesthesiology* 30:29-36, 1969
2. GARRET R, AMES RP: Black-pigmented adenoma of the adrenal gland. *Arch Pathol* 95:349-353, 1973
3. KOVAC K, HORVATH E, FELDMAN PS: Pigmented adenoma of adrenal cortex associated with Cushing's syndrome. Light and electron microscopic study. *Urology* 7:641-646, 1976
4. DEGROOT LJ: *Endocrinology*, Vol 2, Grune and Stratton, 1979, pp 1199-1200
5. KORENMAN SG, GRANNER DK, SHERMAN BM: Practical Diagnosis Endocrine Disease. Houghton Mifflin, 1978, pp 89-91, 111
6. ZANIEWSKI M, SHEELERS LR: Cushing's syndrome associated with functional black adenoma of the adrenal cortex. *Southern Medical Journal* 73:1410-1412, 1980
7. BEIERWALTES WH, STURMAN MF, RYO U, et al: Imaging functional nodules of the adrenal glands with <sup>131</sup>I-19-iodocholesterol. *J Nucl Med* 15:246-251, 1974