

Failure of Uptake of Radiocolloid by the Femoral Heads: A Diagnostic Problem: Concise Communication

Richard P. Spencer, Yil Sun Lee, John J. Sziklas, Ronald J. Rosenberg, and Mozafareddin K. Karimeddini

University of Connecticut Health Center, Farmington, Connecticut, and Hartford Hospital, Hartford, Connecticut

One hundred six patients had the area of the femoral head scintigraphed after completion of a Tc-99m sulfur colloid liver scan. In 47 (45%), there was no visible activity in the femoral heads. This was somewhat age-related. All six individuals in the 11- to 19-yr age group showed femoral-head uptake of radiocolloid, but only 37% of those 70 to 79 yr old revealed such accumulation. The finding that less than one half of adults had uptake of radiocolloid in the femoral heads was consistent with results of three smaller series of patients (larger dose of radiocolloid, use of a different preparation of sulfur colloid, and use of In-111 chloride). We conclude that not all adults take up radiocolloid in the femoral heads, and that lack of such uptake is not necessarily abnormal. Use of radiocolloid accumulation to gauge femoral-head vascularity may be more limited than previously appreciated, although right-left asymmetry might be of some diagnostic assistance.

J Nucl Med 24: 116-118, 1983

In children, aseptic necrosis of the femoral head displays a fairly definitive bone image (1,2). In adults, however, the "aseptic wedge" is often not clearly found. This may be because a different disorder is involved, or because the aseptic event is overshadowed by uptake in fractures that occur in the femoral head or neck in adults (3). Several authors have therefore suggested an additional diagnostic technique, namely the use of Tc-99m sulfur colloid, to determine whether a femoral head has a vascular supply. This assumes that the normal adult femoral head can accumulate radiocolloid. We investigated the validity of this assumption (4).

MATERIALS AND METHODS

Four different studies were carried out. In the first, 106 consecutive patients having Tc-99m sulfur colloid images of the liver and spleen also had the region of the femoral head analyzed. The femoral-head study was done at least 30 min after intravenous administration of

3 mCi of the radiocolloid.* The time delay permitted clearance from the blood stream. Imaging was by gamma camera†, with the collection of 300,000 counts. A three-point rating scale was used:

- 0 = no uptake seen in the femoral heads, despite uptake in the pelvic bone marrow;
- 1+ = femoral heads just visible;
- 2+ = femoral heads have uptake clearly discernable.

Examples of the images are shown in Fig. 1. Each image was read by two physicians independently and, when there was not exact agreement in the rating, the higher value was used. Of the total of 106 patients, all but one were asymptomatic as far as the femoral heads were concerned.

A second study centered on 12 adult patients with hip or pelvic pain, in whom a dose of 10-12 mCi of Tc-99m sulfur colloid was used (3-4 times the typical dose for liver/spleen scans). Images of 600,000 counts were obtained and the same rating scale was applied as in the first set of patients.

A third study also involved patients referred for

Received Sept. 13, 1982; revision accepted Nov. 4, 1982.

For reprints contact: Dr. Richard Spencer, Dept. of Nucl. Med., Univ. of Connecticut Health Science Ctr., Farmington, CT 06032.

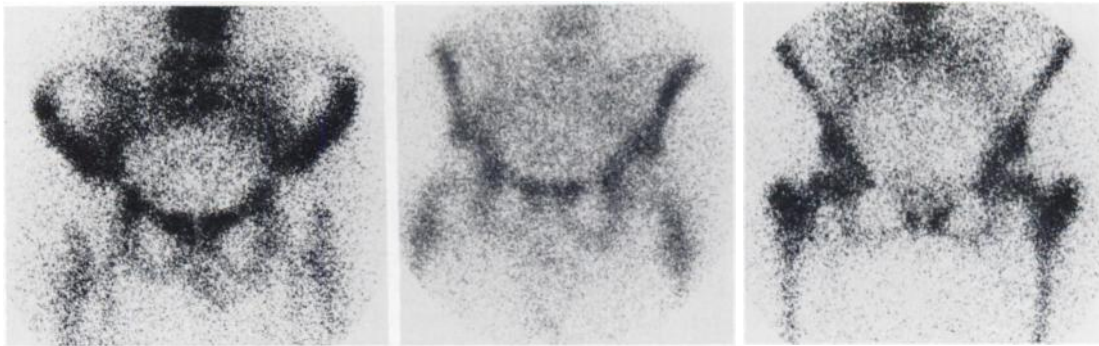


FIG. 1. From left to right, these images represent anterior femoral-head views in patients with zero, one plus, and 2 plus uptake of the radiotracer.

liver/spleen scans. This series used 4 mCi of Tc-99m sulfur colloid from a different supplier.[†] A gamma camera[‡] was used and 300,000 counts obtained. A total of 60 patients were followed.

A fourth study consisted of reviewing ten consecutive In-111 chloride bone-marrow scans (24 hr after injection) from local hospitals. These studies, on adults, were also graded by the same criteria as in all the above.

RESULTS

The population of the first series consisted of 66 females and 40 males. The age breakdown and femoral-head uptake of radiocolloid are shown in Table 1. Six patients were referred because of abdominal trauma. The others had been sent in for evaluation of cirrhosis, or because of known tumors elsewhere, or abdominal pain, or for other indications. Of 47 patients without femoral-head uptake of radiocolloid, 27 (57%) had normal liver images.

Results of the other three studies are shown in Table 2. When the larger dose of radiocolloid was used (10–12

mCi), 41% of the patients had no demonstrable uptake in the femoral heads. Considering all 82 patients in these three smaller series, 36 (44%) did not have radiocolloid in the femoral-head region. In no case did we see a significant difference of accumulation between the two femoral heads.

DISCUSSION

It is clear that the commonly used radiocolloids do not significantly accumulate in the femoral heads of a majority of adults. This is somewhat age-dependent, as shown in Table 1. For example, 100% of patients in the 11-to-19-yr age bracket had radiocolloid demonstrable in the femoral heads, but in only 37% of those 70–79 yr old was it visible.

This lack of uptake of radiocolloid in the femoral-head area did not necessarily reflect disease in the patients. For example, it also occurred in those with minor problems (blunt abdominal trauma). Of individuals without femoral-head uptake, 57% had entirely normal liver scans, and many others showed only minimal alterations,

TABLE 1. ANALYSIS OF RADIOCOLLOID ACCUMULATION IN THE FEMORAL HEADS IN 106 CONSECUTIVE CASES.*

Age range	No. cases	Femoral head uptake			Percent 1+ or better
		Zero	1+	2+	
11–19	6	–	6	–	100
20–29	7	2	4	1	71
30–39	8	4	4	–	50
40–49	11	4	5	2	64
50–59	23	13	7	3	44
60–69	32	12	19	1	63
70–79	19	12	7	–	37
Totals	106	47	52	7	

* In the total population studied, 47/106 (45%) showed no uptake in the femoral heads. The value was 47/100 (47%) in those age 20 and greater.

TABLE 2. SUMMARY OF THE THREE ADDITIONAL STUDIES THAT WERE CARRIED OUT

Study	Number of cases	Number with no femoral head uptake	Percent with no uptake
2. Femoral-head uptake, 10–12 mCi of Tc-99m sulfur colloid (Squibb)	12	5	41%
3. Femoral-head uptake, 4 mCi of Tc-99m sulfur colloid (Ackerman)	60	26	43%
4. Femoral-head uptake, 1 mCi of In-111 chloride	10	5	50%

such as a slight shift of radiocolloid to the spleen. Indeed, if severe liver disease were present, shift of radiocolloid to the bone marrow might be more frequent, but we could not demonstrate clear femoral-head uptake of radiocolloid in such individuals.

We thus conclude that lack of radiocolloid uptake in the femoral heads (as defined by the customary Tc-99m sulfur colloid) frequently occurs and is probably age-related. Hence, the extensive listing of diseases with failure of radiocolloid uptake in the femoral heads (5) may simply be including “normal” aging individuals. Our study also suggests re-evaluation of the need for data on blood flow to the proximal femoral area (6), to determine whether it truly reflects “marrow”. Lack of radiocolloid activity in the femoral heads is not necessarily an indicator of disease. Hence, in a significant number of patients, the radiocolloid study may provide little diagnostic information. Aside from minor variations, attributable to positioning of the patient, asymmetries between the right and left femoral heads were not observed in our asymptomatic patients. Thus, asymmetry between the left and right femoral heads, in terms of radiocolloid uptake, might be diagnostically helpful.

FOOTNOTE

- * E.R. Squibb and Sons kit.
- † G.E. 37 Maxicamera, large-field-of-view.
- ‡ Kits by Ackman Nuclear Pharmatopes, Inc.
- § Siemens, large-field-of-view.

ACKNOWLEDGMENT

Supported by USPHS CA 17802 from the National Cancer Institute.

REFERENCES

1. FASTING OJ, LANGELAND N, BJERKREIM I, HERTZENBERG L, NAKKEN K: Bone scintigraphy in early diagnosis of Perthe's disease. *Acta Orthopaed Scand* 49:169–174, 1978
2. DANIGELIS, JA: Pinhole imaging in Legg-Perthe's disease: Further observations. *Semin Nucl Med* 6:69–82, 1976
3. HOILUND-CARLSON PF, WIDDING A, UHRENHOLDT A, et al: Scintigraphic and bioptic findings after intracapsular fracture of the femoral neck. *J Nucl Med* 21: P 55, 1980
4. SPENCER RP, LEE YSC, SZIKLAS JJ, et al: Radiocolloid imaging of the femoral heads: A possible interpretive fallacy. *J Nucl Med* 23: P 29, 1982
5. LECKLITNER ML, NUSYNOWITZ ML: Nonvisualization of the femoral head in ^{99m}Tc-sulfur colloid medullary osteoscintigraphy. *Semin Nucl Med* 11:322–324, 1981
6. LAHTINEN T, ALHAVA EM, KARJALAINEN P, et al: The effect of age on blood flow in the proximal femur in man. *J Nucl Med* 22:966–972, 1981

**Southwestern Chapter
Society of Nuclear Medicine
28th Annual Meeting**

March 17–20, 1983

**Lincoln Plaza
Announcement**

Oklahoma City, Oklahoma

The Southwestern Chapter of the Society of Nuclear Medicine will hold its 28th Annual Meeting March 17–20, 1983, Lincoln Plaza, Oklahoma City, Oklahoma.

The program will include submitted papers, invited speakers, and teaching sessions covering areas of current interest in Nuclear Medicine. The program will be approved for credit toward the AMA Physicians Recognition Award under Continuing Medical Education Category 1 through the Society of Nuclear Medicine.

Scientific and Commercial Exhibits will be shown at this meeting.

The Southwestern Chapter annual Nuclear Medicine refresher course will be held March 17, 18, 1983. The course will include reviews of basic science, instrumentation, radiopharmaceuticals and in vitro and diagnostic imaging techniques. Nuclear Medicine scientists, technologists, and physicians interested in a state of the art review are invited to attend.

For further information contact:

Southwestern Chapter
1209 Lair Avenue
Metairie, LA 70003
Tel: (504)733-0063