Cerebral Blood-Flow Tomography: Xenon-133 Compared with Isopropyl-Amphetamine-Iodine-123: Concise Communication

N. A. Lassen, L. Henriksen, S. Holm, D. I. Barry, O. B. Paulson, S. Vorstrup, J. Rapin, M. le Poncin-Lafitte, J. L. Moretti, S. Askienazy, and C. Raynaud

Rigshospital, Copenhagen, Denmark, C. H. U. Saint Antoine, Paris, France, Hopital Henri Mondor, Créteil, France, Hopital Saint Anne, Paris, France, and Hopital Frederic Joliot, Orsay, France

Tomographic maps of local cerebral blood flow (CBF) were obtained with xenon-133 and with isopropyl-amphetamine-iodine-123 (IMP) in 11 subjects: one normal, two tumor cases, and eight cerebrovascular cases. A highly sensitive four-face, rapidly rotating, single-photon emission tomograph was used. The Xe-133 flow maps are essentially based on the average Xe-133 concentration over the initial 2 min during and after an inhalation of the inert gas lasting 1 min. These maps agreed very well with the *early* IMP maps obtained over the initial 10 min following an i.v. bolus injection. The subsequent IMP tomograms showed a slight decrease in contrast amounting to appr. five percentage points in the CBF ratio between diseased and contralateral areas. It is concluded that Xe-133 is more practical: low cost, available on a 7-day basis, easily repeatable, quantifiable without the need for arterial sampling, and with low radiation exposure to patient and personnel. On the other hand, IMP gives an image of slightly higher resolution. It also introduces a new class of iodinated brain-seeking compounds allowing, perhaps, imaging of other functions more important than mere blood flow.

J Nucl Med 24: 17–21, 1983

Single-photon tomography of inhaled Xe-133 has been used for some years to map local cerebral blood flow (CBF) in man (*1–3*). Based on animal studies by Winchell et al. (*4,5*) another lipophilic tracer, isopropyl-[^{123}I]iodoamphetamine (IMP) has recently been introduced for tomographic measurement of CBF in man (*6–9*). This study concerns a direct comparison between the two methods.

METHODS

The tomograph. The instrument we use is based on the principles pioneered by Kuhl et al. (*10*). It is a rapidly revolving four-faced, digital gamma camera system*.

The detector head consists of four specially constructed gamma cameras rotating around the head at a uniform speed of one half turn in 5 sec, i.e., the time it takes to record all projections needed for reconstruction. This does not mean, however, that one tomogram (one slice) is made every 5 sec. In order to obtain a sufficient number of counts many sets of projections are added together before the calculations. Thus, the fast rotation is essentially a means of obtaining a time-averaged picture of each slice. Three slices are recorded simultaneously.

A series of four 1-min pictures is taken during and after inhalation of xenon-133 (10 mCi/l) for 1 min. The counting rate is at its maximum approximately 500,000 cpm. With 2 mCi of IMP, the counting rate is about 60,000 cpm per slice after about 5 min. The spatial resolution in the plane is about 1.7 cm full-width-half-maximum (FWHM).

Received Apr. 27, 1982; revision accepted Aug. 24, 1982.

For reprints contact: Niels A. Lassen, MD, Dept. of Clinical Physiol., Bispebjerg Hosp., DK-2400 Copenhagen NV Denmark.

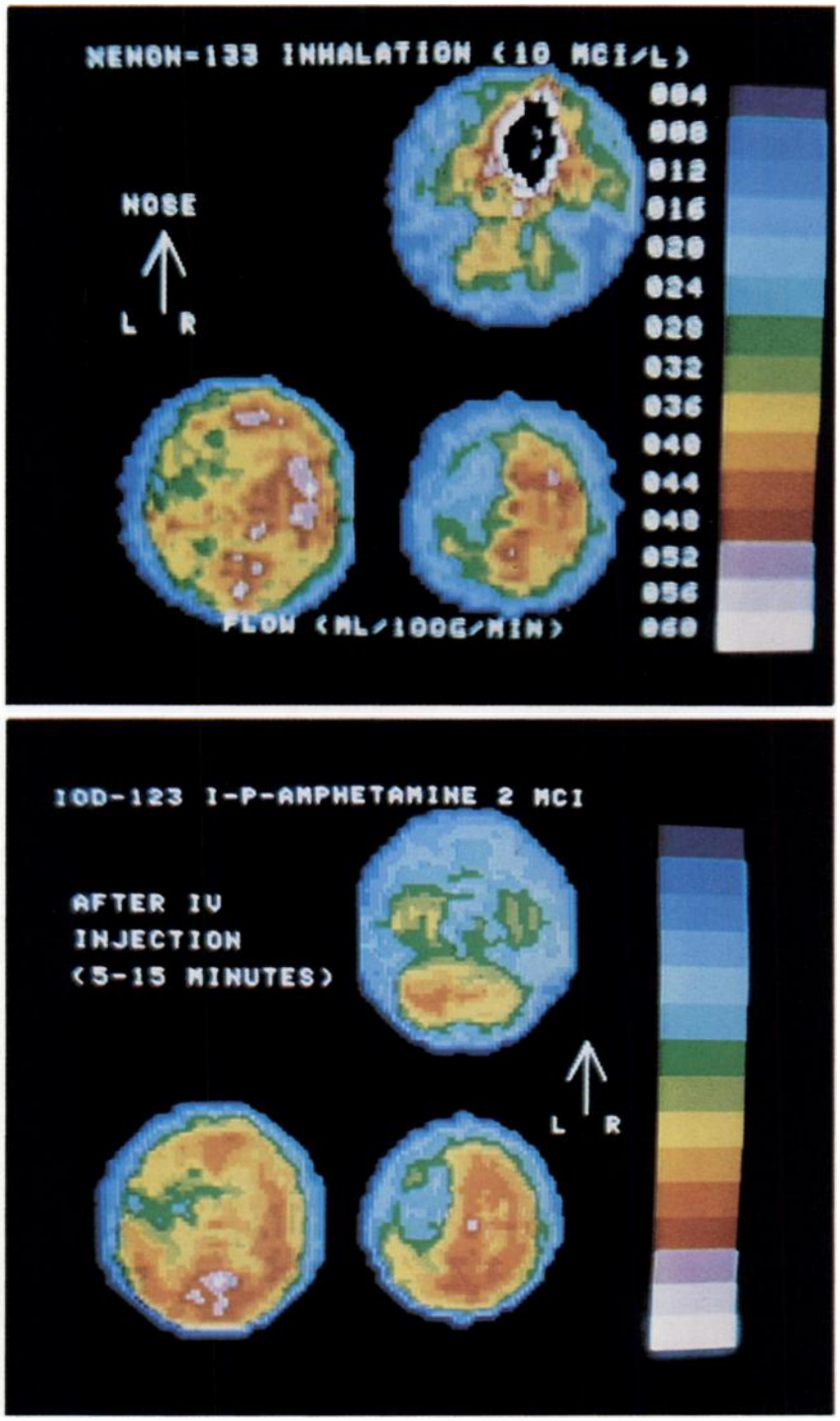

FIG. 1. Intracerebral hematoma in a 61-yr-old man with chronic hypertension. Right hemiparesis, no loss of consciousness. TCT shows large left-sided intracerebral hematoma with rim of edema. Here studied with Xe-133 and AMP(I-123) two weeks after onset of symptoms. Extent and degree of left-sided reduced flow signalled by Xe-133 and by IMP uptake is practically the same. Note reduced flow/uptake in right cerebellar hemisphere ("crossed cerebellar diaschisis").

The three slices recorded from have a thickness (FWHM) of 2.0 cm. The mid-slice planes are separated by 4 cm. This means that between the three slices there are two slices ~2 cm wide from which the instrument records very little. In order to see these slices, one must make a new study displacing the head 2 cm in the body's longitudinal direction. The detector head's four sides have 16 sodium iodide crystals each, giving 64 detectors in all. Each crystal is effectively 12 cm long and records simultaneously from all three brain slices; for each 4 cm of crystal a converging collimator sees the corresponding brain slice 2 cm wide. With three photomultipliers per

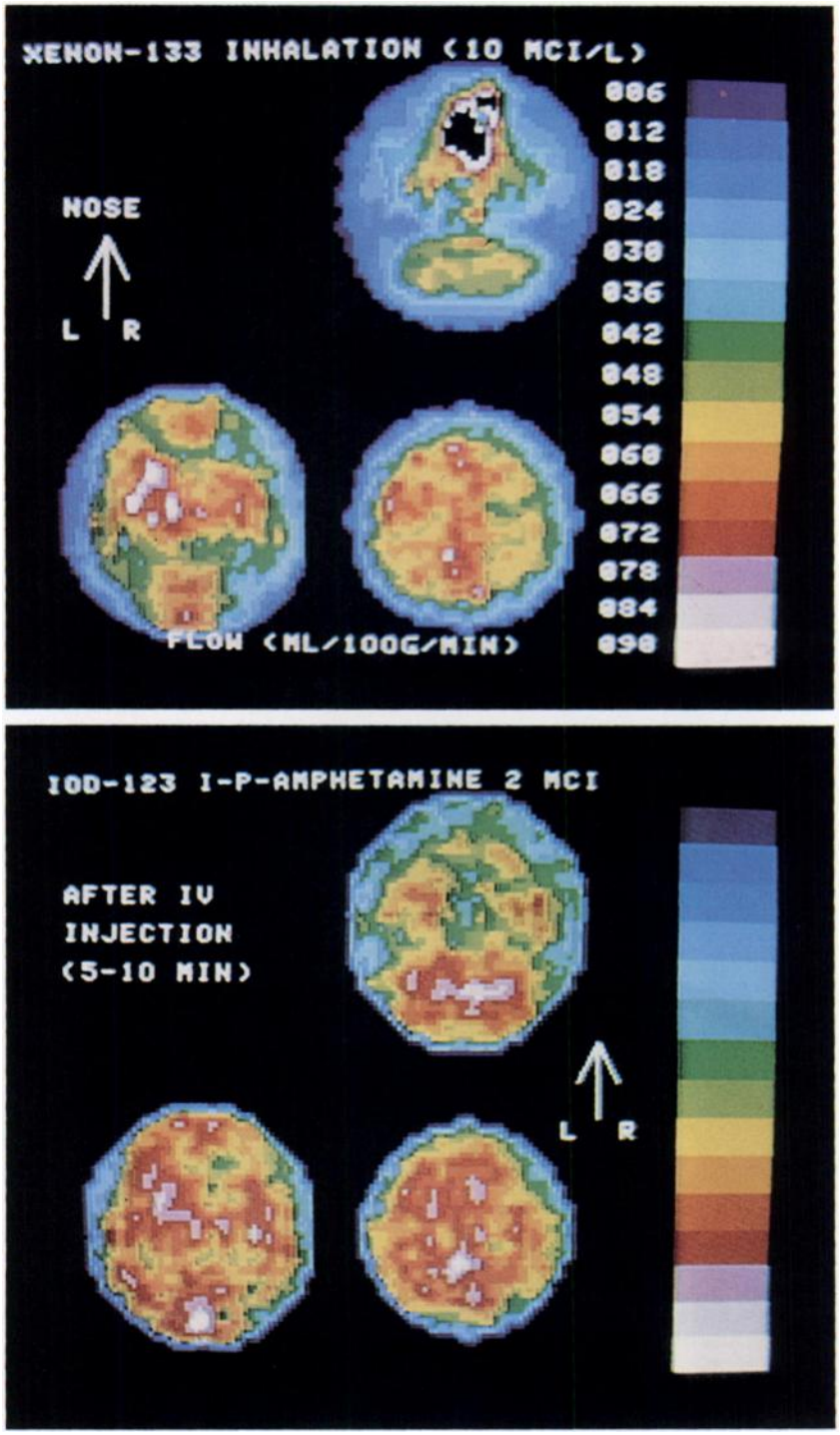

FIG. 2. Transient ischemic attacks and small infarct in a 33-year-old man with severe stenosis of right middle cerebral artery. TIAs involve left-sided hemiparesis. TCT shows small hypodense area in right hemisphere. Studied with Xe-133 and AMPI-123 several days after last TIA. The two methods concur in showing large areas of reduced blood flow/AMPI uptake in right hemisphere (area much larger than on TCT).

crystal, the instrument determines the position of the events correctly. Each of the 64 crystals thus functions, in essence, as a simplified Anger camera.

The tomograms are reconstructed from the observed projections using a filtered back-projection algorithm. An attenuation correction is applied, with its coefficient so set that a uniform source (a plastic bucket filled with water containing the nuclide) gives a uniform image.

The Xe-133 input curve is estimated by a single stationary scintillation detector placed over the right lung. Under inhalation of 10 mCi/l of Xe-133 for 1 min, the calculated gonadal radiation exposure is 0.04 rad/study,

and that of the critical organ, the lung, 0.37 rad/study (*11*).

With IMP the input curve was not recorded, since that would necessitate arterial sampling and hence violate the atraumatic nature of the study. For 2 mCi of I-123 the calculated gonadal radiation exposure is 0.1 rad/study, and that of the critical organ, the lung, 1.0 rad/study. Our iodine-123 is produced by the (p,5n) reaction, which avoids the contamination inherent in the (p,2n) reaction used by others (*8,9*). The lack of contamination not only lowers the radiation dose per mCi, but also provides a better image quality.

Calculations. For xenon-133 we use the approach of Celsis et al. to calculate CBF in ml/100 g-min (*3*). This method consists in a linearization and scaling of the average Xe image for the first 2 min. In providing area-to-area comparisons, the calculation modifies this 0–2 min picture only minimally, i.e., it gives essentially a picture of the early Xe-133 distribution.

For IMP the area-to-area difference of CBF was assumed to be given by the unaltered tomograms. This is correct provided the fractional extraction (E) and the subsequent fractional washout (k in min^{-1}) are the same for all areas. Taking a series of 10-min IMP scans over the first one-hour period, we calculated the ratio of counts over the area of interest (showing decreased uptake) relative to the contralateral one. If the assumptions stated are correct, this ratio signals relative CBF, and it should be constant.

The tracers. Xenon-133 was obtained in gaseous form and administered in a closed respiratory system giving a lung concentration of 10 mCi/l. Following 1 min of Xe-133 inhalation, the patient was switched to a non-rebreathing system, inhaling room air and exhaling for about 5 min through a xenon trap allowing re-use of the trapped radioactivity.

Isopropyl-para-[^{123}I]iodoamphetamine (IMP) was procured commercially†. An exchange reaction is used to label 15 mg of stable IMP with 2 mCi of I-123, yielding a specific activity of 0.133 mCi/mg. About 95 of the label migrated chromatographically as IMP in a chloroform 84% methanol 15% acetic acid 1% system.

CEREBRAL EXTRACTION OF IMP IN MAN

Two patients were studied by injecting IMP into the internal carotid artery and rapidly sampling the cerebral venous blood. The extraction in the brain was evaluated by comparing the dilution curve with that of $^{35}Cl^-$ (1 μCi) injected simultaneously. In the first patient, suffering from a meningioma, the extraction was measured twice, giving values of 89% and 90% (mean hemispheric CBF 56 ml/100 g-min). In the second patient, suffering from a ischemic cortical infarct, the extraction was also measured twice, giving 90% for both injections (mean hemispheric CBF 54 ml/100 g-min).

In both patients we used 0.6 mg IMP for the first injection and 2.4 mg for the second, and the extraction was not influenced by the amount injected. With intravenous injection of 15 mg, only about 5% of the tracer reaches the brain, i.e., ~0.75 mg of IMP. We thus found the same high extraction in man as Kuhl and coworkers (*8*) found in the monkey (they did not state the weight of IMP used). We conclude that the 15 mg of IMP used in our clinical series does not change the extraction from that found by Kuhl et al. (*8*) using, per study, 0.6 mg IMP labeled with 5 mCi I-123.

RESULTS COMPARING Xe-133 AND IMP

Eleven subjects were studied. The group comprised one normal man, two meningioma patients, and eight patients with cerebrovascular disease. Excellent agreement was found in all cases between the Xe-133 CBF tomograms and the IMP tomograms taken over the first 10 min when both are expressed in the same relative units (per cent of mean value), see Figs. 1 and 2.

A slight but systematic tendency was noted when following the IMP tomograms for 60 min: when the diseased area (low IMP uptake) was compared with the contralateral (normal) area, the asymmetry decreased with time. On average, the side-to-side difference decreased by about 5 percentage points: e.g., from 29% to 24% in one case or from 14% to 8% in another. This phenomenon tends to decrease the ease with which the diseased areas can be discerned on the later IMP tomograms.

DISCUSSION

The IMP method for the measurement of CBF has been validated in the recent studies by Kuhl et al. (*8*). They used dogs and arterial sampling to record the input to the brain. Over a wide flow range, good agreement was found with CBF, as measured simultaneously by labeled microspheres, with tissue samples collected 5 min after tracer injection. The present study offers supportive evidence comparing the IMP tomograms with Xe-133 tomograms in patients with focal brain disease from meningioma or stroke.

The IMP tomograms gradually lost some of their contrast in that the initial asymmetric pattern of tracer distribution became modified towards a more uniform, symmetric distribution over 1 hr (and much more markedly so over the following 24 or 48 hr). This observation is compatible with findings of Kuhl et al. (*8*) that the counting-rate ratio for grey matter to white matter in normal man decreased slightly over the first hour. Preliminary studies in rats by J. Rapin and M. le Poncin-Lafitte (unpublished observations) show the same tendency.

Our results thus indicate that in order to map CBF, the IMP tomograms should be taken within the first 10 min. Yet, since the modifications mentioned are slight, the pictures taken within the first 60 min are qualitatively acceptable. Considering the many imperfections of single-photon tomography—due to Compton scatter, tissue absorption, errors of reconstruction, and poor resolution ("partial volume effect")—one must concede that truly quantitative maps of tracer distribution cannot be obtained by SPECT. Therefore we concur with Kuhl et al. (*8*) in concluding that IMP tomograms taken within one hour essentially depict the distribution of local blood flow.

Despite the two validations mentioned—that of Kuhl et al. (*8*) and our own—the IMP method may have pitfalls. It is based on assuming the high (~90%) first-pass extraction found in normal nervous tissue. Our data tend to confirm this assumption for local areas of decreased flow in patients with meningioma and with cerebrovascular disease. Nevertheless, in other disease states this may not hold. Low IMP extraction in highly vascularized malignant brain tumors is a possible exception (*12*).

A tendency toward sharper outlining of tissue structures was found with IMP relative to xenon-133. This difference could be due to difference in counting rate, but may also reflect the better imaging afforded by the higher-energy photons of I-123. In particular the deeper structures should be better defined. Also, the absence of prominent activity in the nasal sinuses, seen with Xe-133, is an advantage in the evaluation of the lower parts of the frontal lobe.

In favor of Xe-133 tomography for routine CBF measurements in man may be mentioned: (a) no arterial sampling is needed, (b) the Xe-133 study lasts only 4 min, (c) the longer half-life and lower tracer cost of Xe-133, and (d) the lower radiation dose of Xe-133. On a clinical level it is of particular importance to stress that repeated studies with Xe-133 can be made at 15-min intervals, whereas between-study interval of 1 to 2 days must be used with IMP.

What, then, has IMP to offer? First of all it has been thought to offer high-resolution CBF tomograms with conventional orbiting gamma cameras. That, unfortunately, has not turned out to be the case. With a radioactive dose of 5 mCi per study, the counting rate per slice is too low to provide adequate resolution (personal experience). Thus, good images demand the use of high-sensitivity instruments such as the Harvard-detector brain-scanning system having, for its single slice, a sensitivity for Tc-99m of 14,000 cps/μCi/ml in a phantom 20 cm in diameter (*9*), or Kuhl's Mark IV having, for its single slice, a similar expressed sensitivity for Tc-99m of 15,400 cps (*8*), or our TOMOMATIC 64 system having for each of the 3 slices a similar expressed sensitivity for Tc-99m of 57,000 cps (171,000 cps for all three slices combined). It is also possible that a conventional single-crystal orbiting gamma camera could be modified to yield higher sensitivity and resolution per slice, if the camera is designed to rotate closer to the head and uses specially constructed converging collimators looking only at one or two slices.

FOOTNOTE

* Medimatic Inc., Gersonsvej 7, 2900 Hellerup, Denmark.
† Oris-CEA, Saclay, France.

REFERENCES

1. STOKELY EM, SVEINSDOTTIR E, LASSEN NA, et al: A single photon dynamic computer assisted tomograph (DCAT) for imaging brain function in multiple cross sections. *J Comput Assist Tomogr* 4:230–240, 1980
2. LASSEN NA, HENRIKSEN L, PAULSON O: Regional cerebral blood flow in stroke by 133 Xenon inhalation and emission tomography. *Stroke* 12:284–288, 1981
3. CELSIS P, GOLDMAN T, HENRIKSEN L, et al: A method for calculating regional cerebral blood flow from emission computed tomography of inert gas concentrations. *J Comput Assist Tomogr* 5:641–645, 1981
4. WINCHELL HS, BALDWIN RM, LIN TH: Development of I-123-labeled amines for brain studies: Localization of I-123 iodophenylalkyl amines in rat brain. *J Nucl Med* 21:940–946, 1980
5. WINCHELL HS, HORST WD, BRAUN L, et al: N-isopropyl-(123-I)p-iodoamphetamine: Single-pass brain uptake and washout; binding to brain synaptosomes; and localization in dog and monkey brain. *J Nucl Med* 21:947–952, 1980
6. KUHL DE, WU JL, LIN TH, et al: Mapping local cerebral blood flow by means of emission computed tomography of N-isopropyl-p(123-I)-iodoamphetamine (IMP). *J Cerebral Blood Flow & Metab* (Suppl. 1)I:25–26, 1981
7. KUHL DE, WU JL, LIN TH, SELIN C, PHELPS M: Mapping local cerebral blood flow by means of emission computed tomography of N-isopropyl-p (123-I)-Iodoamphetamine (IMP). *J Nucl Med* 22:P16, 1981
8. KUHL DE, BARRIO JR, HUANG SC, et al: Quantifying local cerebral blood flow by N-isopropyl-p-(123-I)-iodoamphetamine (IMP) tomography. *J Nucl Med* 23:196–203, 1982
9. HILL TC, HOLMAN BL, LOVETT R, et al: Initial experience with SPECT (Single-Photon Computerized Tomography) of the brain using N-isopropyl I-123-p-iodoamphetamine: Concise communication. *J Nucl Med* 23:191–195, 1982
10. KUHL DE, EDWARDS RQ, RICCI AR: The Mark IV system for radionuclide computed tomography of the brain. *Radiology* 121:405–413, 1976
11. ATKINS HL, ROBERTSON JS, CROFT BY, et al: Estimates of radiation absorbed doses from radioxenons in lung imaging. *J Nucl Med* 21:459–465, 1980
12. LAFRANCE ND, WAGNER HN, JR, WHITEHOUSE P, et al: Decreased accumulation of isopropyl-iodo-amphetamine (I-123) in brain tumors. *J Nucl Med* 22:1081–1083, 1981