

# Gallium-67 Scanning in Nitrofurantoin-Induced Pulmonary Reaction

Michael J. Crook, Peter D. Kaplan, and Mustafa H. Adatepe

*Allegheny General Hospital, Pittsburgh, Pennsylvania 15212*

**Gallium-67 scanning of the lung has been used in the detection and assessment of pulmonary disorders including sarcoidosis, interstitial fibrosis, and pulmonary malignancies. We found it useful in the evaluation of a patient with lung disease from nitrofurantoin. The efficacy of therapy can be assessed, and clinical improvement predicted, on the basis of serial gallium-67 scanning.**

**J Nucl Med 23: 690-692, 1982**

Since the reports of Israel and Diamond (1) and Sollaccio et al. (2), acute and chronic pulmonary reactions have been recognized following the use of the urinary antiseptic nitrofurantoin. The reactions include interstitial pneumonitis, interstitial fibrosis, and pleural effusion, as well as fulminant hemorrhagic pneumonitis (3-8). Treatment consists of discontinuing the offending drug and the administration of corticosteroids.

We present a case of acute pulmonary reaction to nitrofurantoin. The gallium scan provided a sensitive assessment of the extent of pulmonary involvement. Its value not only helped in diagnosis, but also in following the patient's course and predicting clinical improvement.

## CASE REPORT

A 64-year-old white female presented with a five-week history of an acute illness characterized by chills, rigors, fatigue, and low-grade fever. One week after the onset of these symptoms she began to note progressive exertional dyspnea. She was admitted to another hospital where a diagnosis of acute bronchitis was made. She was discharged greatly improved after treatment with oxtriphylline and erythromycin. One week after discharge, however, she was readmitted because of the recurrence of fever, chills, and progressive dyspnea. She was then transferred for further evaluation and treatment.

Additional history disclosed that the patient had undergone a hysterectomy and bladder suspension in 1977. Over the year preceding the present illness she had treated herself on an intermittent basis with Macrodantin for 'bladder discomfort'. She admitted taking the drug at home between her two recent hospitalizations.

Physical examination revealed a well-developed, thin woman breathing with rapid, shallow respirations at 26 per min. Heart rate was 100 per min and she was afebrile. Auscultation of the chest was normal. Neither finger clubbing nor cyanosis was noted. The remainder of the examination was normal. Because of the temporal relationship of her symptoms to drug ingestion at home, and improvement without the drug in the hospital, a diagnosis of nitro-

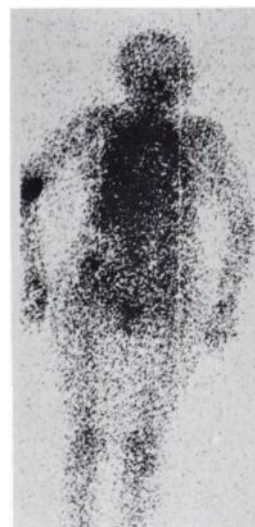furantoin toxicity was entertained.

A chest radiograph showed reticulonodular infiltrates in the lower lung fields. These were not present on a chest x-ray one year ago (Fig. 2). Arterial blood gases on room air, and pulmonary function studies, are presented in Table 1.

CBC and differential were normal; sedimentation rate was 50 mm/hr; antinuclear antigen and rheumatoid factors were negative. Echocardiogram was normal.

Four days after admission the patient underwent fiberoptic bronchoscopy, with transbronchial biopsies obtained from the right upper and lower lobes. The bronchial segments appeared normal and cytological examination of washings was unremarkable. The biopsy specimens showed nonspecific chronic pneumonitis with interstitial fibrosis.

The patient received 5 mCi of gallium-67 citrate intravenously on 3/31/80, and whole-body and rectilinear scans were performed 48 hr later. The scans showed marked, diffuse increased uptake in both lung fields. The calculated Gallium Index\* (3) was 345 in the left lung and 300 in the right lung for a total Gallium Index of 645 (Fig. 1).



**FIG. 1.** Whole body gallium-67 scan with diffuse increased uptake in both lung fields. Total Gallium Index (see text) is 645.

Received Feb. 8, 1982; revision accepted April 12, 1982.

For reprints contact: Michael J. Crook, MD, 62 Elm Street, Glens Falls, NY 12801.

TABLE 1. PULMONARY FUNCTION STUDIES AND ARTERIAL BLOOD GASES (ROOM AIR)

Measurement	Predicted Value	Admission to Allegheny General Hospital 3/80	Re-examination 6/80
Forced vital capacity, liters	2.97	1.55 (52%)	2.90 (98%)
Total lung capacity, liters	4.80	4.84 (101%)	5.14 (107%)
Forced expiratory volume in 1 sec, liters	2.33	1.25 (54%)	2.15 (93%)
Diffusing capacity (single breath) ml/min-mmHg	14.1	4.9 (35%)	15.6 (111%)
pH		7.46	7.50
PCO <sub>2</sub>		34	38
PO <sub>2</sub>		58	73
Saturation		91%	96%

The patient was started on 60 mg per day of prednisone and advised to discontinue the use of Macrodantin at home. She was discharged in stable condition and was readmitted two months later for re-evaluation after being weaned from steroids. Her symptoms had completely disappeared and her exercise tolerance had returned to normal.

Pulmonary function studies (Table 1) and arterial blood gases showed definite improvement compared with earlier studies.

A repeat Ga-67 scan showed normal uptake in the lungs and gave a calculated Gallium Index of zero (Fig. 3). Chest radiograph showed clearing of the lower-lobe infiltrates that were noted on films from her first admission (Fig. 4).

#### DISCUSSION

Nitrofurantoin-induced pulmonary reactions assume many forms (4-8). Most authors have described acute, subacute, and chronic forms, with varying presentations and objective findings. Our patient had an acute onset of symptoms with typical com-

plaints (fever, chills, exertional dyspnea) and objective findings (increased sedimentation rate and abnormal chest radiograph, arterial blood gases, and pulmonary function studies).

The precise mechanism by which nitrofurantoin affects the lung and provokes fibrosis is not known. Biopsy specimens usually reveal an inflammatory reaction with infiltration of lymphocytes, plasma cells, and eosinophils (4,8). Rechallenge of patients with known sensitivity to nitrofurantoin has produced an acute influenza-type reaction characterized by temperature elevation, chills, and cough. Because of these findings it is theorized that nitrofurantoin provokes a hypersensitivity reaction to lung parenchyma of the Arthus type (Type III hypersensitivity of Gell and Coombs) (5).

How this lesion provokes the avid uptake of gallium-67 is not known. Various studies have demonstrated marked Ga-67 uptake by lactoferrin—an iron-binding protein found in high concentration in polymorphonuclear leukocytes (PMNs) (9). Thus, lactoferrin deposited by PMNs at sites of inflammation provides the exudate with a large quantity of Ga-67-binding molecules. In nitrofurantoin pulmonary reaction, however, the cellular infiltrate is comprised of lymphocytes, plasma cells, and eosinophils. Other possible mechanisms of Ga-67 uptake in this lesion may relate to either T-lymphocytes (which have been shown to concentrate

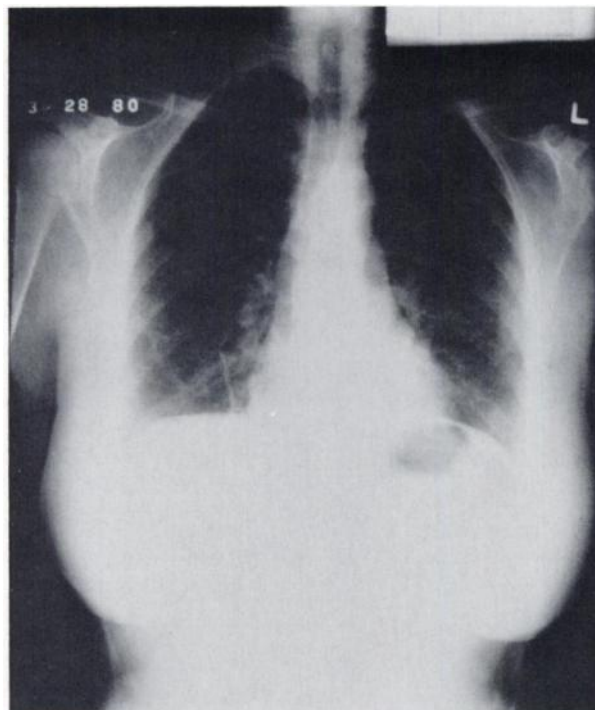


FIG. 2. Admission radiograph showing reticulonodular infiltrates in lower lung fields.

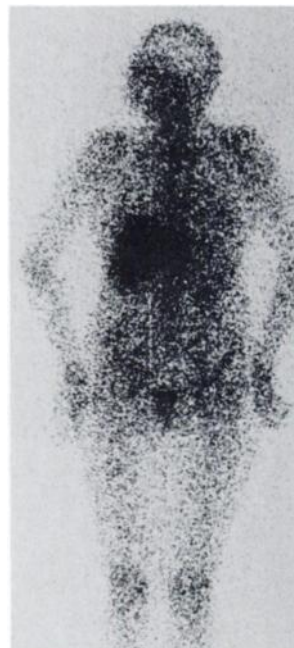


FIG. 3. Whole-body gallium-67 scan repeated after treatment, with normal uptake and Gallium Index of zero.

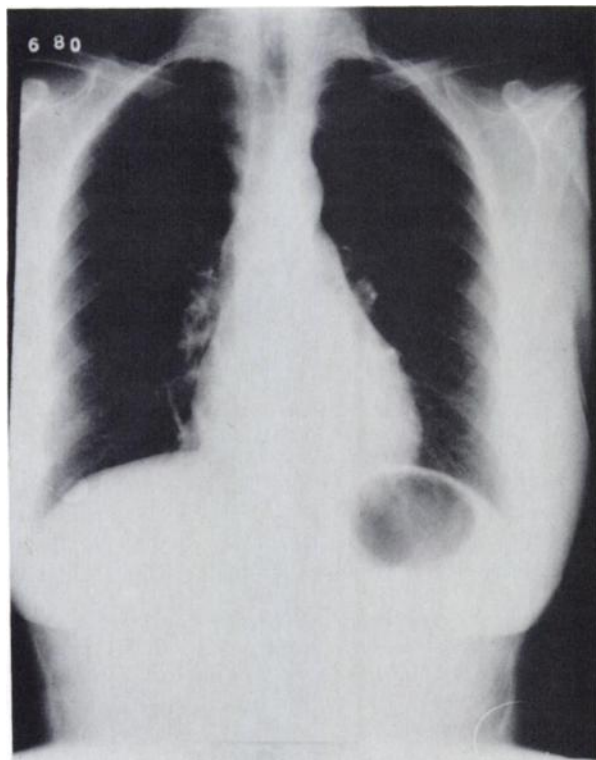

FIG. 4. Follow-up radiograph showing clearing of the lower-lobe infiltrates.

Ga-67 in vitro), or to the inflammation itself, which may increase capillary permeability allowing early influx of the radionuclide (10).

During the past decade, imaging of the lungs with Ga-67 citrate has been shown to be useful in the diagnosis, staging, and assessment of response to treatment of a variety of pulmonary disorders, including: (a) differentiation of pulmonary infarction from bacterial pneumonia; (b) detection of hilar and mediastinal involvement with pulmonary malignancies; (c) staging of interstitial lung diseases such as sarcoidosis and idiopathic pulmonary fibrosis (3,11).

Line and Fulmer et al. (3) reported the results of gallium scans in the evaluation of 30 patients with idiopathic pulmonary fibrosis. The calculated Gallium Index was significantly higher in the affected group compared with a group of normal controls. When compared with lung biopsy findings, the index correlated well with the degree of interstitial cellularity and alveolar cellularity. They concluded that quantitative evaluation of gallium scans, especially if done serially, may be a useful adjunct in the staging of disease activity and subsequent response to therapy.

The use of Ga-67 scanning was most helpful in the assessment and management of this patient with nitrofurantoin induced lung disease. The findings on the initial gallium scan correlated well with the clinical findings and suggested that the process was acute and potentially reversible. The dramatic symptomatic and functional improvement that occurred following the drug and administration of corticosteroids was paralleled by the return of the gallium scan to normal.

In view of the widespread use of chemotherapeutic agents with known lung toxicity (busulfan, bleomycin, methotrexate), gallium scanning may play an important role in evaluating other drug induced lung disease (12).

#### FOOTNOTE

\* Gallium Index— $\sum [(\% \times I_w) \times (T_w)]$  where % = area involved,  $I_w$  = Intensity weight (0 = background to 4 = liver uptake),  $T_w$  = Texture weight (0.5 patchy, 1.0 diffuse). The product of these three factors is determined for each region of increased gallium uptake; the products of each area are then summed to obtain the calculated Gallium Index (3).

#### ACKNOWLEDGMENT

The authors are grateful for the secretarial assistance of Kathy Bloskis and Irene M. Billow in preparation of this manuscript.

#### REFERENCES

1. ISRAEL HL, DIAMOND P: Recurrent Pulmonary Infiltration and Pleural Effusion due to Nitrofurantoin Sensitivity. *N Engl J Med* 266:1024, 1026, 1962
2. SOLLACCIO PA, RIBUADO CA, GRACE WJ: Subacute Pulmonary Infiltration due to Nitrofurantoin. *Ann Intern Med* 65(6):1284-6, 1966
3. LINE BR, FULMER JD, REYNOLDS HY, et al: Gallium-67 Scanning in the Staging of Idiopathic Pulmonary Fibrosis: Correlation with Physiologic and Morphologic Features and Bronchoalveolar Lavage. *Am Rev Res Dis* 118:355-65, 1978
4. BONE RC, WOLFE J, Sobonya RE et. al: Desquamative Interstitial Pneumonia Following Long-Term Nitrofurantoin Therapy. *Am J Med* 60:697-701, 1976
5. LARSSON S, CRONBERG S, DENNEBERG T, et al: Pulmonary Reaction to Nitrofurantoin. *Scand J Resp Dis* 54: 103-110, 1973
6. AVERBUCH SD, YUNGBLUTH P: Fatal Pulmonary Hemorrhage due to Nitrofurantoin. *Arch Intern Med* 140:271-3, 1980
7. ROSENOW EC, DEREMEE RA, DINES DE: Chronic Nitrofurantoin Pulmonary Reaction. *N Engl J Med* 279(23): 1258-62, 1968
8. SIMONIAN SJ, KROEKER EJ, BOYD DP: Chronic Interstitial Pneumonitis with Fibrosis after Long-Term Therapy with Nitrofurantoin. *Ann Thoracic Surg* 24:284-88, 1977
9. WEINER R, HOFFER PB, THAKUR MI: Lactoferrin: Its Role as a Ga-67-Binding Protein in Polymorphonuclear Leukocytes. *J Nucl Med* 22:32-37, 1981
10. LINE BR, HUNNINGHAKE GW, KEOGH BA, et. al: Gallium-67 Scanning to Stage the Alveolitis of Sarcoidosis: Correlation with Clinical Studies, Pulmonary Function Studies and Bronchoalveolar Lavage. *Am Rev Res Dis* 123:440-446, 1981
11. SIEMSEN JK, GREBE SF, WAXMAN AD: The Use of Gallium-67 in Pulmonary Disorders. *Semin Nucl Med* 8(3): 235-49, 1978
12. RICHMAN SD, LEVENSON SM, BUNN PA: Gallium-67 Accumulation in Pulmonary Lesions Associated with Bleomycin Toxicity. *Cancer* 36:1966-72, 1975