

PRELIMINARY NOTES

Evaluation of Human Thyroid Tumors by Proton Nuclear Magnetic Resonance

J. de Certaines, J. Y. Herry, G. Lancien, L. Benoist, A. M. Bernard, G. Le Clech

Centre Eugène Marquis, C.H.R. de Pontchaillou, Rennes, France

Proton nuclear magnetic resonance (NMR) was used in a study of 40 patients with thyroid tumors following partial or total thyroidectomy. Three patient groups were considered: those with nodules showing increased uptake, those with solitary nodules with decreased uptake, and those with multinodular goiters. Spin-lattice and spin-spin relaxation times (T_1 and T_2) were measured on samples of nodular and extranodular tissue from each patient. Increased T_1 and T_2 were observed for benign cold nodules, an increase in T_1 alone for nodules with increased uptake, and a wide fluctuation in T_1 and T_2 for multinodular goiters. The four cancers in the series did not show a distinctive proton NMR pattern in comparison with the other nodular structures studied. The results point to the feasibility of applying NMR techniques to the detection of thyroid disease.

J Nucl Med 23: 48-51, 1982

Nuclear magnetic resonance (NMR) techniques have not been widely applied to the study of the thyroid gland. Schara et al. (1) concluded that, in certain cases, the measurement of spin-lattice relaxation time (T_1) could be helpful in diagnosing benign thyroid tumors, and Sinadinovic et al. (2) found increased T_1 and spin-spin (T_2) values in thyroid tissue of rats given antithyroid medication. The present study was undertaken to explore the possible contribution of proton NMR measurements to the detection of thyroid disease. T_1 and T_2 were measured on fresh samples of human thyroid tissue. The results were compared with the findings of scintigraphy, laboratory tests, and histopathologic examination.

MATERIALS AND METHODS

Patients. Forty patients with nodular goiters were studied after partial or total thyroidectomy. Three groups were identified on the strength of scanning studies and histopathologic examination: ten patients with a nodule showing increased activity on scan and little or

no uptake in the remainder of the gland; 13 patients with solitary nodules showing decreased activity, of which nine were benign and four papillary carcinomas; and 17 patients with multinodular goiter consisting of multiple nodules with decreased uptake shown histologically to be benign adenomas. In the first group of ten patients, nodule autonomy was demonstrated by the TSH stimulation test, and microscopy showed the nodules to be adenomas, hyperfunctioning in some patients. In five of the ten patients elevated levels of circulating thyroid hormone were observed.

NMR measurements. Two samples of thyroid tissue were collected from each thyroid gland, one from the region of nodularity, the other from grossly healthy-looking tissue at some distance from nodular tissue. Part of each sample was used for microscopy, and part for NMR measurements. T_1 and T_2 measurements* were made at 20 MHz and a probe temperature of 23 °C. A $\pi - \tau - \pi/2$ pulse train was used to measure T_1 , and a Carr-Purcell-Gill-Meiboom sequence to measure T_2 (3). A maximum interval of 2 hr elapsed between thyroidectomy and measurements of relaxation time. Tissue samples were kept at 4 °C in sealed test tubes. The relaxation times remained unchanged for at least 12 hr under these conditions.

Received May 5, 1981; revision accepted Aug. 13, 1981.

For reprints contact: Jacques de Certaines, Service de Médecine Nucléaire, Centre Eugène Marquis, C.H.R. de Pontchaillou, 35011 Rennes Cedex, France.

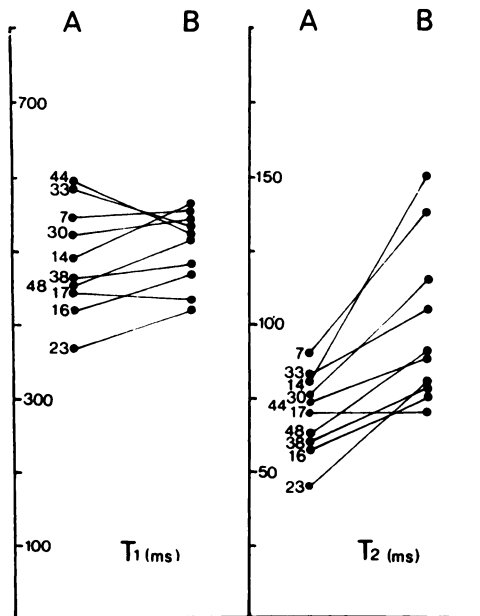


FIG. 1. Spin-lattice and spin-spin relaxation times (T_1 and T_2) of nodules with increased uptake (A = extranodular tissue; B = nodular).

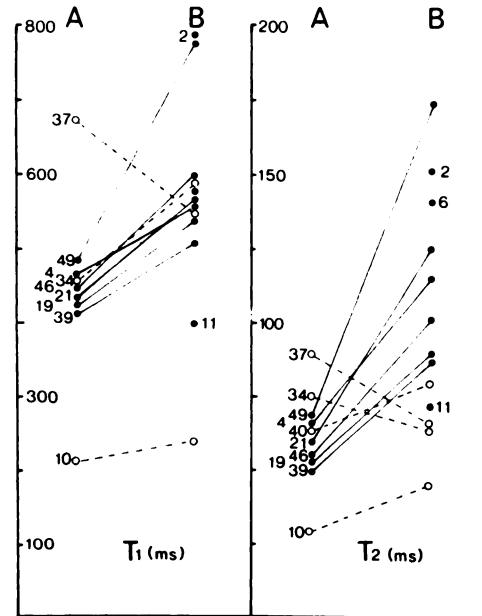


FIG. 2. Spin-lattice and spin-spin relaxation times (T_1 and T_2) of solitary nodules showing decreased activity (unbroken line = benign nodules; broken line = malignant).

Water content. For technical reasons the water content could be measured only in the last 18 patients studied (36 samples). The ratio was determined for weight of water evaporated by 48-hr exposure at 30 °C under partial vacuum (200 mbar) to that in fresh thyroid tissue, with a view to determining any relationship to relaxation times. Values were analyzed for statistical significance by the Student's *t*-test, and correlation coefficients were determined.

RESULTS

Nodules showing increased uptake. Compared with extranodular tissue relaxation times, the T_1 of these nodules showed a marked degree of variability, with an increase in seven patients and a decrease in three; T_2 was increased in all the patients except one, in whom no difference was noted (Fig. 1). Mean T_1 and T_2 values

and differences between nodular and extranodular relaxation times are shown in Table 1. Differences were not significant for T_1 , whereas the 42% increase in nodular T_2 relative to extranodular T_2 was highly significant ($p < 0.001$).

Solitary nodules showing decreased uptake. All patients in the group with benign nodules showed increased T_1 and T_2 (Fig. 2). The mean T_1 for healthy tissue was 448 ms ($\sigma = 116$ ms). This difference was significant ($p < 0.05$). T_1 and T_2 showed considerable variability for the four patients with papillary carcinoma (Table 2). An increase in T_1 was observed in two cases and a decrease in one case. T_1 was not measured in the fourth patient. T_2 rose in two cases and declined in two.

Multinodular goiters. There were no significant differences in relaxation times between nodular and extranodular tissue in the patients with multinodular goiter (Fig. 3 and Table 1).

TABLE 1. MEAN SPIN-LATTICE AND SPIN-SPIN RELAXATION TIMES (T_1 AND T_2) OF THYROID TUMOR						
	Extranodular tissue		Nodular tissue		Relative change	
	T_1	T_2	T_1	T_2	$\Delta T_1/T_1$	$\Delta T_2/T_2$
Nodules with increased uptake (N = 10)	490 ($\sigma = 69$)	69 ($\sigma = 13$)	529 ($\sigma = 79$)	108 ($\sigma = 38$)	3.8%	42%
Solitary nodule with decreased uptake (benign) (N = 9)	448 ($\sigma = 23$)	59 ($\sigma = 7$)	590 ($\sigma = 116$)	118 ($\sigma = 32$)	32%	95%
Multinodular goiter (benign nodules showing decreased activity) (N = 17)	513 ($\sigma = 55$)	74 ($\sigma = 13$)	541 ($\sigma = 76.5$)	88 ($\sigma = 25$)	5%	19%

Patient no.	Nontumor tissue		Tumor tissue		Relative change	
	T ₁	T ₂	T ₁	T ₂	ΔT ₁ /T ₁	ΔT ₂ /T ₂
10	210	30	240	46	14%	53%
34	437	76	565	64	6%	-16%
37	672	90	548	66	-18%	-27%
40	—	64	—	80	—	25%

Water content. In 18 patients (36 samples) a rough correlation was observed between relaxation times and water content: $r = 0.63$ for T₁ and $r = 0.58$ for T₂ (Fig. 4).

DISCUSSION

The results of the study provide further evidence of major differences in relaxation times between healthy and diseased thyroid tissue. When comparing the T₁ values found by different authors, the frequency and temperature used must be considered (3). Taking this into account, our results confirm the findings of Schara et al. (1), who measured only T₁. For extranodular tissue from patients with benign solitary nodules of decreased uptake, T₁ and T₂ values could be regarded as equivalent to those for normal thyroid tissue, since the sites of sampling were normal on gross and microscopic examination and the patients exhibited no signs of thyroid dysfunction. These measurements could thus be used as reference values. With respect to these reference times,

thyroid adenoma T₂ was consistently increased and T₁ frequently increased. These homogeneous nodular structures had relaxation times greater than or equal to those found in non-nodular sites. Changes such as necrosis, hemorrhage, and edema were associated with highly aberrant relaxation times; notably, in two patients with marked interstitial edema (Nos. 49 and 12, Figs. 2 and 3), T₁ and T₂ were greatly increased. This finding is in keeping with another study, which showed elevated T₁ and T₂ in edematous tissue (unpublished data). In another patient (No. 37, Fig. 2) with a thyroid cancer the tissue sample showed a very dense stroma and was more fibrous than the surrounding healthy tissue, and relaxation times were decreased. In patient No. 34, Fig. 2, fibrous changes were associated with low T₂ but not low T₁.

Changes in T₁ did not always correlate with changes in T₂. This was particularly evident in the group of patients with nodules showing increased activity, in which T₂ was greatly increased and T₁ showed little or no change. Thus, the information to be gained from measurement of T₁ is not necessarily the same as that provided by a T₂ measurement.

There were too few thyroid cancers in this series to permit appraisal of NMR as an aid in diagnosing thyroid malignancies. All that can be said about the findings in the four patients with papillary cancer is that they failed to exhibit NMR patterns clearly distinct from those of nodular goiter. This is consistent with the observation of Schara et al. (1) that a T₁ measurement is of no value

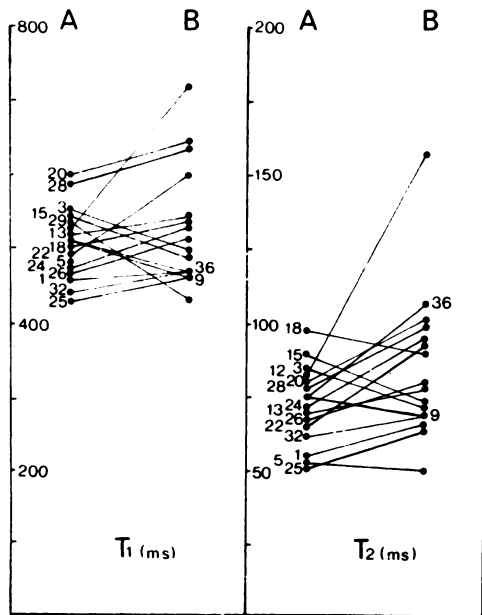


FIG. 3. Spin-lattice and spin-spin relaxation times (T₁ and T₂) of multinodular goiters.

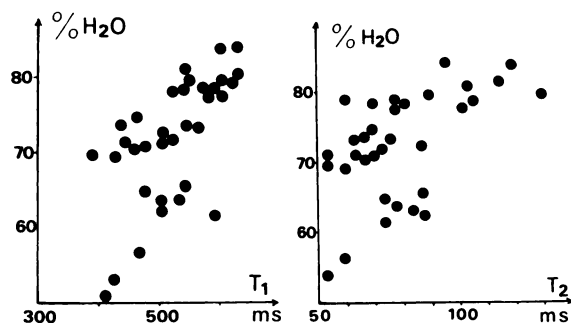


FIG. 4. Relationship between nuclear magnetic resonance relaxation times and tissue water content.

in the diagnosis of papillary cancer. Further investigation is required to verify the hypothesis, postulated by this group, of a correlation between T_2 and degree of tumor cell differentiation. In patients with nodules showing increased uptake, the extranodular thyroid tissues that failed to take up tracer were dormant; histologically they consisted of large follicles lined with flat epithelium and containing abundant colloid. This tissue had slightly higher T_1 and T_2 values than reference tissue (Table 1). In rats treated with antithyroid medication, Sinadinovic et al. (2) observed increased relaxation times in thyroid tissue. The histologic appearances were different, however, from those described above, with elevated follicular epithelium and absence of colloid. Further experimental models are needed to study the interrelationships between changes in thyroid function and relaxation times.

The present findings suggest that NMR tomography (4) might be used advantageously to detect diffuse or nodular thyroid disease in human patients. It is not unlikely that the respective roles of scintigraphy and ul-

trasound in thyroid diagnostic studies will need review in the light of this newcomer to the investigative armamentarium.

FOOTNOTE

* Bruker Minispec P 20 spectrometer.

REFERENCES

1. SCHARA M, ŠENTJURC M, AUERSPERG M, et al: Characterization of malignant thyroid gland tissue by magnetic resonance methods. *Br J Cancer* 29:483-486, 1974
2. SINADINOVIC J, RATKOVIC S, KRAINCANIC M, et al: Relationship of biochemical and morphological changes in rat thyroid and proton spin-relaxation of the tissue water. *Endokrinologie* 69(1):55-66, 1977
3. FARRAR TC, BECKER ED: *Pulse and Fourier Transform NMR. Introduction to Theory and Methods*. London, Academic Press, 1971, pp 20-33
4. MALLARD J, HUTCHINSON JM, EDELSTEIN W: Imaging by nuclear magnetic resonance and its bio-medical implication. *J Biomed Eng* 1(3):153-160, 1979

**SOUTHWESTERN CHAPTER
SOCIETY OF NUCLEAR MEDICINE
27th ANNUAL MEETING**

March 26-28, 1982

North Park Inn

Dallas, Texas

The program will feature an in-depth review of the role of nuclear medicine in gastrointestinal and cardiovascular evaluation. Featured speakers will be Abass Alavi, M.D., and Robert E. Henkin, M.D., with additional teaching sessions in each area. Contributed scientific papers, in all areas, will be accepted but special emphasis will be given to studies in the areas of special emphasis. The program will be approved for credit toward the AMA Physicians Recognition Award under Continuing Medical Education Category 1 through the Society of Nuclear Medicine.

The Southwestern Chapter annual Nuclear Medicine refresher course will be held March 25, 1982 at the North Park Inn. The course will include reviews of basic science, instrumentation, radiopharmaceuticals, and in vitro and diagnostic imaging techniques. Nuclear medicine scientists, technologists, and physicians interested in a state-of-the-art review are invited to attend.

For further information contact:

Southwestern Chapter, Society of Nuclear Medicine
1209 Lair Ave.
Metairie, LA 70003
Tel: (504)733-0063