

# Scintigraphy of Hepatic Hemangiomas: The Value of Tc-99m-Labeled Red Blood Cells: Concise Communication

Dov Front, Henry D. Royal, Ora Israel, J. Anthony Parker, and Gerald M. Kolodny

*Rambam Medical Center, Haifa, Israel and Harvard Medical School and Beth Israel Hospital, Boston, Massachusetts*

**Fourteen patients with hepatic hemangiomas were evaluated by Tc-99m colloid scintigraphy and Tc-99m RBC angiography, including flow studies and early and delayed static studies. On colloid scintigraphy, the liver appeared enlarged, with single or multiple focal defects. During the flow and early static Tc-99m RBC studies, the lesions showed poor perfusion and were filled only partially or not at all. Delayed Tc-99m RBC studies demonstrated the whole extent of the lesion and all the lesions when multiple hemangiomas were present. A flow study showing decreased perfusion and a late blood-pool study showing increased local blood volume appear characteristic of hemangiomas. Liver biopsy should not be attempted in such cases.**

**J Nucl Med 22: 684-687, 1981**

According to several authors (1-3), hemangiomas constitute 0.4-7% of all liver neoplasms and are the most common type of benign tumor of the liver. Their clinical management is different from that of malignant liver neoplasms, secondary or primary. The role of scintigraphy in the identification of hemangiomas has not been established and, as recently suggested, may be nonspecific and sometimes misleading (4). The present study was prompted by a patient with liver scintigraphic findings of a focal defect and sulfur colloid angiography that indicated no increase in radionuclide flow. The patient had severe bleeding after a needle biopsy of the liver and a cavernous hemangioma was later demonstrated. The scintigraphic characteristics of hemangiomas are described, and the value of scintigraphy in indicating the vascular nature of these tumors is assessed.

## MATERIALS AND METHODS

In our institution we have studied 14 patients whose

clinical diagnosis was hepatic cavernous hemangioma and who had undergone radiocolloid liver scintigraphy and Tc-99m-labeled RBC angiography. In six patients the findings of contrast angiography were typical of hemangioma. In four patients liver biopsies had been performed, two being obtained during surgery and two by needle biopsy. In another four patients the 12-30-mo clinical followup indicated no change in liver size or function and the findings of angiography with Tc-99m-labeled red blood cells, to be discussed, were felt to establish the diagnosis.

Liver scintigraphy was performed with Tc-99m sulfur colloid in six patients and with Tc-99m phytate in eight. Radionuclide angiography with red blood cells, labeled in vitro using 15 mCi of Tc-99m and a commercial kit, was done in all patients in the projection that had best demonstrated the lesion on the radiocolloid scan. Two-second images were obtained after the bolus injection of the tracer. The flow study was followed immediately by an early blood-pool study. Images were taken in the anterior, right lateral, and posterior views, and in additional views when deemed necessary. Delayed blood-pool studies were done 1-2 hr after the injection. A large-field-of-view camera or scanning table was used for the late static Tc-99m RBC studies.

Received Dec. 16, 1980; revision accepted March 26, 1981.

For reprints contact: Dov Front, MD, PhD, Div. of Nuclear Medicine, Rambam Medical Center, Haifa, 35254, Israel.

**TABLE 1. SCINTIGRAPHIC CHARACTERISTICS OF HEPATIC HEMANGIOMAS IN 14 PATIENTS**

Radiocolloid liver scintigraphy		Scintigraphy with Tc-99m-labeled RBCs			
Liver Size		Radionuclide flow		Additional information from late static studies*	
Normal†	1	Perfusion similar to normal liver	0	Lesion on blood-pool study larger than that on radiocolloid	7
Abnormal	13	Decreased perfusion	6	Additional lesions on RBC blood-pool undetected by colloid	5
		Decreased perfusion with small areas of increased flow	5	Photon-deficient areas in lesion shown on RBC	6
Abnormality		Increased perfusion	0		
Single defect	11	Not done	2		
Multiple defects	3	Undetermined	1		
		<u>Early static study</u>			
		Partial filling of lesion	9		
		Nonfilling of lesion	3		
		Not done	2		
		<u>Late static study</u>			
		Activity similar to normal liver	0		
		Activity higher than normal liver	14		
		Activity lower than normal liver	0		

\* Note that some patients had more than one finding.

† Case shown in Fig. 1.

**RESULTS**

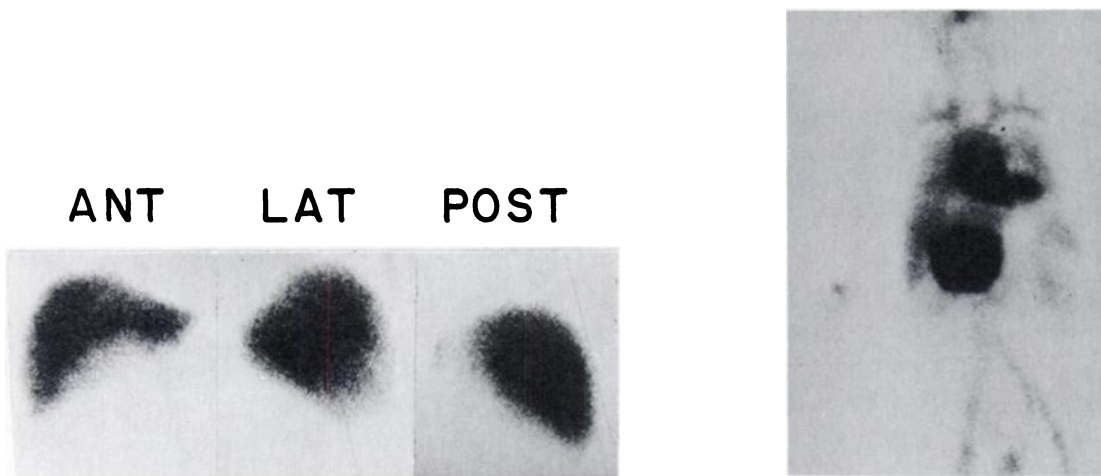
The results of radiocolloid and Tc-99m RBC studies are summarized in Table 1.

**Radiocolloid liver scintigraphy.** The liver was enlarged in 13 of 14 cases. In one patient physical examination showed a large mass in the right upper quadrant. On scintigraphy with phytate (Fig. 1), the liver appeared

normal in size, but the delayed study with Tc-99m RBCs showed a large hemangioma extending far beyond the margins of the liver.

In 11 cases the hemangioma presented as a single lesion, usually occupying a large area of the liver; one patient had a single, small focal defect. Multiple lesions were found in three cases.

**Scintigraphy with Tc-99m-labeled RBCs.** Radionu-



**FIG. 1.** (Left) Tc-99m phytate scintigraphy in anterior, lateral, and posterior views. Liver appears to be normal in size, with some evidence for pressure on its inferior border. (Right) Tc-99m RBC scintigraphy after 2 hr shows increased blood volume in hemangioma, the greater part of which is beyond normal border of liver.

clide angiography showed a perfusion defect in all 11 patients examined by this technique. In six cases decreased perfusion was noted in the entire lesion, whereas in five cases some small areas of increased perfusion were evident in the otherwise unperfused area (Fig. 2).

Early blood-pool studies were performed in 12 cases. In three of these, the lesion appeared as a photon-deficient area. In the other nine there was some degree of filling with radioactivity but the greater part of the lesion remained photon deficient (Fig. 2).

In the delayed blood-pool studies, all 14 patients showed complete filling of the lesion, radioactivity levels being much higher than in the liver or neighboring tissues, only the heart showed comparable activity. In seven cases, the lesion was much larger than the focal defect delineated by colloid scintigraphy, and additional lesions undetected by colloid scan were revealed in five. Photon-deficient areas were found in six cases, probably indicating thrombosis or infarction.

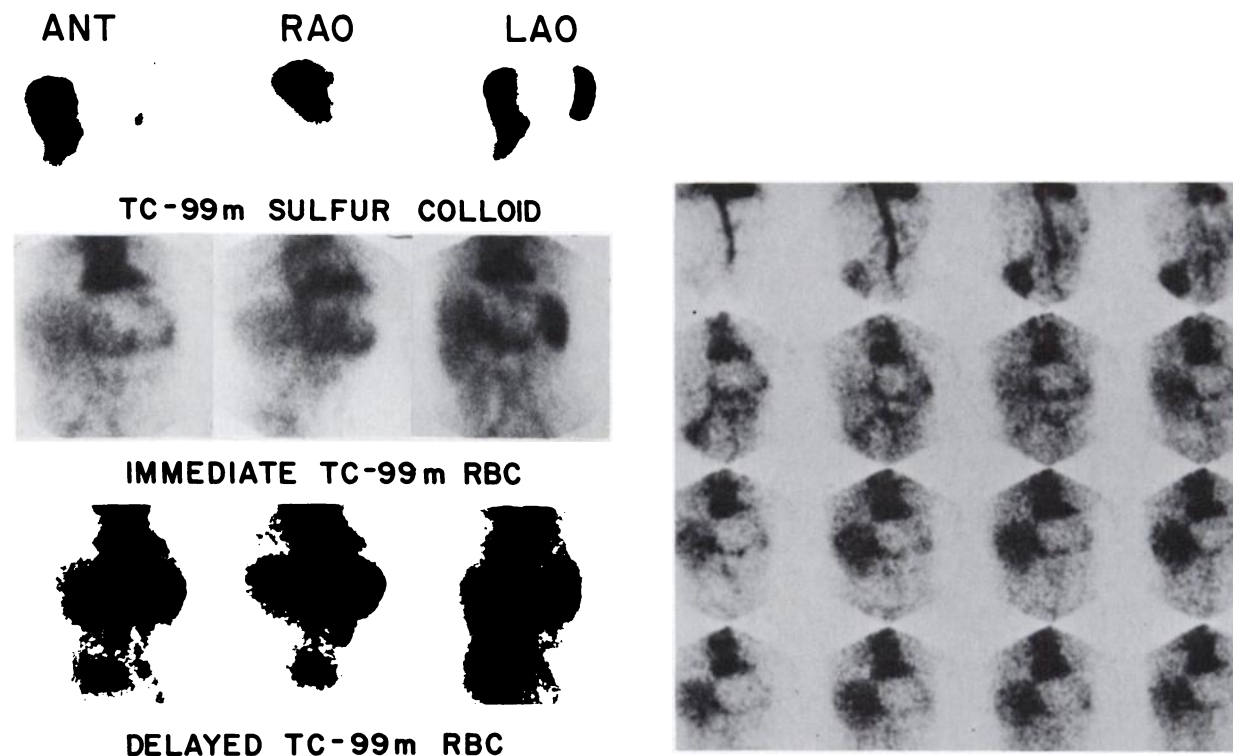
#### DISCUSSION

Hepatic hemangiomas may be detected incidentally at autopsy, in a clinical workup of patients suspected of harboring malignancy of the liver, or when they produce symptoms. Hemangiomas vary in size and may reach 30 cm in diameter. They are usually single, but may be multiple or pedunculated, and may reach beyond the normal margin of the liver. One third or more of the

patients present with symptoms related to a mass and pressure on adjacent abdominal organs. Thrombosis and infarction may be associated with pain (1-3).

Colloid liver scintigraphy is nonspecific, and hemangiomas appear in our material as a single large lesion (4-6) or as multiple focal defects closely resembling metastatic spread. Sometimes no significant change is noted (Fig. 1). Technetium-99m RBC studies are more informative. Radionuclide angiography and delayed blood-pool studies may seem to give contradictory results. With flow studies the lesion has less activity compared with the normal liver, and no increase in flow is detected in either the arterial or the portal phase. In the delayed static studies, the lesion has much higher activity than the liver. This "perfusion/blood-pool mismatch," which can occur because these two techniques image different entities, is the key to the scintigraphic diagnosis of hepatic hemangioma.

Radionuclide angiography reflects the regional blood flow of the lesion, whereas the late static Tc-99m RBC study shows the blood pool. Visualization of the whole extent of the lesion can be achieved only after complete mixing of radionuclide and blood in the hemangioma. The degree of mixing—and hence the extent to which the lesion is demonstrated—depends on the length of time between the injection and the study. Early blood-pool studies, occurring when mixing is incomplete and the vascular nature of the lesion is not evident, may be



**FIG. 2.** (Left) Liver scintigraphy in anterior, right anterior oblique, and left anterior oblique views. Sulfur colloid scintigraphy shows large focal defect in left lobe. Immediate Tc-99m-labeled RBC shows focal defect, with some increased activity in the periphery. Late Tc-99m RBC static study shows large blood volume in left lobe. (Right) Two-second angiography with Tc-99m-labeled RBCs indicates perfusion defect in left lobe.

misleading (4). The same is true for radionuclide angiography, which is considered, in general, to be a good indicator of the vascularity of hepatic lesions and is "useful preparatory to liver biopsy by establishing any risk produced by the presence of a vascular lesion" (7). This apparently is not the case in hepatic hemangiomas, where the flow study does not show increased activity and a liver biopsy may have catastrophic results.

A Tc-99m RBC flow study demonstrating decreased perfusion and a late blood-pool study indicating increased blood volume are characteristic of hepatic hemangiomas. Delayed studies also show lesions that are not appreciated on liver colloid scintigraphy (Fig. 1, Table 1) and they also visualize the whole extent of the lesion and its relation to other abdominal organs. By comparison, ultrasound appears less useful, as hemangiomas do not show any specific pattern. The lesion may be hypoechoic, anechoic, or hyperechoic (5). Changes on computed tomography are in general considered to be nonspecific (8-10), although the authors of a recent publication (11) feel that the TCT findings are characteristic.

#### REFERENCES

1. FELDMAN M: Hemangioma of the liver. Special reference to its association with cysts of the liver and pancreas. *Am J Clin Pathol* 29:160-162, 1958
2. ISHAK KG, RABIN L: Benign tumors of the liver. *Med Clin North Am* 59:995-1013, 1975
3. WALT AJ: Cysts and benign tumors of the liver. *Surg Clin North Am* 57:449-464, 1977
4. GOOD LI, ALAVI A, TROTMAN BW, et al: Hepatic hemangiomas: Pitfalls in scintigraphic detection. *Gastroenterology* 74:752-758, 1978
5. WIENER SN, PARULEKAR SG: Scintigraphy and ultrasonography of hepatic hemangiomas. *Radiology* 132:149-153, 1979
6. FRONT D, HARDOFF R, ISRAEL O, et al: Perfusion vascularity mismatch in liver hemangiomas. *Clin Nucl Med* 3: 212-213, 1978
7. DENARDO GL, STADALNIK RC, DENARDO SJ, et al: Hepatic scintiangiographic patterns. *Radiology* 111:135-141, 1974
8. STEPHENS DH, SHEEDY PF, HATTERY RR, et al: Computed tomography of the liver. *Am J Roentgenol* 128:579-590, 1977
9. FREENY PC, VIMONT TR, BARNETT DC: Cavernous hemangioma of the liver: ultrasonography, arteriography, and computed tomography. *Radiology* 132:143-148, 1979
10. FREENY PC: Computed tomography in the diagnostic approach to cavernous hemangioma of the liver. *Radiology* 134:554, 1980
11. JOHNSON CM, SHEEDY PF, STANSON AW, et al: Computed tomography and angiography of cavernous hemangiomas of the liver. *Radiology* 138:115-121, 1981

## 7th ANNUAL SCIENTIFIC MEETING GREATER NEW YORK CHAPTER SOCIETY OF NUCLEAR MEDICINE

October 23-25, 1981

Bellevue Stratford Hotel

Philadelphia, Pennsylvania

### Announcement and Call for Abstracts

The 7th Annual Scientific Meeting of the Greater New York Chapter of the Society of Nuclear Medicine will be held Friday through Sunday, October 23-25, 1981 at the Bellevue Stratford Hotel in Philadelphia, Pennsylvania. The Scientific Program Committee welcomes the submission of abstracts or original contributions in nuclear medicine from members and nonmembers of the Society of Nuclear Medicine. Abstracts for the Scientific Program will be published and will be available to all registrants at the meeting. Please send 6 copies with supporting data to:

Leon Malmud, M.D.  
Program Chairman, Greater N.Y. Chapter, SNM  
Div. of Nuclear Medicine  
Temple University Hospital  
3401 N. Broad St.  
Philadelphia, PA 19140

**Deadline for abstract submission is September 1, 1981.**

For information concerning registration or commercial exhibits please contact:

Mitchell H. Stromer, M.B.A.  
Greater N.Y. Chapter, SNM  
100-1 Einstein Loop  
Bronx, NY 10475  
Tel: (212) 671-1325

The program will be approved for credit toward the AMA Physicians Recognition Award under Continuing Medical Education Category I through the Society of Nuclear Medicine and for VOICE credit for technologists.