

PRELIMINARY NOTES

Cardiac Function in Patients with Prior Myocarditis

Sunil K. Das, Thomas J. Brady, James H. Thrall, and Bertram Pitt

University of Michigan School of Medicine, Ann Arbor, Michigan

Gated cardiac blood-pool imaging under rest and exercise was used to assess left-ventricular functional reserve in six asymptomatic patients with prior myocarditis and six age matched control subjects. Coronary artery disease was excluded in three of the six patients by coronary arteriography. In the remaining three, coronary artery disease was thought unlikely on the basis of history and the presence, during exercise, of a normal ECG and normal Tl-201 myocardial image. Conventional indices of resting left-ventricular function—including cardiothoracic ratio, echocardiographic left-ventricular diameter, and percentage change in minor diameter—were normal in those with prior myocarditis. The mean resting left-ventricular ejection fraction was also normal by gated blood-pool imaging, and not significantly different from that for control patients: 0.58 ± 0.05 and 0.65 ± 0.02 , respectively. Three patients with prior myocarditis had resting left-ventricular ejection fractions of less than 0.50. On exercise, the patients with prior myocarditis decreased their mean left-ventricular ejection fraction by an average of 8% compared with an increase of 15% in the control group ($p < 0.01$).

This study suggests that asymptomatic patients with prior myocarditis have left-ventricular dysfunction that may not be clinically apparent, and suggests the need for further long-term follow-up.

J Nucl Med 21: 689-693, 1980

Late sequelae of myocarditis include reduced exercise tolerance (1), valvular heart disease (2), constrictive pericarditis (3), and sudden death (4). Although chronic cardiomyopathy might be a consequence of prior myocarditis, the proof of this link has not been established (5). It is assumed that most patients recover from an episode of myocarditis and regain normal cardiac function (6). The present study was designed to evaluate left-ventricular functional reserve in asymptomatic patients with a diagnosis of prior myocarditis, using the technique of gated cardiac blood-pool imaging under exercise.

PATIENT MATERIAL

Six patients, all males, with a mean age of 40 (range 27-53 yr) were evaluated between 10 and 48 mo (mean

24 mo) after an episode of presumed myocarditis. Before their illness, all patients were healthy and had no evidence of heart disease. Prior chest radiographs, obtained for routine employment purposes, were reviewed in three of these patients; all showed normal cardiac silhouettes.

The clinical data at the time of acute illness are shown in Table 1. An upper respiratory tract infection preceded cardiac symptoms in four of the patients. Acute cardiac symptoms were noted in all six. Dyspnea was present in six of these patients, palpitation in four, and chest pain of the nonischemic type in three. Cardiomegaly, slight in one and moderate in five, was noted on the chest radiograph in all of these patients. An S3 gallop was noted in three and a pericardial friction rub was noted in one. The ECG was abnormal in all six. Frequent ectopic atrial and ventricular premature beats were noted in five patients, and three had transient atrial fibrillation. ST-segment and T-wave abnormalities were noted in three patients. There was no ECG evidence of infarction in five

Received Oct. 17, 1979; revision accepted Jan. 3, 1980.

For reprints contact: Sunil K. Das, MD, Cardiology Div., Univ. of Michigan Hospital, 1405 E. Ann St., Ann Arbor, MI 48109.

TABLE 1. CLINICAL DATA ON SIX PATIENTS WITH MYOCARDITIS AT INITIAL PRESENTATION*

Pt.	Age	Sex	Presentation	Chest radiograph	ECG	Other	Cardiac catheterization and angiogram
1	33	male	upper-respiratory illness, chest discomfort, fatigue	cardiomegaly	LBBB	slight ↑ CPK and SGOT	↑ LVEDP; moderate LV hypokinesis (LVEF 0.48); normal coronary arteriograms
2	27	male	fever, chest discomfort, dyspnea, pericardial friction rub, upper-respiratory illness	cardiomegaly; slight pulmonary congestion	PAB, PVB, transient AF	pericardial effusion on echo, normal CPK and SGOT	—
3	42	male	dyspnea, palpitation following upper-respiratory illness, S3 gallop	cardiomegaly	transient AF, PAB, PVB	normal CPK and SGOT	—
4	40	male	dyspnea, palpitation, nonexertional chest pain, S3 gallop	cardiomegaly	PVB, ST-T abnormality	normal CPK and SGOT	↑ LVEDP; moderate LV hypokinesis; normal coronary arteriograms
5	53	male	dyspnea, palpitation, fever following upper-respiratory illness, S3 gallop	cardiomegaly; pulmonary congestion	PVB	normal CPK and SGOT	—
6	40	male	dyspnea, palpitation, syncope	cardiomegaly	transient AF, PVB, ST-T abnormality	normal CPK and SGOT	normal LVEDP; slight LV hypokinesis (LVEF 0.54); normal coronary arteriograms

* Abbreviations: AF = atrial fibrillation; CPK = creatinine phosphokinase; LBBB = left bundle branch block; LV = left ventricular; LVEF = left-ventricular ejection fraction; LVEDP = left-ventricular end-diastolic pressure; PAB = premature atrial beats; Pt = patient; PVB = premature ventricular beats; S3 = third heart sound; SGOT = serum glutamic-oxaloacetic transaminase; ST-T = ST-segment and T-wave abnormality on ECG.

of the six who had no conduction abnormalities. One patient had complete left bundle branch block.

Three of the six patients were evaluated by cardiac catheterization, including coronary arteriography, within 6 wk of their illness. The coronary arteries were normal, including the patient with complete left bundle branch block. In two there was a mild elevation of left-ventricular end-diastolic pressure, and all three had slight to moderate diffuse left-ventricular hypokinesis on the

left-ventricular angiogram (Table 1). Although no viral isolation or serologic confirmation of virus involvement was obtained in any of our patients, the clinical presentation at the time of illness was consistent with the diagnosis of myocarditis (7). All of the patients had returned to their occupations and were asymptomatic at the time of this study. Thallium-201 scintigraphy in four of the six patients tested—including the three who did not undergo coronary arteriography during their acute

illness—showed no abnormalities of tracer uptake at rest or under adequate myocardial stress. The stress ECG showed no ischemic ST segment changes in these patients. The follow-up evaluation included chest radiograph, resting ECG, resting echocardiogram, and rest and exercise multiple-gated cardiac blood-pool imaging.

METHOD

For the radionuclide studies, patients received 25 mCi of Tc-99m-tagged red blood cells. Images were obtained at 40° left anterior oblique position, using a scintillation camera with parallel-hole, low-energy collimator (8). Data collection was computer controlled in a multiple-acquisition format providing 14 synchronized frames per cardiac cycle based on the R wave of the ECG (9). A restraining harness was used to prevent significant motion of the thorax during exercise. Exercise was initiated at a load of 25 watts until a pedaling rate of 60 revolutions per minute was achieved. The load was then progressively increased while maintaining the 60-rpm pedaling rate until effort became limited by fatigue. Imaging during peak exercise was repeated in the manner described above but with the frame rate adjusted for the then shorter R-R interval. During exercise, the ECG, heart rate, and blood pressure were constantly monitored with a physician in attendance. Data were analyzed by previously described techniques (10,11). A semi-automated edge-detection algorithm was used to outline the left ventricle in each frame of the baseline rest and exercise studies. These contours were used to define left-ventricular regions of interest for each frame. A background region was constructed 1.2 cm outside the left ventricle in a 60° arc adjacent to the lateral wall. Background-subtracted left-ventricular time-activity curves were generated to determine net end-diastolic and end-systolic counts (EDC and ESC). The left-ventricular ejection fraction (LVEF) was calculated by the formula:

$$\text{LVEF} = \frac{\text{EDC} - \text{ESC}}{\text{EDC}}$$

A resting left-ventricular ejection fraction of less than 0.50, or a decrease in left-ventricular ejection fraction, or an increase of less than 0.05 with exercise, is considered an abnormal response in our laboratory. Regional wall motion was analyzed and compared with the resting and exercise studies by viewing the multiple-frame studies in continuous closed-loop cinematic display (12). None of the patients were on cardiac drugs known to influence ventricular inotropy. Six male subjects, age range 29–50 yr, (mean age 41) all without clinical evidence of cardiovascular disease, were also evaluated similarly for comparison.

STATISTICS

The mean LVEFs during rest and exercise were computed in each group and compared for determination of significance using Student's t-test.

RESULTS

Results of the follow-up evaluation are shown in Table 2. Cardiac examination was normal, except in the one patient who had abnormal splitting of the second sound consistent with his complete left bundle branch block. The ECGs were normal except in this patient. Heart size, as assessed by the cardiothoracic ratio, was normal in all. The left-ventricular internal diameter and percentage change in minor diameter, assessed by M-mode echocardiography, were also normal in all. The results of the multiple-gated cardiac blood-pool imaging studies are shown in Fig. 1 for the patients and controls; results are expressed as mean LVEF \pm s.e.m. The resting mean LVEF for the six patients with prior myocarditis was 0.58 ± 0.05 compared with 0.65 ± 0.02 in the control group. This difference was not significant ($p > 0.2$). Three of the six patients with prior myocarditis had

TABLE 2. FOLLOW-UP DATA 10 TO 48 MO AFTER MYOCARDITIS (N = 6)*

Pt.	Symptoms rest and exercise	Exam	CT ratio	ECG	Echocardiogram		MUGA EF		Interval from myocarditis to study (mo)
					LVID (cm)	% Δ minor axis	rest	exercise	
1	none	abn S2	normal	LBBB	5.6	25	0.49	0.53	22
2	none	nl	normal	nl	3.8	42	0.68	0.62	10
3	none	nl	normal	nl	5.2	35	0.43	0.32	20
4	none	nl	normal	nl	4.8	25	0.48	0.50	24
5	none	nl	normal	nl	4.6	33	0.71	0.59	48
6	none	nl	normal	nl	5.4	30	0.68	0.71	18

* Abbreviations: abn = abnormal; EF = ejection fraction; LBBB = left bundle branch block; LVID = left-ventricular internal diameter; MUGA = multiple-gated acquisition; nl = normal; Pt = patient; S2 = second heart sound.

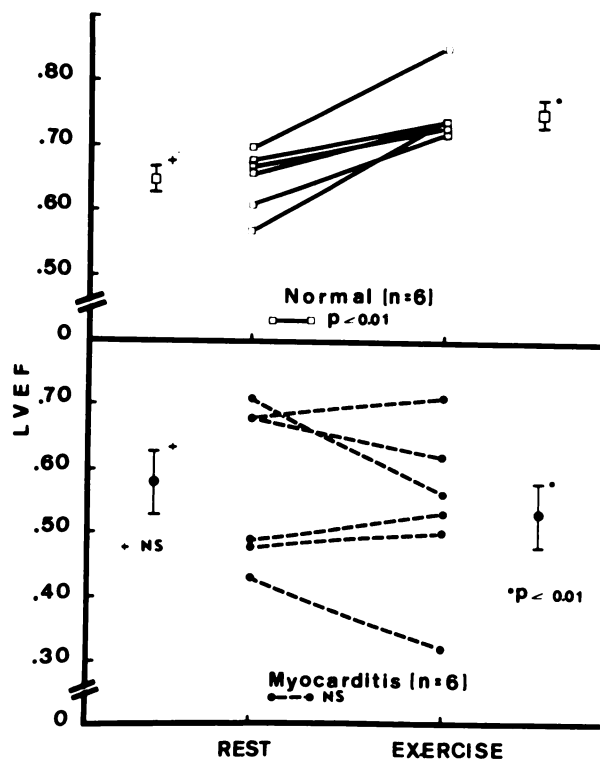


FIG. 1. Left-ventricular ejection fraction at rest and under exercise, by cardiac blood-pool imaging, in normal subjects and in asymptomatic patients with prior myocarditis.

abnormal resting LVEF less than 0.50 (Table 2). The mean LVEF during exercise in the patients with prior myocarditis was 0.53 ± 0.05 , compared with 0.75 ± 0.02 in the control group. This difference was significant ($p < 0.01$). Three patients with prior myocarditis showed decline in the LVEF with exercise and three showed only slight increase (less than 0.05); this resulted in a mean decline of 8% under exercise, as against a rise of 15% in the normal controls. No regional wall-motion abnormalities were noted either at rest or during exercise in any subject.

DISCUSSION

Although the diagnosis of myocarditis was not confirmed by viral or bacterial studies in our patients, the clinical presentation at the time of acute illness was consistent with the diagnosis (7). Coronary artery disease as a cause was excluded in three of the patients by coronary arteriography. Significant coronary artery disease was unlikely in the other three on the basis of history and the presence of a normal exercise ECG and rest and exercise myocardial Tl-201 uptake. By combining Tl-201 scintigraphic data during rest and exercise with electrocardiographic ST-segment responses to exercise, over 90% of patients with significant coronary artery disease may be identified, making it highly unlikely that coronary artery disease could explain the re-

sults of exercise blood-pool imaging in the present study (13). Furthermore, in contrast to patients with significant ischemic heart disease, there were no wall-motion abnormalities detected on our patients' exercise imaging.

Since patients with a history of prior myocarditis are often asymptomatic and have normal resting left-ventricular function, myocarditis has not been felt to result in long-term cardiac dysfunction (6,14). Resting indices of left-ventricular function, however, provide only a limited assessment of this function. Dynamic exercise testing improves the likelihood of detecting abnormal left-ventricular function. This fact has been recognized in patients with ischemic heart disease in whom LVEF is normal at rest but during exercise either fails to increase normally or actually decreases (10). Similar results have been reported in patients with valvular heart disease (15). Left-ventricular function determined by gated cardiac blood-pool imaging has recently been shown to correlate well with values determined during contrast left ventriculography both at rest and following exercise (16).

It has been postulated that in some instances myocarditis may result in a chronic cardiomyopathy (5). Although direct evidence for this postulate is lacking, results of the present investigation suggest that further long-term follow-up of postmyocarditis patients, using sensitive measures of ventricular function, is needed. It is conceivable that the initial episode of myocarditis may damage myocellular constituents in such a way as to incite a progressive immunological process and further cardiac dysfunction (17).

The findings of the present study in asymptomatic postmyocarditis patients with normal to mildly abnormal resting left-ventricular function but impaired left-ventricular functional reserve, suggest that these patients should be followed carefully to determine whether their impaired functional reserve is predictive of subsequent cardiomyopathy or other cardiac complications. Finally, the present study also points out that failure to increase LVEF during exercise is not specific for ischemic heart disease but may result from a variety of causes resulting in myocardial damage, including prior myocarditis.

REFERENCES

1. BENGSSON E, LAMBERGER B: Five-year follow-up study of cases suggestive of acute myocarditis. *Am Heart J* 72: 751-763, 1966
2. BURCH GE, SUN SC, COLCOLOUGH HL, et al: Coxsackie B viral myocarditis and valvulitis identified in routine autopsy specimens by immunofluorescent techniques. *Am Heart J* 74:13-23, 1967
3. WOLFF L, GRUNFELD O: Pericarditis. *N Engl J Med* 268: 419-426, 1963
4. GORMSEN H: Sudden, unexplained death due to myocarditis. *Acta Pathol Microbiol Scand Suppl* 105:30-48, 1955
5. SAINANI GS, KROMPOTIC E, SLODKI SJ: Adult heart dis-

- ease due to the coxsackie virus B infection. *Medicine* 47: 133-147, 1968
6. GERZEN P, GRANATH A, HOLMGREN B, et al: Acute myocarditis: A follow-up study. *Br Heart J* 34:575-583, 1972
 7. ABELMANN WH: Virus and the heart. *Circulation* 44: 950-956, 1971
 8. PAVEL DG, ZIMMER AM, PATTERSON VN: In vivo labeling of red blood cells with ^{99m}Tc : New approach to blood pool visualization. *J Nucl Med* 18:305-308, 1977
 9. STRAUSS HW, SINGLETON R, BUROW R, et al: Multiple gated acquisition (MUGA): An improved noninvasive technique for evaluation of regional wall motion (RWM) and left ventricular function (LVF). *Am J Cardiol* 39:284, 1977 (abst)
 10. BORER JS, BACHARACH SL, GREEN MV, et al: Real-time radionuclide cineangiography in the noninvasive evaluation of global and regional left ventricular function at rest and during exercise in patients with coronary-artery disease. *N Engl J Med* 296:839-844, 1977
 11. BUROW RD, STRAUSS HW, SINGLETON R, et al: Analysis of left ventricular function from multiple gated acquisition cardiac blood pool imaging: Comparison to contrast angiography. *Circulation* 56:1024-1028, 1977
 12. GREEN MV, BACHARACH SL, DOUGLAS MA, et al: The measurement of left ventricular function and the detection of wall motion abnormalities with high temporal resolution ECG gated scintigraphic angiocardiology. *IEEE Trans Nucl Sci* 23:1257-1263, 1976
 13. BAILEY IK, GRIFFITH LSC, ROULEAU J, et al: Thallium-201 myocardial perfusion imaging at rest and during exercise. Comparative sensitivity to electrocardiography in coronary artery disease. *Circulation* 55:79-87, 1977
 14. LEVI GF, PROTO C, QUADRI A, et al: Coxsackie virus heart disease and cardiomyopathy. *Am Heart J* 93:419-421, 1977
 15. BORER JS, BACHARACH SL, GREEN MV, et al: Exercise-induced left ventricular dysfunction in symptomatic and asymptomatic patients with severe aortic regurgitation assessed by radionuclide angiography. *Am J Cardiol* 39:284, 1977 (abst)
 16. WALTON JA, LO KS, BRYMER JF, et al: Exercise ventriculography: Assessment of the functional significance of coronary artery lesions. *Circulation* 58:11-122, 1978 (abst)
 17. SANDERS V: Viral myocarditis. *Am Heart J* 66:707-713, 1963

THE HERITAGE OF NUCLEAR MEDICINE

The Heritage of Nuclear Medicine is a compendium of important scientific papers tracing the history of nuclear medicine from its foundations in the physical sciences through its development as a branch of medicine.

With papers reproduced in facsimile form (and translated into English where necessary). ***The Heritage of Nuclear Medicine*** covers the period from 1886 to 1959. Included are seminal papers by Crookes, Becquerel, Hevesy, Fermi, Anger, Cassen, Berson and Yalow, and others. A lively historical essay by Marshall Brucer outlines the development of nuclear medicine and puts the volume's 31 scientific papers into perspective.

Created to commemorate the 25th anniversary of the Society of Nuclear Medicine, ***The Heritage of Nuclear Medicine***, is in large format and printed on heavyweight, cream vellum paper. Copies may be ordered from:

Book Order Department
Society of Nuclear Medicine
475 Park Avenue South
New York, NY 10016

A check (or purchase order) for \$14.50 must accompany all orders. (Please add \$2.50 for postage and handling.)