

LETTERS TO THE EDITOR

Myocardial Imaging with Tl-201

The beautiful series of experiments described by Narahara et al. (1) serve to point out one of the deficiencies of instrument evaluation that has become part of the accepted folklore of nuclear medicine—namely, that the relative performance of two imaging instruments can be quantitated by comparing MTFs obtained from the responses of the devices to line sources with or without scattering media, multiplied by some power function of their respective sensitivities.

The effects of scatter are thus grossly underestimated. It is self-evident that the image formed by scattered photons should depend on activity distribution and tissue density, two parameters that are highly structured. In spite of this, the analysis of the contributions from scatter to image quality are based on the assumption that "scattered radiation is presumed to represent background and contains no structural information" (2). Other authors in the field have implicitly or explicitly made the same assumption, which is clearly negated by the data presented by Narahara and co-workers. Performances indices based on simplistic assumptions and corroborated with simple experimental configurations cannot be used to predict image quality under realistic imaging situations, where scatter contributes a false image that is dependent on the activity distribution (within and without the field of view) and on tissue density. This scatter image is pure noise, but is structured with frequency and spatial components that overlap those of interest. While the assumption described above may be adequate to compare two almost identical instruments (e.g. two cameras with energy resolution of 15% and 17% FWHM at 140 keV), it will yield results that grossly underestimate the advantages that elimination of scatter through the use of detectors with enhanced energy resolution—e.g., germanium with 1–3% FWHM energy resolution at 140 keV—can bring to clinical gamma imaging.

LEON KAUFMAN
ROBERT S. HATTNER
University of California
San Francisco, California

1. NARAHARA KA, HAMILTON GW, WILLIAMS DL, et al: Myocardial imaging with thallium-201: An experimental model for analysis of the true myocardial and background image components. *J Nucl Med* 18: 781–786, 1977

2. ATKINS FD, BECK RN, HOFFER PB, et al: Dependence of optimum baseline setting on scatter fraction and detector response function. *Medical Radionuclide Imaging*, IAEA-SM-210/76 I: 101–118, 1977

The Role of Ga-67 Citrate Imaging and Diagnostic Ultrasound in Patients with Suspected Abdominal Abscesses

The experience of Kumar et al., comparing abscess detection with Ga-67 and ultrasound (1) (*J Nucl Med* 18: 534–537, 1977) agrees generally with ours. We would like to point out, however, that there are regional differences that can make one technique superior to the other, depending upon the area to be searched.

Due to normal uptake of Ga-67 by the liver, peri-hepatic abscesses—particularly subdiaphragmatic—are difficult to detect utilizing this modality. In ultrasonography on the other hand, the presence of the liver is quite useful, for it displaces bowel that might otherwise block sound transmission due to its gas content, and thus renders this area ideal for ultrasonic search. Similarly, in the pelvis, the presence of a filled bladder allows detailed ultrasonic exploration. It is in the area in between, where the presence of bowel gas seriously interferes with ultrasonography, that Ga-67 scanning may be superior, although large bowel activity often poses difficulties in interpretation here.

In practice, of course, one often does not know in advance the most likely area of involvement. Nevertheless, it is worthwhile bearing these divisions in mind.

M. A. WINSTON, M.D.
VA Wadsworth Hospital Center
Los Angeles, California

REFERENCE

1. KUMAR B, ALDERSON P, GEISSE G: The role of Ga-67 citrate imaging and diagnostic ultrasound in patients with suspected abdominal abscesses. *J Nucl Med* 18: 534–537, 1977

Reply

In regard to the Letter to the Editor from Dr. M. A. Winston, I generally agree with his comments. I would like to point out, however, that in most patients referred with the clinical suspicion of an abdominal abscess, there is some clinical symptomatology or previous surgery in one specific area that makes one technique more advisable than the other.

In those cases where there is not a suspicious area, we should keep in mind the difference as pointed out by Dr. Winston.

GUILLERMO GEISSE
Mallinckrodt Institute of Radiology
Washington University Medical School
St. Louis, Missouri

Bone Scanning in Neonatal Subcutaneous Fat Necrosis

Neonatal subcutaneous fat necrosis is a benign self-limiting disorder. The breakdown of fat results in the accumulation of crystals of fatty acids in the subcutaneous fat spaces of the infant. The fatty acids provoke a foreign-body reaction with a subsequent fibroblastic proliferation, deposition of calcium salts, and formation of bone. The roentgenographic manifestations are striking and consist of punctate aggregates of calcium in the subcutaneous fat. As a rule, the bone formed is masked by the extensive soft-tissue calcifications and is not visible on roentgenograms.

The purpose of this report is to illustrate and discuss the possible mechanisms for the extraskelatal accumulation of

a bone-seeking radiopharmaceutical in an infant with extensive subcutaneous fat necrosis.

A term infant was delivered by low forceps following a normal 7-hr labor. Hypotonia, weak cry, absent Moro reflex, and a left facial palsy were noted at birth. Because of a heart murmur and an enlarged heart, the infant was transferred to our hospital at 2 days of age for cardiac evaluation.

The admission physical examination revealed ecchymoses of the face and scalp, with large areas of cutaneous thickening and hyperemia over both maxillae. The heart rate was 150/minute and the respiratory rate 80/minute. The blood pressure in the right arm was 150/40 mm Hg and neither femoral pulse was palpable. Cardiac catheterization performed at 2 weeks of age revealed a coarctation of the aorta and a small patent ductus arteriosus.

A serum calcium of 7.0 mg% (normal = 8–10.5 mg%) on admission prompted the administration of supplemental calcium by gavage. Within 3 days the serum calcium rose progressively to 8.9 mg% and the supplemental calcium was discontinued. All subsequent levels of serum calcium remained above 9 mg%.

Chest roentgenograms initially revealed cardiac enlargement and mild passive congestion. Hydralazine, digitalis, and diuretics evoked a satisfactory clinical response, and subsequent chest roentgenograms revealed only mild cardiac enlargement. There were no subcutaneous calcifications. The child was discharged at 3 weeks of age.

At 7 weeks of age a chest roentgenogram revealed exten-

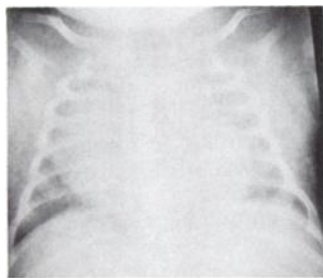


FIG. 1. Note diffuse calcium deposits in subcutaneous fat layers.

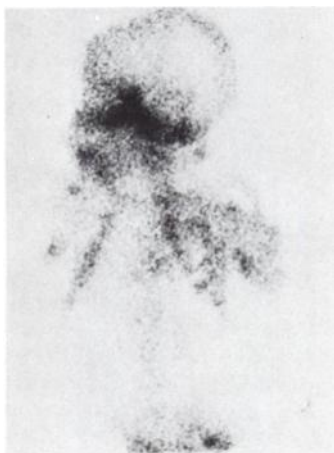

FIG. 2. Anterior scintiphoto with Tc-99m pyrophosphate 4 hr following injection. Extensive uptake in soft tissues masks normal skeletal uptake.

sive calcifications in the subcutaneous fat of the trunk and extremities (Fig. 1). A scintigram was made 4 hr after i.v. administration of 2.7 mCi of Tc-99m pyrophosphate. It showed extensive uptake in the soft tissues (Fig. 2).

Serial roentgenograms revealed a gradual resolution of the soft-tissue calcifications, and when the infant was 6 months of age, almost complete reabsorption of the calcium had occurred.

Neonatal subcutaneous fat necrosis is an uncommon disorder affecting otherwise healthy infants. Although the exact cause is not known, trauma and/or asphyxia have been implicated as associated factors in the production of the fat necrosis (1). The cheeks, shoulders, and thighs are the sites most frequently affected. The involved areas are ligneous and hard on palpation and there may be a red or purple discoloration of the overlying skin. Clinically the course of the disease is benign and usually there are no systemic symptoms. As a rule, serum calcium levels are normal, though a transient hypocalcemia may be noted. Gradual resolution of the hard cutaneous lesions occurs over a period of several months (2).

Roentgenographically the lesions are seen as confluent calcified plaques just below the dermis, and correspond in location to the areas of discolored skin.

Histologic examination of the lesions reveals a typical foreign-body reaction, with lymphocytes and giant cells surrounding fatty-acid crystals. As a result of the soft-tissue injury, granulation tissue (fibroblasts and capillaries) is present; in addition, calcium deposits and bone formation are frequently noted.

The accumulation of the pyrophosphate tracer in the soft tissues of an infant with subcutaneous fat necrosis may be readily explained by a consideration of the properties of the phosphate complex and the formation of bone in the lesions. Recent studies (4,5) suggest that pyrophosphate exhibits a preferential affinity for the multiple unbound side chains of newly formed collagen, and secondarily for the interface of the hydroxyapatite crystal. The multipotential nature of granulation tissue leads to the formation of osteoblasts, which produce osteoid (collagen). Dystrophic calcification induces the formation of hydroxyapatite crystals. The bone that is eventually formed in the soft tissues may contain all of the elements of mature bone, including hematopoietic elements (3). Thus because of the active formation of bone in the soft tissues, the delayed bone image will reveal increased uptake of Tc-99m pyrophosphate in the soft tissue. It is therefore conceivable that the bone scan may be positive before soft-tissue calcifications become evident radiographically.

JONATHAN L. WILLIAMS
MARIE A. CAPITANIO
H. THEODORE HARCKE, JR.
St. Christopher's Hospital for Children
Philadelphia, Pennsylvania

REFERENCES

1. MARKS MB: Subcutaneous adipose derangements of the newborn. *Am J Dis Child* 104: 44–52, 1962
2. SHACKELFORD GD, BARTON LL, MCALISTER WH: Calcified subcutaneous fat necrosis in infancy. *J Can Assoc Radiol* 26: 203–207, 1975
3. ROBBINS SL: *Pathologic Basis of Disease* 4th edition. Philadelphia, WB Saunders Co., 1974, pp 51–52
4. ROSENTHALL L, KAYE M: Technetium-99m-pyrophosphate kinetics and imaging in metabolic bone disease. *J Nucl Med* 16: 33–39, 1975

5. KAYE M, SILVERTON S, ROSENTHALL L: Technetium-99m-pyrophosphate: Studies in vivo and in vitro. *J Nucl Med* 16: 40-45, 1975

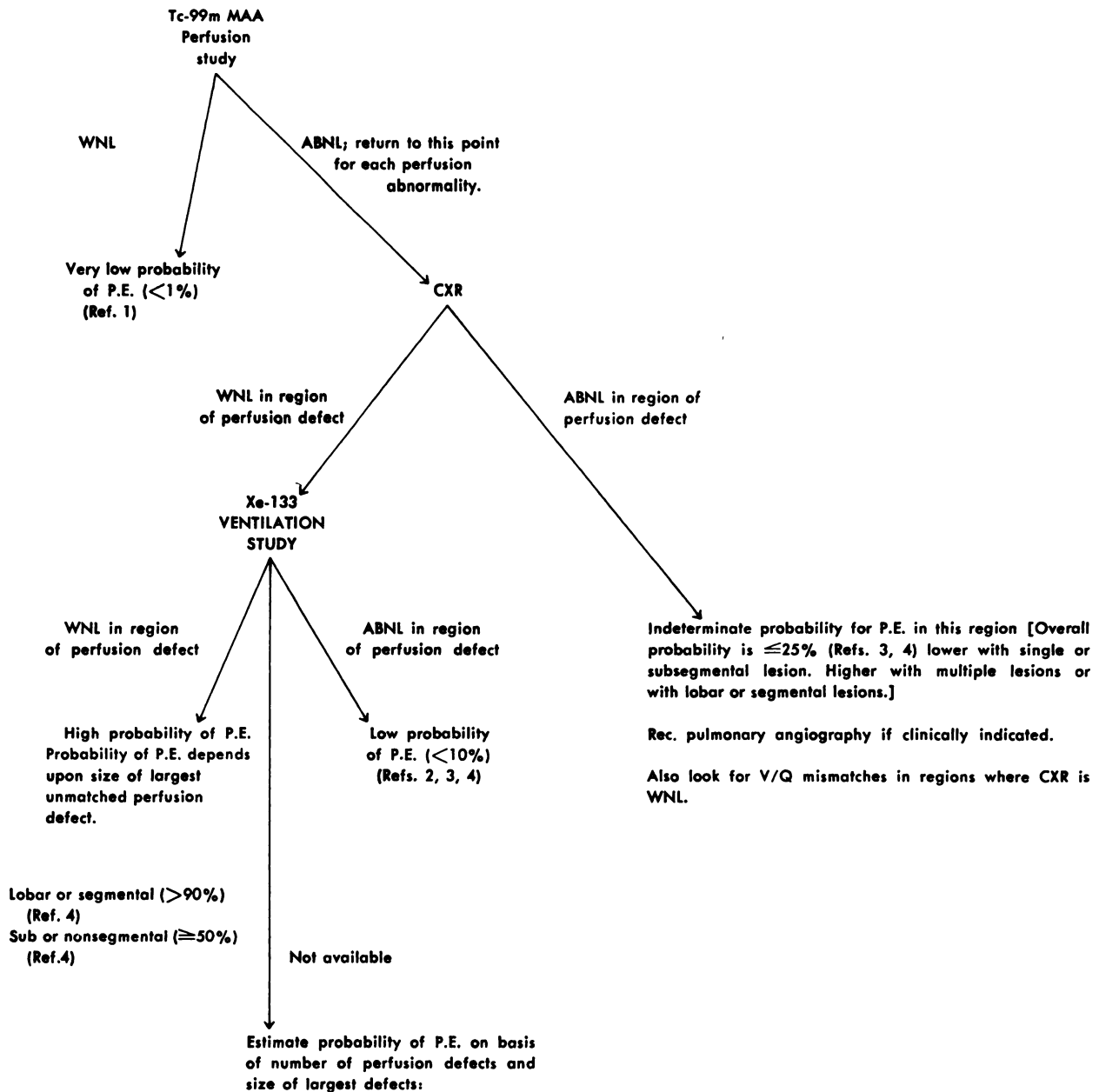
Interpreting Lung Studies Obtained in Patients with Suspected Pulmonary Embolism

In response to a recent article by Robin (1), we have decided to re-evaluate our method of interpreting lung

studies obtained in patients with suspected pulmonary embolism. After reviewing the recent literature, we have developed a flowchart as an aid in interpretation (see illustration). This flowchart is currently being used in our laboratory and we feel that it might be of value to the readers of the *Journal*. Please note that although evaluation of the perfusion study is the first step in the overall interpretation process, whenever possible we precede the perfusion study with a ventilation study.

In reporting these studies to the referring physician, we

FLOWCHART



January 3, 1978

Paul Weiss, M.D.
John Seder, M.D.

Multiple Defects (Ref. 4)	
Lobar	80%
Segmental	50%
Subseg	10%

Single Defect (Ref. 4)
50%
~25%
<10%