

Reply

This is in response to the letter to the Editor from D. P. Shreiner (1).

The subject of our article (2) was to demonstrate that the upright view, when used in hepatic scans, improves resolution. One assumes that if resolution is improved, indeed, lesion detection would be improved. The findings of improved resolution in scans of those patients who are able to stand have been observed at our institution, as well as at others, for several years, but have not previously been analyzed.

There was a figure demonstrating computer analysis of a scan with hepatic metastases. When a specific lesion was analyzed, it was delineated more clearly. For the purposes of our article, focal defects were chosen for analysis, since they were easiest to identify.

We agree that the scans suffer in reproduction, particularly when they reach the third generation. We agree with Dr. Shreiner that we did not attempt, in our article, to conduct a large-scale study of patients with various hepatic abnormalities, since autopsy or biopsy proof is, at best, difficult to come by. To date, there have been very few studies of hepatic metastases that are of acceptable quality. One of the best and most recent studies was published recently in this Journal by Drum, et al. (3); however, we were not prepared to enter into such an extensive effort at this time. We hope that Dr. Shreiner will try utilizing such a simple and inexpensive maneuver to see the effect, and perhaps, for the benefit of his patients, as well.

FRED A. METTLER, JR.
Cancer Research and Treatment Center
Albuquerque, New Mexico

REFERENCES

1. SHREINER DP: Visualization of hepatic lesions with upright views. *J Nucl Med*: in press
2. METTLER JR FA, SHEA JR WH, GUIBERTEAU MJ: Improvement in visualization of hepatic lesions with upright views. *J Nucl Med* 18: 1128-1130, 1977
3. DRUM DE, BEARD JM: Scintigraphic criteria for hepatic metastases from cancer of the colon and breast. *J Nucl Med* 17: 677-680, 1976

Improvement in Visualization of Hepatic Lesions with Upright Views

In their Technical Note (1), Mettler et al. state: "Comparison of gray-scale ultrasonography with routine radionuclide hepatic scans indicates the superiority of ultrasound (12). This may not be true when standing radionuclide scans are routinely performed."

Our study (2), to which Mettler et al. refer, indeed stated that in areas accessible to the transducer sonography was superior to radionuclide imaging for the resolution of small, deep lesions. We defined this superiority strictly in terms of such resolution and not in overall diagnostic ability. We reached our conclusions in the study, as in our routine clinical work, by examining all patients able to stand in both the supine and upright positions.

ZACHARY D. GROSSMAN, M.D.
BRIAN W. WISTOW, M.D.
State University of New York
Upstate Medical Center
Syracuse, New York

REFERENCES

1. METTLER FA, SHEA WH, GUIBERTEAU MJ, et al: Improvement in visualization of hepatic lesions with upright views. *J Nucl Med* 18: 1128-1130, 1977
2. GROSSMAN ZD, WISTOW BW, BRYAN PJ, et al: Radionuclide imaging, computed tomography, and gray-scale ultrasonography of the liver: A comparative study. *J Nucl Med* 18: 327-332, 1977

Myocardial Imaging with Tc-99m Pyrophosphate in Patients with Adriamycin for Neoplasia

I have read the article of Chacko et al. (1) with great interest. It is encouraging to note that serious effort is being made to use myocardial imaging techniques to understand cardiac disorders other than coronary-artery disease. Their association of Tc-99m pyrophosphate activity in the cardiac region with adriamycin-induced cardiac damage however, is a bit premature. The problem of cardiotoxicity as a long-term complication of adriamycin therapy is well known. Several diagnostic procedures that promise to be sensitive for early detection of cardiac toxicity—such as systolic time-interval measurement (2) or echography (3)—may also be too sensitive, and result in unnecessary withdrawal of a beneficial drug from the therapeutic regimen of a cancer patient (4). The possibility that prior radiotherapy to the chest may be an additional factor in causing cardiac uptake of Tc-99m pyrophosphate must be considered also. We have reported a high incidence of cardiac uptake of Tc-99m pyrophosphate in patients with prior history of therapeutic chest irradiation as compared with a control group of unirradiated patients (5). The majority of their patients who show cardiac uptake of Tc-99m pyrophosphate also had prior cardiac irradiation. In an effort to relate cardiac uptake to adriamycin administration alone, an analysis of a patient group that has had no chest irradiation would be very interesting. Comparison with sensitive techniques such as serial EKG, systolic time interval, echocardiography, based on experimental confirmation, will help explain the dynamic processes encountered in chemotherapy.

JAGMEET S. SOIN
Milwaukee County Medical Complex
Milwaukee, Wisconsin

REFERENCES

1. CHACKO AK, GORDON DH, BENNETT JM, et al: Myocardial imaging with Tc-99m pyrophosphate in patients with adriamycin for neoplasia. *J Nucl Med* 18: 680-683, 1977
2. RINEHART JJ, LEWIS RP, BALCERZAK SP: Adriamycin cardiotoxicity in man. *Annals of Int Med* 81: 475-478, 1974
3. JONES SE, EWY GA, GROVE BM: Echocardiographic detection of adriamycin heart disease. *Proc of Am Soc Clin Oncol* 16: 228, 1975 (Abst)
4. MINOW RA, GOTTLIEB JA, FRAZIN L, et al: Adriamycin cardiotoxicity. *Annals of Int Med* 82: 855-857, 1975
5. SOIN JS, COX JD, YOUKER JE, et al: Cardiac localization of ^{99m}Tc-(Sn)-pyrophosphate following irradiation of the chest. *Radiology* 124: 165-168, 1977
6. SOIN JS: Myocardial localization of Tc-99m pyrophosphate. *J Nucl Med* 17: 853, 1976

Reply

In our article (1) we described our technique of using Tc-99m pyrophosphate in patients who stood a risk of de-

veloping adriamycin cardiotoxicity. Since publication of that paper, we have continued studying an entire series of patients, including those described in our article. We have used several methods of diagnosis, including echoradiography, technetium pyrophosphate imaging, electrocardiography, enzyme studies, conventional chest radiographs, and clinical evaluation. We hope to be able to publish this work in the near future. We also hope at that time to have completed our experimental work in support of our clinical data.

In answer to Dr. Soin's contention that the majority of patients showing cardiac uptake of Tc-99m pyrophosphate had prior chest irradiation, we can only say that this abnormality was to be expected. Patients with prior irradiation do stand a higher chance of developing cardiac toxicity from adriamycin than patients without (2,3).

MAJ. ANNA K. CHACKO, MC, USA
Nuclear Medicine Service
Tripler AMC, Hawaii

REFERENCES

1. CHACKO AK, GORDON DH, BENNETT JM, et al: Myocardial imaging with Tc-99m pyrophosphate in patients on adriamycin treatment for neoplasia. *J Nucl Med* 18: 680-683, 1977
2. MINOW RA, BENJAMIN RS, GOTTLIEB JA: Adriamycin cardiomyopathy—an overview with determination of risk factors. *Can Chemother Rep* 6: 192-201, 1975, pt 3
3. FAJARDO LF, ELTRINGHAM JR, STEWART JR: Combined cardiotoxicity of adriamycin and x-radiation. *Lab Invest* 34: 86-96, 1976

Modification of a Gated Acquisition Test Device

It has been reported recently that a Tc-99m source mounted on a modified, 78-rpm, phonograph turntable can be used to evaluate and study gated-acquisition techniques (1). The suggested modification of the turntable includes a simple pulse-forming circuit that is triggered by a micro-switch mounted to the edge of the turntable platter.

We describe here a simple approach that has enabled us to evaluate gated-acquisition programs without the necessity of building a pulse-forming network. The device uses only an existing turntable and tone arm. We have found that the output of an inexpensive phonograph cartridge mimics a QRS complex and triggers a commercially available gating device, thereby obviating the need for a pulse-forming circuit. The arm of the phonograph is suspended over the turntable platter and a 21-gauge needle is fixed to the surface of the platter at an angle that minimally disturbs the phonograph needle once for each revolution. The gating device is connected to the output signal plug of the turntable. A Tc-99m source is placed on a turntable at the same radial as the 21-gauge needle, thus fixing in time the relationship between the "R wave" and the geometric position of the source.

Since we are continuously upgrading our existing programs for gated acquisition, this device has enabled us to perform simple tests of acquisition and processing without exposing patients to prolonged imaging time.

JOHN P. WEXLER
STEPHEN SCHARF
ARI RABINOWITZ
Albert Einstein College of Medicine
Bronx, New York

REFERENCE

1. SILVERSTEIN EA, TURNER D, FORDHAM EW, et al: Cardiac blood pool imaging over the complete cardiac cycle with a multifformat imager. *J Nucl Med* 18: 159-162, 1977

Clinical Assessment of the Importance of the Quantity of Tin in Commercial Bone Imaging Kits

Technetium-99m-labeled phosphates, especially the pyrophosphate, have become the popular agent for skeletal and cardiac imaging (1,2). To achieve firm technetium-to-phosphate binding, the valence state of technetium (pertechnetate) is reduced from seven to four by a reducing agent. In the case of Tc-99m, tin in the form of stannous chloride accomplishes this. Too little tin in the reaction vial results in an excess of free pertechnetate, and too much tin may produce colloid. It is important to note that excess tin would, upon injection, coat the red blood cells and the choroid plexus, which would accumulate increased amounts of Tc-99m pertechnetate used subsequently for brain imaging. False-positive brain scans resulting from previous bone scans have been reported (3,4). Therefore, it is crucial that the quantity of tin in a bone-imaging reagent be restricted to the absolute minimum necessary for firm labeling. At present several commercial firms supply pyrophosphate kits for bone imaging, with varying quantities of tin as the reducing agent. In the two kits approved by the FDA for clinical use, different amounts of pyrophosphate and tin are present. In the kit made by Mallinckrodt Nuclear (Technescan-pyp kit), the pyrophosphate/Sn ratio (by weight) is 3.5 (a low-ratio agent); in the kit made by Squibb (Phosphotec), the ratio is 20 (high-ratio agent). The present study was undertaken to compare the clinical significance of the varying quantities of tin on the biologic behavior, in vivo and in vitro stability of the labeled agents.

Nine patients ranging in age from 30 to 75 yr (mean, 53), for whom a bone-imaging study was requested, were chosen. The purpose of the investigation and the procedure were

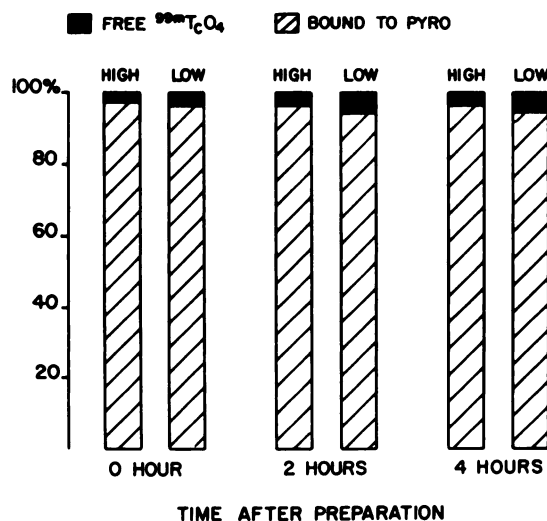


FIG. 1. Results of thin-layer radiochromatographic analysis of high- and low-ratio pyrophosphate/Sn imaging agents labeled with Tc-99m, showing identical binding efficiency and 4-hr in vitro stability.