

Demonstration of Ga-67 Localization in Human Placenta

Robert A. Newman, James G. Gallagher, John P. Clements, and Irwin H. Krakoff

Vermont Regional Cancer Center and University of Vermont, Burlington, Vermont

Gallium-67 uptake was noted in the mid-pelvic uterine area of a 19-week-pregnant female. Lateral and oblique Ga-67 scans revealed an anterior location of radioactivity that correlated with the position of the placenta as determined by ultrasonic technique.

J Nucl Med 19: 504-506, 1978

In nonmalignant conditions Ga-67 is normally concentrated within the liver and spleen, whereas other intra-abdominal structures are not normally seen (1). Experimental comparisons of various radionuclides, including Ga-67, as agents for the study of the placenta have been made both in rabbits (2,3) and in primates (2). These studies have demonstrated that marked concentration of Ga-67 can occur not only in placental tissues but also in blastocysts, sites of embryo implantation (3), and in fetal tissue (4). The relevance of these studies to gallium concentration by human placental and other reproductive tissues is difficult to assess due to the difference in structure between the human placenta and other primate placentas (5,6), and to the lack of Ga-67 imaging data in pregnant humans. However, agents that can be shown to inhibit tumor growth must be considered as potential teratogens. To our knowledge this is the first reported case of Ga-67 localization in the human placenta.

CASE REPORT

The patient is a 15-year-old girl who was admitted

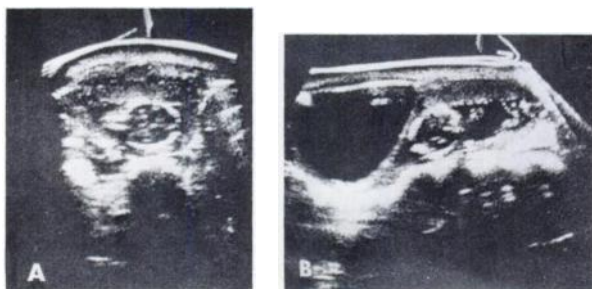


FIG. 1. Representative ultrasonic scans demonstrating anterior implantation of placenta. (A) Transverse scan, 6 cm below umbilicus. (B) Longitudinal scan, 1 cm to the left of midline. Singleton fetus in vertex presentation and filled urinary bladder are also shown. Both scans were obtained with patient supine.

to the otolaryngology service for acute respiratory distress secondary to a large necrotic oropharyngeal mass that had been treated as a peritonsillar abscess for several weeks at another hospital. The mass had occluded both nasopharynx and oropharynx to the point where emergency tracheostomy was required. Biopsy of the mass revealed a poorly differentiated lymphocytic lymphoma. There was no evidence of lymphoma elsewhere. Initial evaluation revealed a gravid uterus consistent with 19 weeks of gestation. Abdominal ultrasonic examination revealed a single fetus in vertex presentation with an anterior placenta (Fig. 1). As part of the staging workup for malignant lymphoma, gallium scans were performed 72 and 96 hr after the i.v. injection of 3 mCi of Ga-67 citrate.

Scans were made with a gamma camera and a whole-body rectilinear scanner. As seen in Fig. 2, there was intense uptake of the tracer by the tumor in the nasopharyngeal area, as well as a marked persistent concentration in the region of the uterus. The 72-hr scan showed evidence of increased uptake in the colon, but this largely disappeared on the 96-hr scan. Detailed examination of the location of Ga-67 in anterior, lateral, and oblique scintiphotos (Fig. 3) showed that the uterine area of tracer concentration was anteriorly located. By ultrasound the patient's placenta was also found to lie anteriorly (Fig. 1), and thus the tissue showing marked concentration of Ga-67 in Figs. 2 and 3 is believed to be the placenta.

DISCUSSION

Factors that affect the gross distribution of Ga-67

Received Oct. 19, 1977; revision accepted Dec. 13, 1977.

For reprints contact: Robert A. Newman, Dept. of Pharmacology, College of Medicine, University of Vermont, Given Bldg., Burlington, VT 05401.

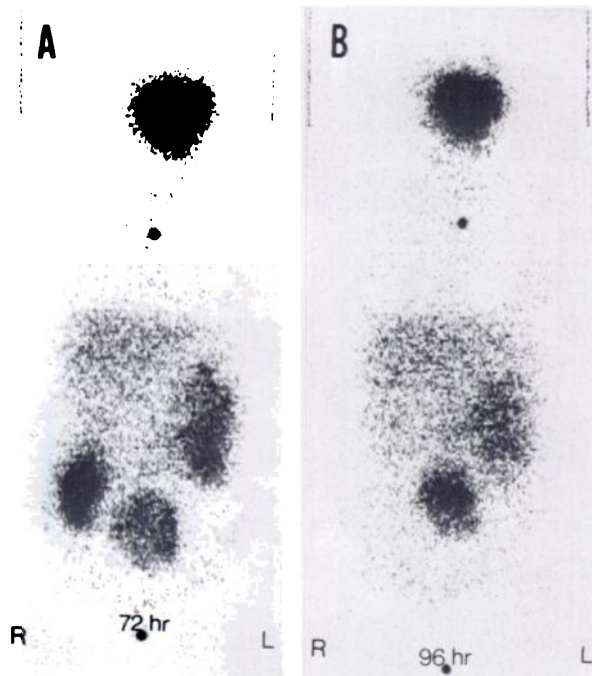


FIG. 2. Anterior whole-body scan of 15-year-old pregnant girl taken 72 hr (A) and 96 hr (B) after administration of Ga-67. In addition to marked uptake in nasopharynx, there is significant uptake by uterus. Upper marker denotes sternal notch and lower marker denotes pubic symphysis.

sues in healthy pregnant laboratory animals (2,3), as well as in the breasts and milk of postpartum lactating women (7,8). Data on the distribution of Ga-67 in pregnant women, however, are limited.

Hart and Adamson (9) have previously shown that the anionic component of gallium compounds does not influence the *in vivo* antitumor activity. Therefore, the distribution of the different gallium salts tested was probably similar. This report shows that radiogallium, administered as citrate, may concentrate in the placenta in significant amounts, and, presumably, so also may stable gallium nitrate, which is currently undergoing Phase I clinical trials as a cancer chemotherapeutic agent. This study does not rule out the possibility that gallium may be concentrated in the fetus at earlier stages of gestation when the fetus may be more susceptible to teratogenic influences. Administration of large doses of gallium nitrate or extensive use of Ga-67 may therefore represent a direct threat to the health of the developing fetus.

ACKNOWLEDGMENT

This work was supported in part by Grant PHS P20 16209 from the National Cancer Institute, National Institute of Health, U.S.P.H.S.

REFERENCES

1. LARSON SM, MILDER MS, JOHNSTON GS: Interpretation of the ^{67}Ga photoscan. *J Nucl Med* 14: 208-214, 1973
2. MAHON DF, SUBRAMANIAN G, MCAFEE JG: Experimental comparison of radioactive agents for studies of the placenta. *J Nucl Med* 14: 651-659, 1973

in animals and man include: presence of tumor, inflammation, age, sex-hormone status, and exposure to ionizing radiation (5). Uptake of Ga-67 has also been demonstrated in a number of reproductive tis-

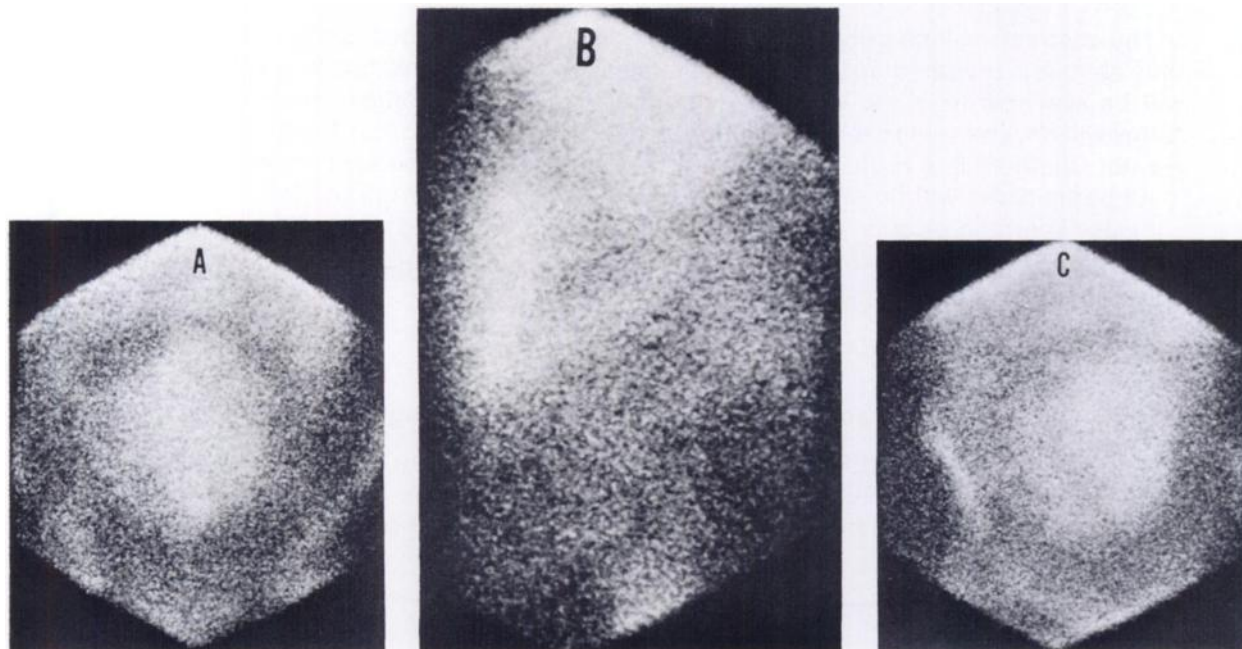


FIG. 3. Gallium scintiphotos of pelvic region, showing increased uptake of tracer in anteriorly positioned placenta. (A) anterior, (B) left lateral, (C) right oblique.

3. TYNDALL RL, CHASKES SJ, CARLTON JE, et al: Gallium-67 distribution in pregnant mammals. *J Exp Zool* 195: 417-423, 1976

4. OTTEN JA, TYNDALL RL, ESTES PC, et al: Localization of gallium-67 during embryogenesis. *Proc Soc Exp Biol Med* 142: 92-95, 1973

5. HAYES RL: The tissue distribution of gallium radio-nuclides. *J Nucl Med* 18: 740-742, 1977

6. RAMSEY EM, MARTIN CB JR, DONNER MW: Fetal and maternal placental circulations. Simultaneous visualization

in monkeys by radiography. *Am J Obstet Gynecol* 98: 419-423, 1967

7. KAN MK, HOPKINS GB: Unilateral breast uptake of ^{67}Ga from breast feeding. *Radiology* 121: 668, 1976

8. TOBIN RE, SCHNEIDER PB: Uptake of ^{67}Ga in the lactating breast and its persistence in milk: Case Report. *J Nucl Med* 17: 1055-1056, 1976

9. HART MM, ADAMSON RH: Antitumor activity and toxicity of salts of inorganic group IIIa metals: Aluminum, Gallium, Indium and Thallium. *Proc Nat Acad Sci USA* 68: 1623-1626, 1971

3rd ANNUAL WESTERN REGIONAL MEETING THE SOCIETY OF NUCLEAR MEDICINE

October 13-15, 1978

Vancouver Hotel

Vancouver, B.C., Canada

ANNOUNCEMENT AND SECOND CALL FOR ABSTRACTS FOR SCIENTIFIC PROGRAM

The Scientific Program Committee welcomes the submission of abstracts of original contributions in nuclear medicine from members and nonmembers of the Society of Nuclear Medicine for the 3rd Annual Western Regional Meeting. Physicians, scientists, and technologists—members and nonmembers—are invited to participate. The program will be structured to permit the presentation of papers from all areas of interest in the specialty of nuclear medicine. Abstracts submitted by technologists are encouraged and will be presented at the scientific program. Abstracts for the scientific program will be printed in the program booklet and will be available to all registrants at the meeting.

Guidelines for Submitting Abstracts

The abstracts will be printed from camera-ready copy provided by the authors. Therefore, only abstracts prepared on the official abstracts form will be considered. These abstract forms will be available from the Western Regional Chapters SNM office (listed below). Abstract forms will only be sent to the Pacific Northwest, Southern California, Northern California, and Hawaii Chapters in a regular mailing. All other requests will be sent on an individual basis.

All participants will be required to register and pay the appropriate fee.

Please send the original abstract form, supporting data, and six copies to:

Jean Lynch, Administrative Coordinator
3rd Western Regional Meeting
P.O. Box 40279
San Francisco, CA 94140

Deadline for abstract submission: Postmark midnight, July 7, 1978.

THE 3RD ANNUAL WESTERN REGIONAL MEETING WILL HAVE COMMERCIAL EXHIBITS AND ALL INTERESTED COMPANIES ARE INVITED. Please contact the Western Regional SNM office (address above). Phone: (415) 647-1668 or 647-0722.