

## **Scintigraphy In the Followup of Pediatric Splenic Trauma Treated without Surgery**

Keith C. Fischer\*, Angelo Eraklis, Pedro Rossello, and S. Treves

*Harvard Medical School and The Children's Hospital Medical Center,  
Boston, Massachusetts*

*Twenty patients with blunt abdominal trauma were diagnosed as having splenic rupture by Tc-99m sulfur colloid scintigraphy. Because of the increased risk of infection in children following splenectomy, surgery was not performed and scintigraphic followup of the injured spleens was carried out. Thirteen patients were scanned at least 2 mo after trauma and the longest followup was 1 yr. Only three spleens showed "scintigraphic healing." The remaining ten showed smaller defects, but in two patients the size of the defect did not change after the 2-mo scan. In no case did the scan defect enlarge. Technetium-99m sulfur colloid scintigraphy offers a convenient and sensitive method of following trauma cases if no surgery is performed. Scintigraphic defects can persist for long periods of time while the patient is asymptomatic.*

**J Nucl Med 19: 3-9, 1978**

In the past two decades, numerous investigators have reported an increased risk of septicemia—often lethal—in children following splenectomy (1-6). The risk is greatest in those patients in whom an underlying disease necessitates the splenectomy, but has also been documented in otherwise healthy patients having their spleens removed because of trauma (5,6). These observations have prompted some physicians to be wary of routine removal of a damaged spleen. When the patient's condition allows, oversewing of splenic lacerations, partial splenectomy, or nonsurgical management may be employed (7,8).

In the clinical setting of nonsurgical management of splenic trauma, scintigraphy with Tc-99m sulfur colloid has proven to be a reliable and convenient technique for diagnosing the splenic injury and docu-

menting its anatomic evolution. We have performed serial scintigraphy on a group of such patients, and we present the results below.

### **MATERIALS AND METHODS**

In the past 3 yr at Children's Hospital Medical Center a total of 24 patients with documented splenic trauma were treated with methods other than complete splenectomy. Four patients who received penetrating abdominal injuries had splenic lacerations seen at surgery. One of these patients underwent a partial splenectomy while the remaining three had their splenic lacerations oversewn.

The remaining 20 cases provide the material for this report. These patients all presented after blunt abdominal trauma, and diagnosis of splenic injury was accomplished by splenic scintigraphy in all cases. Two patients went on to arteriography because of associated injuries, and a ruptured spleen was confirmed in both of them. Clinical and scintigraphic data on all 20 patients are summarized in Table 1.

All patients were imaged 10-20 min after i.v. injection of 60  $\mu$ Ci/kg of Tc-99m sulfur colloid.

Received June 8, 1977; revision accepted Aug. 19, 1977.

For reprints contact: Salvador Treves, Div. of Pediatric Nuclear Medicine, The Children's Hospital Medical Ctr., 300 Longwood Ave., Boston, MA 02115.

\* Present address: Dept. of Radiology, Jewish Hospital, 216 S. Kingshighway, P.O. Box 14109, St. Louis, MO 63178.

TABLE 1. CLINICAL AND SCINTIGRAPHIC DATA

Case, Age & Sex	Clinical findings and hospital course	Scan findings and followup
1) J.L. 13, M	Hemophilia; Hct. 39 → 32; Factor VIII and blood given. Hct. stabilized.	Large spleen with focal defect. No F/U scan. Asymptomatic.
2) M.D. 10, M	Hct. 39 → 35; no transfusions.	Focal defect. No F/U scan. Asymptomatic.
3) S.K. 16, M	Hct. stable; no transfusions.	Band of decreased activity fills in and 3-mo scan shows no defect. Asymptomatic.
4) T.J. 8, M	Hct. 40 → 34; no transfusions.	T-shaped defect in spleen fills in by 3 mo. Asymptomatic.
5) J.H. 11, M	Hematuria. Hct. stable; no transfusions. IVP normal.	Band of decreased activity narrows but persists at 12 mo. Unchanged since 3-mo scan. Asymptomatic 6/77.
6) M.M. 7, M	Hct. 36 → 24; transfused 2 units whole blood.	Band of decreased activity narrows but persists at 12 mo. Unchanged since 2 mo. Asymptomatic.
7) F.C. 12, M	Hct. 36 → 24; transfused 4 units whole blood.	"Small" spleen with wedge defect becomes smaller but residual defects persist at 11 mo. Asymptomatic.
8) W.H. 17, M	Hct. 37 → 29; transfused 2 units of whole blood.	Band of decreased activity smaller but persists at 2 mo. Asymptomatic.
9) D.K. 13, M	Hct. 35 → 31; transfused 2 units of whole blood.	Focal defect in spleen smaller at 4 mo. Refused additional scans. Asymptomatic.
10) R.G. 4 mo, M	Angiogram shows hepatic hematoma and rt. renal laceration. Confirms splenic trauma. Hct. 30 → 18; transfused 700 cc. packed cells.	Focal defect smaller at 3 wk. Lost to followup.
11) P.M. 15, M	Angiogram shows lt. renal fracture and confirms splenic rupture. Hct. 37 → 30; transfused 2 units whole blood.	Band of decreased activity persists at 8 mo. Vague abdominal pains.
12) D.S. 6, M	Hct. 37 → 32; no transfusions.	Round focal defect partially filled in at 7 mo. Asymptomatic.
13) H.P. 5, F	Von Willebrand's disease. Hct. 30 → 24. Transfused with cryoprecipitate and whole blood.	Small band of decreased activity persists at 3½ mo. Refuses other scans. Asymptomatic.
14) C.T. 6, M	Hct. stable; no transfusions.	Focal defect persists at 5 mo, but is smaller. Asymptomatic.
15) D.B. 6, M	Hct. stable; no transfusions.	Band of decreased activity in spleen. F/U scan at outside hospital technically inadequate to assess healing. Asymptomatic.
16) L.A. 13, F	Hematuria. Hct. 35 → 29; 1 unit transfused. IVP normal.	Band of decreased activity unchanged at 5 days. F/U scan at outside hospital was inadequate. Asymptomatic.
17) M.B. 12, M	Multiple fractures. Hematuria. Hct. stable; no transfusions; normal IVP.	Band of decreased activity unchanged on scan at 5 days. Asymptomatic.
18) P.G. 1, F	Hct. stable; no transfusions given.	Spleen "small" in appearance and upper pole decreased in activity. Spleen returns to normal size and configuration on scan by 3 mo.
19) R.D. 9, M	Hct. 36 → 28; no transfusions given.	Focal defect still present and only slightly smaller after 4 mo. Asymptomatic.
20) M.H. 7, M	Hct. 40 → 29; transfused 1 unit of whole blood.	Focal defect unchanged at 10 days. No other F/U. Asymptomatic.

A gamma camera equipped with either a high-resolution or a diverging low-energy collimator was used, and 500,000-count images were obtained in anterior, posterior, left and right lateral, left anterior oblique, and left posterior oblique views. A diagnosis of splenic injury was made if a region of decreased activity was noted within the spleen.

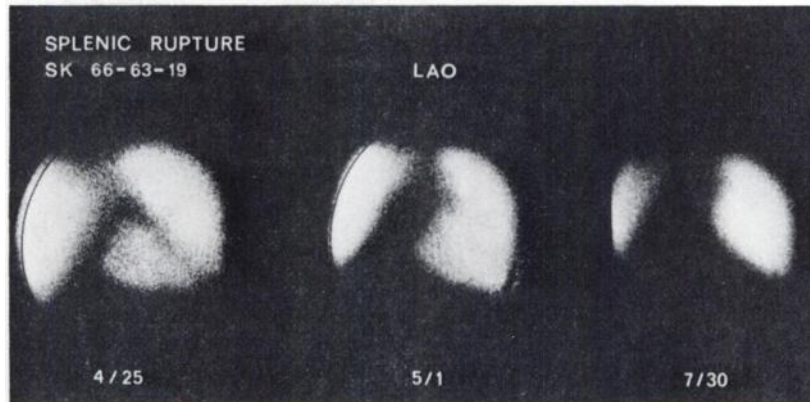
After diagnosis of splenic trauma by scintigraphy, all patients were admitted to the Surgical Service, their vital signs closely monitored, their abdominal girth recorded frequently, and sequential hematocrits obtained. Transfusions were given as necessary, and ten patients received blood during their hospital stay

(Table 1). If the patient's hematocrit stabilized within 48 hr and need for transfusions did not exceed one third of the patient's blood volume, surgery was not performed. The average hospital stay for these patients was 10–14 days. If no other medical problems were present, they were then discharged on limited activity for 2 mo. Followup scintigraphy was usually obtained before discharge and periodically thereafter.

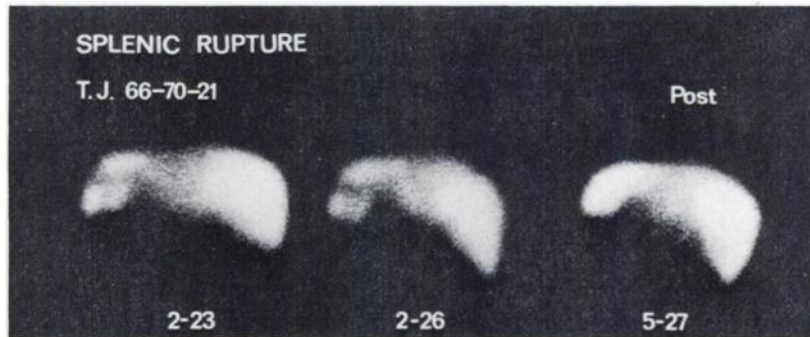
#### RESULTS

Seventeen of the 20 patients received at least one followup splenic scintigram in our department. Two

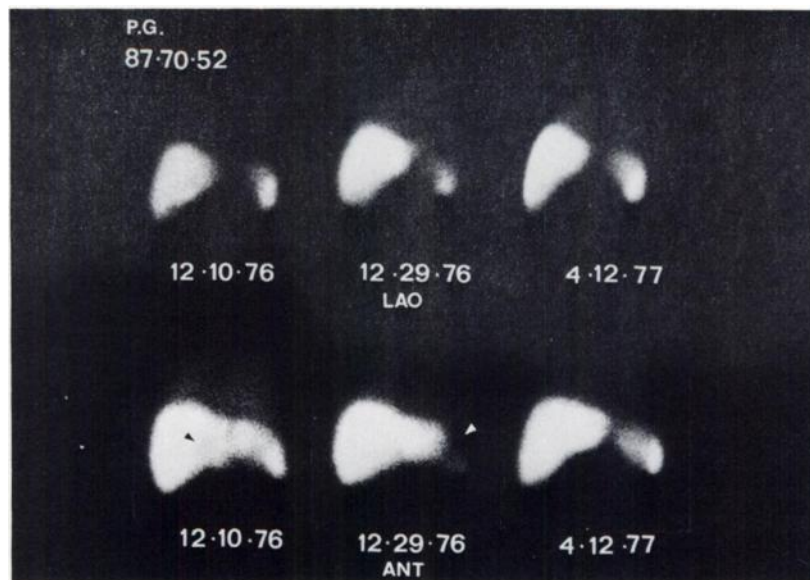
**FIG. 1.** Patient S.K. fell while running. Initial LAO scan (4/25) demonstrates oblique band of decreased activity in lower part of spleen. Six days later (5/1), this band was less evident. Three months after original trauma (7/30) the spleen is intact. Other views confirmed this. There has been some loss of splenic volume.



**FIG. 2.** Patient T.J. was injured in automobile accident. Initial posterior scan (2/23) shows T-shaped area of decreased activity. Repeat scan after 3 days (2/26) shows little change. Scan at 3 mo (5/27) shows no residual defects.



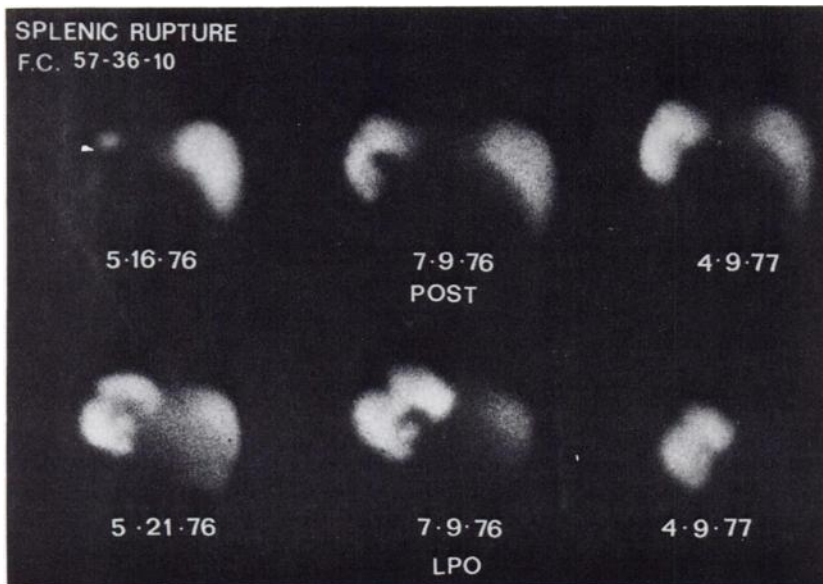
**FIG. 3.** Patient P.G. was a battered child. Initially ANT and LAO scans (12/10/76) were suspicious for an area of decreased activity in left lobe of liver (arrow), but spleen was thought normal. Patient was readmitted after further trauma. Multiple views (12/29/76) showed decreased activity in upper pole of spleen (arrow). Repeat study at 3 mo (4/12/77) shows normal distribution of activity within spleen and liver.



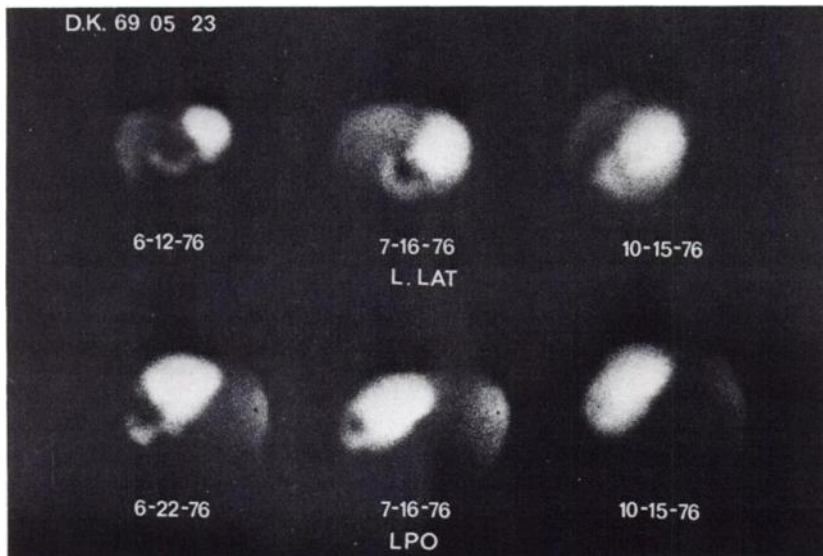
patients (L.A., D.B.) had inadequate scintigrams at an outside hospital. Thirteen patients had scintigrams 2 mo or more after the injury. Of these, three (Figs. 1-3) showed scintigraphic evidence of healing by 3 mo. The remaining ten demonstrated residual scintigraphic defects 2-12 mo after trauma. All but one patient were reached for clinical followup and of these only one (P.M.) complained of any symptoms referable to the abdomen. He complained of infre-

quent short-lived episodes of abdominal pain that were not localized to the left upper quadrant. The remaining nineteen patients and their physicians reported no abnormal physical signs or symptoms.

In no case did the initial splenic defect enlarge on subsequent spleen scan to suggest an enlarging hematoma or the formation of a traumatic cyst. Of the ten cases in which defects persisted, eight showed gradual decrease in size of the defect (Figs. 4 and 5)



**FIG. 4.** Patient F.C. fell 6 ft to ground. Initial scan (5/16/76) shows band of decreased activity in posterior projection (arrow). Scan also demonstrates a very small spleen which may be due to acute vascular constriction. Spleen appears to be in two segments but LPO view 5 days later (5/21/76) shows a "waist" of functioning tissue. Two months later (7/9/76) there is more apparent functioning splenic tissue but defect has not decreased much in size. Scan 11 mo after trauma (4/9/77) shows only a small residual defect medially.



**FIG. 5.** Patient D.K. fell 12 ft to ground. Left lateral scan (6/12/76) and LPO (6/22/76) show large defect in inferior portion of spleen. One month after trauma (7/16/76) defect has decreased in size. Four months post trauma (10/15/76) only a suggestion of the defect remains.

while two patients (M.M., J.H.) showed a stable scintigraphic defect over an extended followup (Figs. 6 and 7).

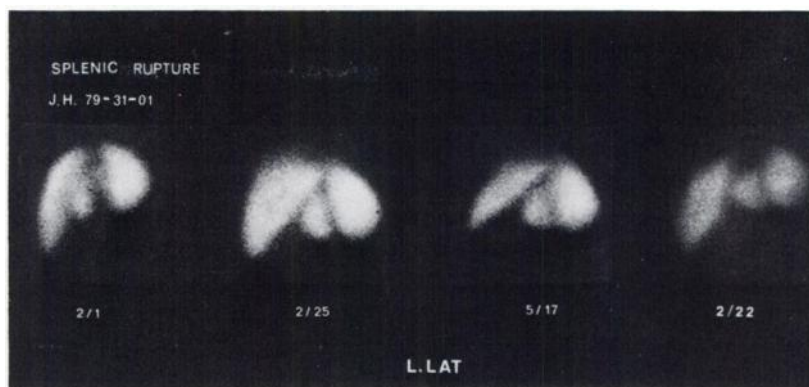
**DISCUSSION**

At our institution, the primary means for diagnosing splenic trauma are the clinical examination and the Tc-99m sulfur colloid spleen scintiphoto. The specificity and sensitivity of gamma imaging for detection of splenic trauma has been adequately documented (9,10). In a large combined series, Gilday and Alderson found that 134 of 136 patients (98.5%) with splenic trauma had abnormal scans (9). In their series, there were 7.2% false positives, but with multiple views this number can probably be reduced. Only 2/136 (1.5%) of patients with

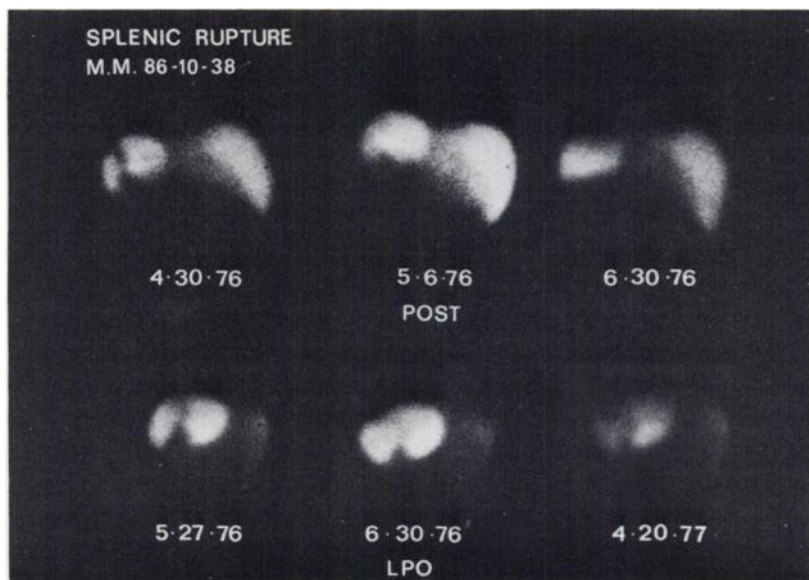
documented splenic trauma had a normal image. Because of this excellent correlation of an abnormal scintigram with documented splenic trauma in our patients, angiography was performed only to define additional injuries.

Beginning with the report of King and Schumaker in 1952 (1), physicians have been made aware of the increased risk of overwhelming and lethal infections in patients without splenic tissue. This risk is considerably greater than that in the general population if the patient has an underlying debilitating disease, such as thalassemia or portal hypertension, which has led to the splenectomy; but an increased risk above that found in the general population can be documented in cases of trauma that have had splenectomy (5,6). The total incidence of post-

**FIG. 6.** Patient J.H. fell on stairs. Initial left lateral scan (2/1/76) demonstrated wide band of decreased activity through spleen. Subsequent scans (2/25/76, 5/17/76, and 2/22/77) show that band persists, with only minor narrowing.



**FIG. 7.** Patient M.M. was hit by car. Initial posterior scan (4/30/76) shows vertical band of decreased activity in addition to wedge-shaped defect inferiorly. By 6/30/76, the fault is not seen on posterior projection but shows well on LPO view (middle of bottom row). On 4/20/77, only the LPO shows defect, which has changed little.



splenectomy mortality from sepsis is estimated to range from 0.25% to 0.58% (5,6), whereas the incidence of sepsis in the general population for all ages is 0.1% (11). This hazard appears to be greatest in children, especially under the age of 1, and 75% of the infections occur within 2 yr after operation (4). The organism most commonly associated with the septicemia is *Diplococcus pneumoniae* in about 50% of cases, and the remainder are due to *Hemophilus influenzae*, *Staphylococcus aureus*, group A streptococcus, and *Neisseria meningitidis* (12).

The exact physiologic explanation for the increased incidence of infection is not known. The spleen comprises 25% of the total lymphoid mass of the body and functions to clear the body of particulate antigens. Postsplenectomy, serum opsonin levels are low and there is defective production of IgM (12). "Tuftsin," a tetrapeptide that stimulates the phagocytic capability of neutrophils, is markedly reduced after splenectomy (13). All these factors may be important in patients' reduced ability to mount a

defense against bacterial infection after splenectomy, but so far no consistent relationship has been found between the levels of these substances and the occurrence of infections.

Whatever the spleen's role in the body's defense against sepsis, the presence of a certain mass of splenic tissue with an intact blood supply appears to be essential for the functional integrity of the defense system (6). Thus, more conservative approaches to the treatment of trauma cases have been adopted, stressing preservation of splenic tissue. Partial splenectomy, oversewing of lacerations, and nonoperative treatment have all been used at our hospital and elsewhere (7,8). At our institution, if the patient's hematocrit can be stabilized within 48 hr, even if it requires transfusions up to one third of the patient's expected blood volume, operation is not performed unless necessitated by associated trauma.

One potential danger of not removing a damaged spleen is believed to be delayed rupture, but this is controversial (14-16). Another potential complica-

tion of nonoperated splenic trauma is the development of a splenic pseudocyst (17,18). These are non-epithelial lined cystic structures containing bloody material. They may present as a mass at a time when the episode of trauma may not even be remembered. Scintigraphy has been previously used to diagnose a splenic pseudocyst (17,18). Ultrasonography also has been utilized to demonstrate a splenic pseudocyst (18). Splenic scintigraphy can thus play an important role not only in diagnosing splenic trauma but also in following patients who, once diagnosed, can be periodically evaluated for evidence (a) that the splenic hematoma and/or laceration is resolving, and (b) that no posttraumatic cysts are developing.

The previous experience of serially evaluating injured spleens with scintigraphy is small. Lutzker et al. reported a nonoperated case in which a defect had filled in by 2 mo posttrauma (19). Mishalany reported a case of splenic laceration that was oversewn at surgery. A band of decreased activity was noted on a spleen scan 9 days postoperatively, but it had filled in on a repeat study 2 mo later (8).

Our experience has been that the majority of lesions do not fill in scintigraphically over a 2-mo period. Of the thirteen patients followed for longer than 2 mo, only three showed resolution of their scintigraphic defects. One of these (P.G.) did not develop a focal area of decreased activity in the spleen but rather a general decrease in activity in the upper pole, which was a clear change from a baseline study (Fig. 3). This pattern may reflect a change in splenic blood flow in acute trauma. Another patient (F.C., Fig. 4) demonstrated a marked decrease in peripheral spleen activity acutely; it was reperused in a subsequent scan, even though a defect persisted in the body of the spleen.

In this study, sequential scans most frequently showed decreasing size of defects but two cases were exceptions. On these, the bandlike defects, after narrowing initially, stabilized in size so that there was essentially no change after 2 mo (Figs. 4, 5). It is problematic what these bands of decreased activity may represent. Nebesar et al. (10) have correlated the scintigraphic patterns of acute spleen trauma with surgical findings. Linear defects were generally found at the site of intrasplenic hematomas and lacerations. The persistent defects in our cases thus most likely represent cicatrization at the site of lacerations. Scintigraphic defects that resolve are presumed to be less extensive hematomas and infarcted splenic tissue, and when a scar forms it does not separate functioning tissue so far as to be resolved as a defect. Our study confirms that multiple views are essential for diagnosis of trauma and are also essential in followup. The spleen is extremely mobile and one view that

has shown the defect previously may look normal subsequently, even though a residual defect persists (Fig. 7).

Splenic scintigraphy has a definite place in the diagnosis of splenic trauma and might well be the initial study performed. If surgery is not performed, a scan before discharge (10–14 days) is suggested, to determine that a defect is not enlarging. The next scan might be performed from 2 to 3 mo after trauma to confirm that the defects are still decreasing in size. The mere presence of a residual defect is probably not a reason for keeping the patient on restricted activity, but rather this is a decision better made on clinical grounds. Continued scintigraphic followup is probably optional if no clinical complication arises. It should be mandatory if pain develops or a mass becomes palpable in the left upper quadrant.

#### REFERENCES

1. KING H, SCHUMAKER HB: Splenic studies: I. Susceptibility to infection after splenectomy performed in infancy. *Ann Surg* 136: 239–242, 1952
2. ERAKLIS AJ, KEVY SV, DIAMOND LK, et al: Hazard of overwhelming infection after splenectomy in childhood. *NEJM* 276: 1225–1229, 1967
3. SMITH CH, ERLANDSON M, SCHULMAN I, et al: Hazard of severe infection in splenectomized infants and children. *Am J Med* 22: 390–404, 1957
4. WINTER ST: Trauma, splenectomy and the risk of infection. *Clin Peds* 13: 1011–1012, 1974
5. WALKER W: Splenectomy in childhood: A review in England and Wales, 1960–1964. *Brit J Surg* 63: 36–43, 1976
6. SINGER DB: Postsplenectomy sepsis. In *Perspectives in Pediatric Pathology*. Rosenberg HS and Bolande RP eds. Chicago, Year Book Medical Publishers, Inc., 1973, pp 285–311
7. DOUGLAS GJ, SIMPSON JS: The conservative management of splenic trauma. *J Ped Surg* 6: 565–570, 1971
8. MISHALANY H: Repair of the ruptured spleen. *J Ped Surg* 9: 175–178, 1974
9. GILDAY D, ALDERSON PO: Scintigraphic evaluation of liver and spleen injury. *Sem Nucl Med* 4: 357–370, 1974
10. NEBESAR RA, RABINOV KR, POTSAID MS: Radio-nuclide imaging of the spleen in suspected splenic injury. *Radiology* 110: 609–614, 1974
11. DAUER CC, KORNS RF, SCHUMAN LM: *Infectious Diseases*. Cambridge, MA, Harvard University Press, 1968, pp 134–139
12. LIKHTE VV: Immunological impairment and susceptibility to infection after splenectomy. *JAMA* 236: 1376–1377, 1976
13. CONSTANTOPOULOS A, NAJJAR VA, SMITH JW: Tuftsin deficiency: A new syndrome with defective phagocytosis. *J Pediatr* 80: 564–572, 1972
14. AYALA LA, WILLIAMS LF, WIDRICH WL: Occult rupture of the spleen. *Ann Surg* 179: 472–478, 1974
15. OLSEN WR: Delayed rupture of the spleen as an index of diagnostic accuracy. *Surg Gyn Obstet* 138: 82, 1974
16. BENJAMIN CI, ENGRAV LH, PERRY JF: Delayed rup-

ture or delayed diagnosis of rupture of the spleen. *Surg Gyn Obstet* 142: 171-172, 1976

17. TOPILLOW AA, STEINHOFF NG: Splenic pseudocyst: A late complication of trauma. *J Trauma* 15: 260-263, 1975

18. WRIGHT FW, WILLIAMS EW: Large post-traumatic

splenic cyst diagnosed by radiology, isotope scintigraphy and ultrasound. *Brit J Rad* 47: 454-456, 1974

19. LUTZKER L, KOENIGSBERG M, CHIEN-HSING M, et al: The role of radionuclide imaging in spleen trauma. *Rad* 110: 419-425, 1974

### Accepted Articles to Appear in Upcoming Issues

Normal Adrenal Asymmetry: Explanation and Interpretation. Accepted 8/3/77.

John E. Freitas, James H. Thrall, Dennis P. Swanson, Ayman Rifai, and William H. Beierwaltes

The Increasing Incidence of Hypothyroidism Within One Year After Radioiodine Therapy for Toxic Diffuse Goiter. Accepted 8/22/77.

Stanley E. Von Hofe, Steven G. Dorfman, Robert F. Carretta, and Robert L. Young

Radiometric Detection of Herpes Simplex viruses. Accepted 9/1/77.

Nancy L. D'Antonio, Min-Fu Tsan, Diane E. Griffin, Patricia A. Charache, and Henry N. Wagner Jr.

Cerebral Perfusion Deficit Masked by Paget's Disease of Skull (Case Report). Accepted 9/2/77.

Kenneth R. Hofstetter, Dennis D. Patton, and Robert E. Henry  
Thallium-201 Imaging in Thyroid Carcinoma—Appearance of a Lymphnode Metastasis (Case Report). Accepted 9/7/77.

Minoru Fukuchi, Keizo Tachibana, Keiji Kuwata, Akiharu Nishikawa, Kayo Hyodo, Eizo Okamoto, and Kiyoyasu Nagai

Cardiac Chamber Imaging: A comparison of Red Blood Cells Labeled with Tc-99m In Vitro and In Vivo. Accepted 9/7/77.

Frederick N. Hegge, Glen W. Hamilton, Steven M. Larson, James L. Ritchie, and Powell Richards

Liver Scintigraphic Features Associated with Alcoholism. Accepted 9/9/77.

David E. Drum and Judith O. Beard  
Effect of Cytomegalovirus Infection on Metabolism of WI-38 Cell Cultures (Concise Communication). Accepted 9/14/77.

Evelyn M. Hurlburt, Ping F. Ki, and Henry N. Wagner, Jr.  
Radionuclide Study in Pulmonary Sequestration (Case Report). Accepted 9/14/77.

Kenji Kawakami, Shimpei Tada, Naofumi Katsuyama, and Sachio Mochizuki

Decreased Tumor Uptake of Gallium-67 in Animals after Whole-Body Irradiation. Accepted 9/16/77.

W. P. Bradley, P. O. Alderson, W. C. Eckelman, R. G. Hamilton, and J. F. Weiss

Focally Accentuated Uptake in an Area of Increased Activity in Tc-99m HEDP Brain Scan (Case Report). Accepted 9/16/77.

Kyung-Il Lee, Teruhiko Tanaka, and Takatsugu Ohi

Extrasosseous Accumulation of Tc-99m Pyrophosphate in Soft Tissue After Radiation Therapy. Accepted 9/18/77.

A. Bekier  
Localization of Ga-67 in Inflammations in the Absence of Circulating Polymorphonuclear Leukocytes (Case Report). Accepted 9/19/77.

Vijay M. Dhawan, John J. Sziklas, and Richard P. Spencer

Scintigraphic Detection of Congenital Intracranial Vascular Malformations. Accepted 9/20/77.

Gary F. Gates, Lawrence S. Fishman, and Harvey D. Segall

Tc-99m pyrophosphate Muscle Labeling in McArdle Syndrome (Case Report). Accepted 9/21/77.

Thomas R. Swift and Mark Brown

Myocardial Imaging with Thallium-201: Effect of Cardiac Drugs on Myocardial Images and Absolute Tissue Distribution. Accepted 9/20/77.

Glen W. Hamilton, Kenneth A. Narahara, Henry Yee, James L. Ritchie, David L. Williams, and K. Lance Gould

Clinical Comparison of Technetium-99m Diphosphonate and Pyrophosphate in Bone Scintigraphy (Concise Communication). Accepted 9/21/77

Edward B. Silberstein, Harry R. Maxon III, George W. Alexander, Jr., and Chris Rauf

Relative Renal Accumulation of Tc-99m Penicillamine as an Index of Differential Renal Function (Concise Communication). Accepted 9/21/77.

Andrew Taylor and Lee B. Talner

The Use of Videotape for Off-Line Viewing of Computer-Assisted Radionuclide Cardiology Studies (Technical Note). Accepted 9/21/77.

James H. Thrall, Bertram Pitt, and Robert S. Marx

The Predictive Value of Myocardial Perfusion Scintigraphy After Stress in Patients Without Previous Myocardial Infarction. Accepted 9/21/77.

David A. Turner, William E. Battle, Hanumant Deshmukh, Michael A. Colandrea, Gary J. Snyder, Ernest W. Fordham, and Joseph V. Messer

Fatty Acid Accumulation and Abnormal Lipid Deposition in Peripheral and Border Zones of Experimental Myocardial Infarcts. Accepted 9/23/77.

David W. Bilheimer, L. Maximilian Buja, Robert W. Parkey, Frederick J. Bonte, and James T. Willerson

Motion Corrected Hepatic Scintigraphy: An Objective Clinical Evaluation. Accepted 9/26/77.

David A. Turner, Ernest W. Fordham, Amjad Ali, Paul D. Rubin, Robert C. Muerhrcke, Bernard E. Oppenheim, Nicholas J. Yasillo, Arun N. Sukerkar, Gary J. Novetsky, Depak P. Dalia, and Paul B. Hoffer

Localization of Tc-99m Pyrophosphate in Muscle After Exercise. Accepted 9/26/77.

Brian C. Lentle, John S. Percy, Wynne M. Rigal, and Anthony S. Russell

Ventilation-Perfusion Lung Imaging and Selective Pulmonary Angiography in Dogs with Experimental Pulmonary Embolism. Accepted 10/6/77.

P. O. Alderson, J. L. Doppman, S. S. Diamond, K. G. Mendenhall, E. L. Barron, and Mary Girton

Distribution of Thallium-201 Injected Into Rats Following Stress: Imaging, Organ-to-Plasma Uptake Ratios, and Myocardial Kinetics. Accepted 10/6/77.

Josep G. Llaurodo, Jane A. Madden, Robert C. Meade, and George A. Smith

Imaging the Adrenal Glands with Radiolabeled Inhibitors of Enzymes (Concise Communication). Accepted 10/10/77.

William H. Beierwaltes, Donald M. Wieland, Stephen T. Mosely, Dennis P. Swanson, Salil D. Sarkar, John E. Freitas, James H. Thrall, and Karl R. Herwig

An Intuitive Approach to Receiver Operating Characteristic Curve Analysis. Accepted 10/10/77.

David A. Turner

Comparison of 19-Iodocholesterol and 6-Iodomethylnorcholesterol as Adrenal Scanning Agents (Letter to the Editor). Accepted 10/10/77.

S. Kraychy and M. A. Leeper  
Reply. Accepted 10/10/77.

Margaret W. Couch and Clyde M. Williams

In Vivo Labeling of Red Blood Cells with Perchnetate in Hyperthyroidism (Letter to the Editor). Accepted 10/10/77.

Kyoichi Ueno  
Reply. Accepted 10/10/77.

Dan G. Pavel and A. M. Zimmer

An Optimized Collimator for Single-Photon Computed Tomography with a Scintillation Camera (Technical Note). Accepted 10/10/77.

Louis T. Kircos, Patrick F. Leonard, and John W. Keyes, Jr.  
Human Reaction to Bovine TSH (Concise Communications). Accepted 10/10/77.

G. T. Krishnamurthy

Evaluation of Left-Ventricular Function in Normal Persons and Patients with Heart Disease. Accepted 10/10/77.

Saeeda Qureshi, Henry N. Wagner, Jr., Philip O. Alderson, Daniel F. Housholder, Kenneth H. Douglass, Mattheus G. Lotter, Edward L. Nickoloff, Masatada Tanabe, and Lloyd G. Knowles

The Complementary Role of Gallium Citrate Imaging and Computed Tomography in the Evaluation of Suspected Abdominal Infection. Accepted 10/10/77.

Robert R. Shimshak, Melvyn Korobkin, Paul B. Hoffer, Robert Schor, Thomas C. Hill, and Herbert Y. Kressel