Bone Scan Artifact Caused by Hyperhidrosis: Case Report

Suraindar K. Ajmani, Samuel R. Lerner, and Felix J. Pircher

Baylor College of Medicine and Veterans Administration Hospital, Houston, Texas

An unusual unilateral axillary concentration of radioactivity was observed in a bone scan. The cause was contamination of the patient's undershirt due to localized hyperhidrosis.

J Nucl Med 18: 801–802, 1977

Scanning artifacts are occasionally produced by contamination of body surface or clothing with radioactivity excreted in saliva, urine, and feces. A case is described in which excessive localized sweating caused an unusual artefact in bone scans.

CASE REPORT

A 57-year-old white male was under evaluation for recurrent left-sided chest pain of 5-year duration. He was first hospitalized in 1972 for evaluation of transient ischemic episodes and suffered a cardiac arrest during a four-vessel angiography. After successful resuscitation he was found to have had an inferior myocardial infarction and minimal left hemiparesis; the latter was attributed to cerebral ischemia. His recovery was uneventful. During the following 4 years he was treated for angina pectoris with coronary vasodilators, with adequate relief. In addition, however, he had developed recurrent left chest pain, which was not relieved by coronary vasodilators; this was believed to be musculoskeletal or psychogenic in origin. To investigate the cause of pain, a bone scan was performed in January 1976. The scan (Fig. 1), done 3 hr after administration of 15 mCi Tc-99m pyrophosphate, showed extraskeletal accumulation of radioactivity in the left axillary region. There was no abnormal localization of tracer in the stomach, salivary glands, or thyroid. No skeletal abnormality was seen. A spot scintillation-camera image of the left shoulder region (Fig. 1, inset a) showed a slightly different pattern of the abnormality, and in a repeat spot image (Fig. 1, inset b), obtained after removal of the patient's clothing and wiping of the axilla, the artefact had vanished. On direct questioning it was learned that the patient had developed hyperhidrosis, limited to the left axilla, following the episode of cardiac arrest and left hemiparesis 4 years earlier. Laboratory tests, including serum calcium, phosphate, alkaline phosphatase, BUN, and creatinine, were all within normal limits.

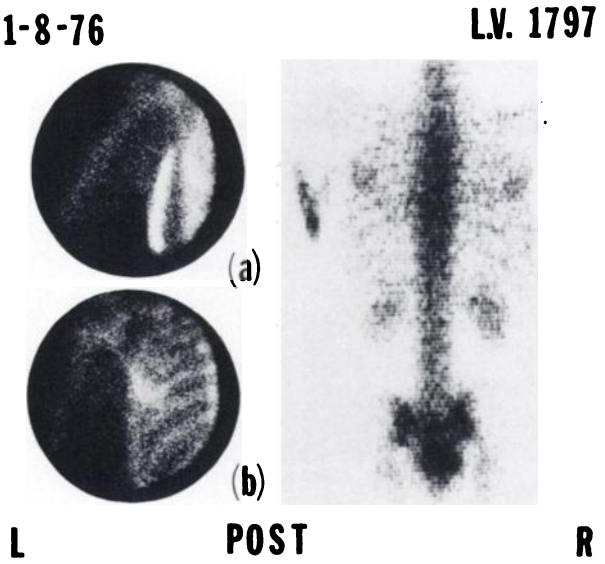

FIG. 1. Posterior bone scan showing extraskeletal abnormality in left axillary region. Scintillation-camera image inset (a) shows different pattern of artefact caused by radioactive sweat. Inset (b) obtained after removal of contaminated clothing and wiping of axilla shows no abnormality.

Received Dec. 14, 1976; revision accepted Feb. 17, 1977.

For reprints contact: S. K. Ajmani, Veterans Administration Hospital, Nuclear Medicine Service, 580/115, 2002 Holcombe Blvd., Houston, TX 77211.

COMMENTS

Radioactive contamination of body surface or clothing may occur, due to either accidental spillage of the dose or by excretion of the tracer or its metabolites by the body. This is seen in the scans as points or irregular lines of radioactivity that shift in an unphysiologic manner with change in position of the patient or clothing. Differentiation from soft-tissue uptake may be achieved by removing the clothing and cleansing the contaminated area and repeating the scan.

Hyperhidrosis may be either generalized or localized to one area. Localized hyperhidrosis occurs frequently in palms, soles, and intertriginous areas: namely, the axillae, the inguinal folds, and the perineal areas. Other common sites are the forehead, the tip of the nose, and the sternal area. The most frequent cause of localized hyperhidrosis is emotional. It is also seen with tabes dorsalis, hemiplegia, and unilateral nerve disorders (*1*).

Sweat contains only traces of phosphate (0.022–0.22 mg/ml), but has significant amounts of chloride (18–97 mEq/liters) (*2*). The chemical composition of the radioactivity in the sweat of the patient under discussion is unknown. It could be Tc-99m pyrophosphate or the hydrolyzed product, as $^{99m}TcO_4^-$, which might be handled like chloride by the sweat glands. The latter possibility is less likely, as no uptake or excretion was seen in the salivary glands, thyroid, or stomach, and routine quality-control chromatography showed less than 5% free Tc-99m in the preparation.

REFERENCES

1. DOMONKOS AN: *Andrews' Diseases of the Skin.* Philadelphia, Saunders, 1971, pp 9–10

2. CARRUTHERS C: *Biochemistry of Skin in Health and Disease.* Springfield, Ill, CC Thomas, 1962, pp 131–157