

Comparative Accumulation of ^{99m}Tc and ^{131}I in Thyroid Nodules: Case Report

Marjan Erjavec, Tadeja Movrin, Marija Auersperg, and Rastko Golouh

Institute of Oncology, Ljubljana, Yugoslavia

Imaging was performed with both pertechnetate and ^{131}I in 58 patients with thyroid nodules. Pertechnetate concentrated in all 12 follicular carcinomas, in two out of seven papillary carcinomas, and in some benign nodules that did not accumulate ^{131}I in the 24-hr images.

J Nucl Med 18: 346-347, 1977

Sodium pertechnetate "trapped" by thyroid tissue is suitable for thyroid imaging, yielding essentially the same information as that obtained with ^{131}I (1). This radionuclide has appreciably replaced ^{131}I for imaging purposes because of its excellent physical characteristics and low radiation risk. Occasionally, however, ^{99m}Tc has been observed to concentrate in lesions that appear to be hypofunctional ("cold") with ^{131}I that have proved to be adenomas or carcinomas (2-6). In our institution a patient with a large follicular carcinoma was imaged, and the pertechnetate clearly concentrated in the tumor but virtually none was found in the remaining thyroid tissue (Fig. 1). The gland, however, accumulated ^{131}I normally, whereas the tumor was "cold." This unexpected finding led us to study the differences in the uptake of these two radionuclides in thyroid nodules.

MATERIALS AND METHODS

For 20 months all patients with thyroid nodules or recurrent thyroid cancer seen in the nuclear medicine laboratory had thyroid images taken with both ^{131}I and ^{99m}Tc . Scanning was performed 24 hr after oral administration of 0.05 mCi of ^{131}I and 20-40 min after administration of 1.2 mCi of ^{99m}Tc . Occasionally there was a 2-3-day interval between the two studies. At first, computer-assisted subtraction of the two large images was used, but since any difference between the two was clearly discernible, the results were later interpreted directly from the original studies. In 58 patients the nature of the lesion was shown cytologically or histologically. The histologic slides were reviewed if the patients were admitted with recurrent cancer following surgery performed elsewhere. In four out of five cases with autonomous

adenoma the diagnosis was established only by clinical and laboratory means.

RESULTS AND DISCUSSION

In all 12 patients with thyroid follicular carcinomas ^{99m}Tc accumulated in the nodules (Fig. 1) but the ^{131}I did not (Table 1). The same was true in two (locally recurrent) out of seven patients with papillary carcinomas, but a review of the tissue histology revealed a follicular component in both cases. A $^{99m}\text{Tc}/^{131}\text{I}$ accumulation difference was found also in one out of five patients with follicular adenomas and in three out of 19 patients with multinodular goiters. The remainder of the nodular lesions did not show an appreciable difference in the concentration of ^{99m}Tc and ^{131}I . Of the 18 patients who only accumulated sodium pertechnetate in the nodules, eight were men, all had follicular carcinomas, and all were over 45 years old. Of the ten women, four had follicular and two had papillary carcinoma and all were over 55 years old. Three women with colloidal goiter were between ages 36 and 53 and the woman with follicular adenoma was 20 years old.

Two patients with follicular carcinoma soon developed distant metastases which clearly accumulated ^{99m}Tc , whereas the ^{131}I uptake was only slight in one case, and none in the other even after thyroid ablation and administration of thyroid-stimulating hormone.

Received March 30, 1976; revision accepted Sept. 19, 1976.

For reprints contact: Marjan Erjavec, Isotope Dept., Institute of Oncology, Ljubljana, Yugoslavia.

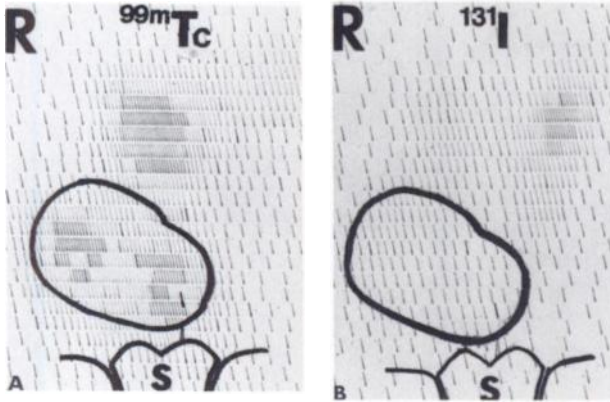


FIG. 1. Large follicular carcinoma before surgery. Pertechnetate accumulated with tumor (A) while iodine only accumulated in remaining normal gland (B).

TABLE 1. RESULTS OF SCINTIGRAPHY WITH ^{99m}Tc AND ^{131}I IN 58 PATIENTS WITH THYROID NODULES*

Nature of lesion	Uptakes of ^{99m}Tc vs. ^{131}I		Total
	Different	Similar	
Follicular carcinoma	12	0	12
Papillary carcinoma	2	5	7
Anaplastic carcinoma	0	4	4
Reticulosarcoma	0	2	2
Chronic lymphocytic thyroiditis	0	2	2
Autonomous adenoma	0	5	5
Follicular adenoma	1	4	5
Nodular and cystic goiter	3	18	21
Total	18	40	58

* The uptake of the two nuclides was either similar [i.e., the nodules were "cold" in both images (except five "hot" autonomous ones)] or else different [i.e., there was a clear accumulation of ^{99m}Tc in areas "cold" with ^{131}I].

To more directly compare the properties of pertechnetate temporally, two patients with follicular carcinoma were imaged 1 and 24 hr after administration of ^{131}I . Radioactivity was found in both tumors at 1 hr but not at 24 hr. Abnormal thyroid tissue may lose the ability to organify iodine but may retain the "trapping" function. The sodium pertechnetate images, obtained previously, were similar to the early images obtained with iodine but were of superior technical quality.

One of the most striking findings in this study was the dissociation of the two functions in all cases of follicular carcinoma. If this dissociation can be documented in a larger series of patients, it might be of diagnostic value (even though adenomas may occasionally behave similarly). This phenomenon might represent a step in the cell alteration toward malignancy. Since highly differentiated follicular carcinomas are difficult to diagnose histologically without the presence of vascular or capsular invasion, the finding of disassociation could be of diagnostic help. If the pertechnetate concentration within a nodule were the same as that within the normal thyroid, the nodule could still be identifiable if it were larger than the gland or showed an abnormal configuration. In some of our cases, however, the pertechnetate concentration in the nodule clearly suggested an "autonomous adenoma with extranodal tissue suppression," thus indicating that the pertechnetate uptake of the nodule could exceed that of the normal gland. In this series, one patient with follicular carcinoma underwent nonradical surgery after a diagnosis of an "euthyroid autonomous adenoma" had been made from the pertechnetate scan. This patient was later readmitted with a recurrent malignancy. We believe that both radionuclides should be employed in cases of solitary thyroid nodules to avoid misleading conclusions and serious errors.

REFERENCES

1. SANDERS TP, KUHL DE: Technetium pertechnetate as a thyroid scanning agent. *Radiology* 91: 23-26, 1968
2. STEINBERG M, CAVALIERI RR, CHOY SH: Uptake of technetium 99m-pertechnetate in primary thyroid carcinoma. Need for caution in evaluating nodules. *J Clin Endocrinol Metab* 31: 81-84, 1970
3. USHER MS, ARZOUMANIAN AY: Thyroid nodule scans made with pertechnetate and iodine may give inconsistent results. *J Nucl Med* 12: 136-137, 1971
4. SCHALL GL, ROTH JA, TEMPLE R: Differential uptake of ^{131}I and $^{99m}\text{TcO}_4^-$ in a histologically unusual metastatic thyroid carcinoma. *J Surg Oncol* 5: 235-244, 1973
5. HIRABAYASHI S, KOGA Y, KITAHARA T, et al.: Inconsistent images of thyroid nodule scintigrams made with iodine and pertechnetate: Case report. *J Nucl Med* 16: 918, 1975
6. TURNER JW, SPENCER RP: Thyroid carcinoma presenting as a pertechnetate "hot" nodule, but without ^{131}I uptake: Case report. *J Nucl Med* 17: 22-23, 1976