

^{99m}Tc-Pyrophosphate Scan and Radiographic Correlation in Thyroid Acropachy: Case Report

Robert S. Seigel, James H. Thrall, and James C. Sisson

University of Michigan Medical Center, Ann Arbor, Michigan

A case of thyroid acropachy secondary to Graves' disease is described. Radiographic abnormalities were found to correlate with those in a ^{99m}Tc-pyrophosphate bone scan. Abnormal tracer concentrations were observed in the diaphyses of the metacarpals and phalanges of both hands and also in regions of pretibial myxedema. The differential diagnosis of the scan abnormalities is discussed.

J Nucl Med 17: 791-793, 1976

Thyroid acropachy is an uncommon complication of Graves' disease manifested by soft-tissue swelling of the phalanges, clubbing of the terminal phalanges, and periosteal new-bone formation in both the hands and feet (1-4). The following case is presented (A) to illustrate the pattern of periosteal and soft-tissue abnormalities; (B) to correlate the scan and x-ray findings; and (C) to discuss the differential diagnosis of the scintigraphic findings.

CASE REPORT

A 23-year-old white woman developed Graves' ophthalmopathy and hyperthyroidism. In April 1973, she received a 5-mCi dose of ¹³¹I. Several months

Received Jan. 12, 1976; original accepted Jan. 27, 1976.

For reprints contact: James H. Thrall, Div. of Nuclear Medicine, University of Michigan Medical Center, 1405 E. Ann St., Ann Arbor, MI 48104.

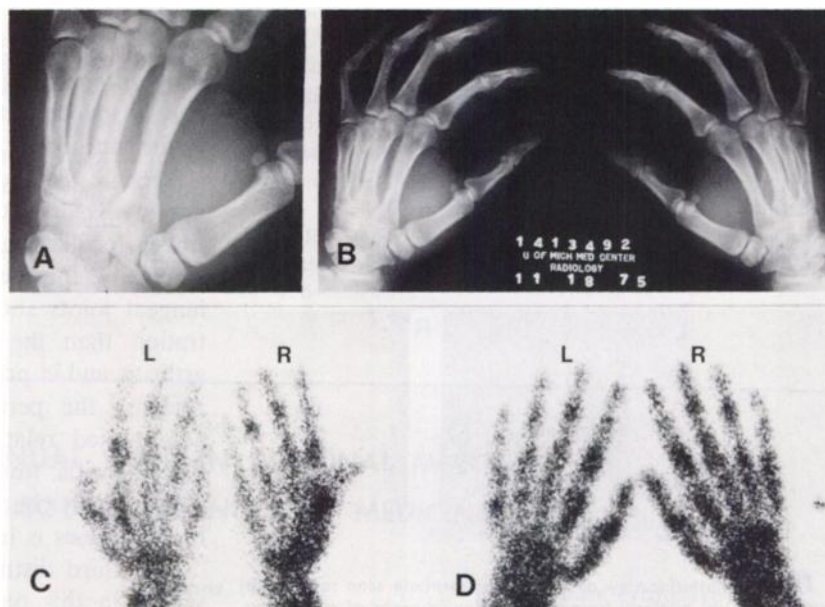


FIG. 1. Radiographs (A,B) and scintigrams (C,D) of hands and wrists. Numerous radiographically normal areas show increased uptake. Note striking tracer uptake in several middle phalanges.

later she developed hypothyroidism, which was reversed with thyroxine treatment. In November 1974, she noted hyperpigmentation of the skin over her shins and a painless swelling of her fingers, requiring the removal of her wedding ring.

When seen in November 1975, she manifested moderate Graves' eye disease. Her thyroid gland was not palpable. Characteristic pretibial myxedema surrounded the legs from the ankle to the proximal calf bilaterally, and there was fusiform swelling of the proximal phalanges of the hands and clubbing at the terminal phalanges.

Radiographs of the hands (Figs. 1A and 1B) showed periosteal reaction of a lamellar type paralleling the diaphyses of the first, second, and fifth metacarpals bilaterally and the third metacarpal on the left. The first and fifth phalanges were also abnormal proximally on both sides, but no middle or distal phalangeal involvement was shown.

Skeletal imaging was performed 4 hr after intravenous injection of 15 mCi of ^{99m}Tc -pyrophosphate, using a Series 110 Ohio-Nuclear scintillation camera. Increased tracer concentration was shown in all areas of radiographic abnormality. Additional uptake, without corresponding radiographic abnormalities, was present in several middle phalanges

and in both wrists (Figs. 1C and 1D). The abnormal uptake was confined to the diaphyses of the involved tubular bones, and no increased accumulation was seen in the metacarpal-phalangeal or interphalangeal joints. Diffusely increased uptake was seen in the soft tissues of both lower extremities corresponding to the regions of pretibial myxedema observed clinically (Fig. 2).

DISCUSSION

Thyroid acropachy is a relatively uncommon (<1%) complication of Graves' disease. Because of the benign course of thyroid acropachy, it is important to distinguish it from such diseases as hypertrophic pulmonary osteoarthropathy. Other potential causes of diffusely increased skeletal tracer concentrations which should be considered in the differential diagnosis include rheumatoid arthritis, osteoarthritis, and hyperparathyroidism. Scintigraphic patterns on ^{99m}Tc bone scans have been described in all of these conditions (5-8). Pachydermoperiostosis might also be considered, but it is extremely rare and scintigraphic findings have not yet been reported in that disorder (9).

One report of thyroid acropachy has described the scintigraphic findings when ^{85}Sr was used as the skeletal tracer (10). Concentrations in the ends of long bones were identified, but no mention was made of abnormalities in the hands and wrists or of pretibial myxedema, as seen in the present case.

Three important scintigraphic findings in the present case should serve to exclude the other differential possibilities mentioned above. First, the uptake distribution differs from that in reported cases of hypertrophic pulmonary osteoarthropathy. The periosteal changes in thyroid acropachy are usually confined to the hands and wrists and only rarely occur in the long bones (1). By contrast, in hypertrophic pulmonary osteoarthropathy, while the wrist and hands may be involved, the dominant involvement is usually in the long bones of the extremities (6).

Second, the small tubular bones of the hands that are involved in thyroid acropachy show abnormal tracer localization only in the diaphyseal regions. Normally, the metacarpal-phalangeal and interphalangeal joints show greater skeletal tracer concentration than the diaphyseal areas. In rheumatoid arthritis and in primary and secondary hyperparathyroidism, the periarticular concentration is further accentuated relative to the diaphyseal activity. In osteoarthritis, involvement of the distal interphalangeal joints is characteristic, and again the activity in the diaphyses is less than in the involved joints (7).

The third distinguishing scintigraphic feature observed in this patient is the diffuse uptake of the



FIG. 2. Posterior view of ^{99m}Tc -pyrophosphate scan reveals diffusely increased bilateral tracer localization in areas of myxedema.

skeletal tracer in both areas of pretibial myxedema. Pretibial myxedema is commonly associated with thyroid acropachy: it was present in 10 out of 13 patients in one series (4). Although the concentration of tracer in the pretibial myxedema is not specific, none of the differential possibilities other than thyroid acropachy would be expected to show this pattern of extraskeletal tracer concentration.

Skeletal scintigraphy is more sensitive than radiography in the early detection of several types of bone disease (5,7). Interestingly, in this case ^{99m}Tc -pyrophosphate accumulated in several bones that were radiographically normal. In thyroid acropachy, bone scans may well be the most sensitive indicator of disease. The bone scan also provides a potentially sensitive objective test for following the activity of the skeletal and soft-tissue disturbances.

In the clinical setting of a patient with a recent history of hyperthyroidism, the diagnosis of thyroid acropachy is usually straightforward. However, the distinctive skeletal and soft-tissue scintigraphic abnormalities of thyroid acropachy may help to identify the disease process in some cases where a long interval has elapsed between the treatment of the hyperthyroidism and the development of the clinical syndrome of thyroid acropachy.

REFERENCES

1. GIMLETTE TM: Thyroid acropachy. *Lancet* 1: 22-24, 1960
2. MCANULTY JH, SISSON JC: Thyroid acropachy: Improvement with time. *Univ Mich Med Cent J* 38: 154-156, 1972
3. SCANLON GT, CLEMETT AR: Thyroid acropachy. *Radiology* 83: 1039-1042, 1964
4. KING LR, BRAUNSTEIN H, CHAMBERS D, et al.: A case study of peculiar soft-tissue and bony changes in association with thyroid disease. *J Clin Endocrinol Metab* 19: 1323-1330, 1959
5. DONNELLY B, JOHNSON PM: Detection of hypertrophic pulmonary osteoarthropathy by skeletal imaging with ^{99m}Tc -labeled diphosphonate. *Radiology* 114: 389-391, 1975
6. KAY CJ, ROSENBERG MA: Positive ^{99m}Tc -polyphosphate bone scan in a case of secondary hypertrophic osteoarthropathy. *J Nucl Med* 15: 312-313, 1974
7. DESAULNIERS M, FUKS A, HAWKINS D, et al.: Radiotechnetium polyphosphate joint imaging. *J Nucl Med* 15: 417-423, 1974
8. ROSENTHALL L, KAYE M: Technetium-99m-pyrophosphate kinetics and imaging in metabolic bone disease. *J Nucl Med* 16: 33-39, 1975
9. SHAWARBY K, IBRAHIM MS: Pachydermoperiostosis: A review of the literature and report on four cases. *Br Med J* 1: 763-766, 1962
10. BIELER E, ALBRECHT AJ: Das szintigraphische Bild der Osteoarthropathie hypertrophiante. *Nucl Med (Stuttg)* 10: 196-200, 1971

**1st ANNUAL WESTERN REGIONAL MEETING
THE SOCIETY OF NUCLEAR MEDICINE**

October 1-3, 1976

Fairmont Hotel

San Francisco, Calif.

Members and friends are invited to attend this meeting sponsored by the chapters of Northern California, Southern California, the Pacific Northwest, and Hawaii. The Scientific Program Committee is preparing a program which includes selected papers as well as lectures by noted scientists. One of the latter is Nobel laureate Emilio Segré. Abstracts will be printed in the program booklet to be distributed to each registrant at the meeting.

We look forward to seeing as many of our friends as possible in San Francisco in the best season of the year.

For registration forms and hotel reservation cards, please write or phone:

**Jean Lynch
Western Regional Coordinator
P.O. Box 40279
San Francisco, CA 94140
(415) 647-1668 or (415) 647-0722**