

TABLE 1. INCIDENCE OF ONLY SKULL AND EXTREMITY ABNORMALITIES DETECTED WITH $^{99m}\text{Tc-Sn-HEDP}$ IN NONOSSEOUS MALIGNANT NEOPLASMS

Bone scan indication	Total	Abnormal	Skull	Extremities
Breast	368	247	12 (5%)	14 (6%)
Lung	230	147	2 (1%)	14 (10%)
Prostate	191	119	2 (2%)	11 (9%)
Hodgkin's	58	29	0	1 (3%)
Lymphoma	42	16	0	2 (12%)
Cervix	41	23	3 (13%)	4 (17%)
Rhabdomyo-sarcoma	39	22	1 (4%)	6 (27%)
Colon	37	21	3 (14%)	2 (10%)
Kidney	35	21	2 (10%)	3 (14%)
Bladder	35	15	1 (7%)	0
Melanoma	30	17	5 (29%)	4 (24%)
Rectum	23	14	0	1 (4%)
Thyroid	14	6	0	0
Total	1143	697	31 (4%)	62 (9%)

abnormalities without abnormal axial uptake of the bone agent ($^{99m}\text{Tc-Sn-HEDP}$).

We have retabulated our clinical data to determine the number of cases in which the only abnormality was reported in the skull or the extremities (Table 1). The overall incidence for solitary skull uptake was 4% and that for solitary extremity uptake was 9%. For solitary uptake in the extremities, upper involvement was limited to the humeri (15%), with one report of a solitary abnormality in the hand. The remaining solitary abnormalities in the extremities (85%) were distributed 70% to femora and 30% to tibias or fibulas.

The 5–10% incidence of skull or extremity uptake without involvement of the axial skeleton reemphasizes the desirability of whole-body scintiscans.

ANDREW J. TOFE
MARION D. FRANCIS
WILLIAM J. HARVEY
Miami Valley Laboratories
Procter & Gamble Company
Cincinnati, Ohio

REFERENCE

1. TOFE AJ, FRANCIS MD, HARVEY WJ: Correlation of neoplasms with incidence and localization of skeletal metastases: An analysis of 1,355 diphosphonate bone scans. *J Nucl Med* 16: 986–989, 1975

Cellular Site of $^{99m}\text{TcO}_4$ Secretion in the Stomach

I would like to comment on a letter to the editor by T. K. Chaudhuri (1) concerning the cellular site of the secretion of $^{99m}\text{TcO}_4$ in the stomach. The work of Meier-Ruge and Fridrich (2) was not quoted in its entirety. Their experiments not only showed selective secretion of pertechnetate by the parietal cells, but also a predominant secretion of iodide by the chief cells, with only small amounts of iodide

being secreted by the parietal and mucus-secreting cells. This is astonishing in view of the many physiologic similarities between iodide and pertechnetate. Because of this contrasting behavior of iodide and pertechnetate in the stomach, Meier-Ruge and Fridrich suggested that microautoradiography should be used with both tracers to distinguish parietal from chief cells.

I agree that further studies regarding the distribution of iodide and pertechnetate in the gastric mucosa are badly needed. A better understanding of the gastric excretion of pertechnetate might also offer an explanation for the disturbing observation that not all gastric-type mucosa contained in Meckel's diverticula are visualized by pertechnetate scanning (3–5).

PETER F. WINTER
Columbia-Presbyterian Medical Center
New York, New York

REFERENCES

1. CHAUDHURI TK: Cellular site of secretion of $^{99m}\text{TcO}_4$ in the stomach—A controversial point. *J Nucl Med* 16: 1204–1205, 1975
2. MEIER-RUGE W, FRIDRICH R: Die Verteilung von Technetium-99m und Jod-131 in der Magenschleimhaut. Ein Beitrag zur Methodik der Mikrohistaautoradiographie wasserlöslicher Isotope. *Histochemie* 19: 147–154, 1969
3. DUSZYNSKI DO, JEWETT TC, ALLEN JE: Tc^{99m} Na pertechnetate scanning of the abdomen with particular reference to small bowel pathology. *Am J Roentgenol Radium Ther Nucl Med* 113: 258–262, 1971
4. LEONIDAS JC, GERMANN DR: Technetium-99m pertechnetate imaging in the diagnosis of Meckel's diverticulum. *Arch Dis Child* 49: 21–26, 1974
5. WINTER PF: Unpublished data, 1975

Reply

I appreciate Dr. Winter's comments on our article (1). Since our major interest was the cellular localization of $^{99m}\text{TcO}_4$ in the stomach, we did not feel it necessary to dis-

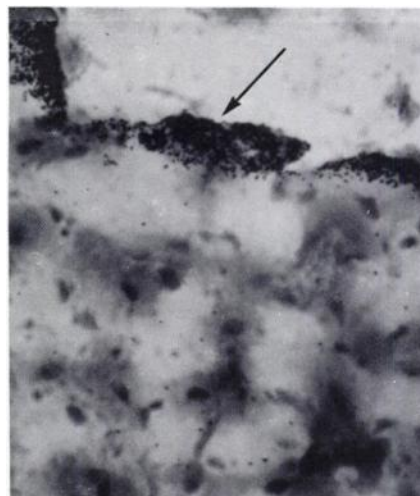


FIG. 1. Autoradiograph ($\times 800$) of gastric mucosa of mouse (taken 15 min after injection of ^{99m}Tc -pertechnetate) shows localization of grains predominantly in mucus-secreting cells (arrow) of surface mucosa. Parietal and chief cells show very few or no silver grains.

cuss the gastric handling of iodide. Also, since we had been working on gastric autoradiography using $^{99m}\text{TcO}_4$, we were concerned with $^{99m}\text{TcO}_4$ only. This is why the iodide part of Meier-Ruge and Fridrich's work (2) was not quoted in our communication. The gastric metabolism of iodide will be the subject of a later communication.

With regard to the cellular site of $^{99m}\text{TcO}_4$ secretion in the stomach, we have obtained further results which we would like to mention here. So far, we have used autoradiography to determine the cellular localization of $^{99m}\text{TcO}_4$ in the stomachs of mice, rats, cats, and dogs. We have found that $^{99m}\text{TcO}_4$ is predominantly handled by the mucus-secreting cells (Fig. 1): heavy grain concentration was observed at the mucus lining, and few or no grains were detected in the parietal and chief cells. These findings are in accord with those of Marsden et al. (3) and Berquist et al. (4), but they disagree with those of Meier-Ruge and Fridrich (2). Our results explain why gastric tissue in Barrett's esophagus, which lacks parietal cells, accumulates $^{99m}\text{TcO}_4$ (4) and why the gastric antrum, also devoid of parietal cells, secretes $^{99m}\text{TcO}_4$ (5).

TAPAN K. CHAUDHURI
Veterans Administration Center and
Eastern Virginia Medical School
Hampton, Virginia

REFERENCES

1. CHAUDHURI TK: Cellular site of secretion of $^{99m}\text{TcO}_4$ in the stomach—A controversial point. *J Nucl Med* 16: 1204–1205, 1975
2. MEIER-RUGE W, FRIDRICH R: Die Verteilung von Technetium-99m und Jod-131 in der Magenschleimhaut. *Histochemie* 19: 147–154, 1969
3. MARSDEN DS, ALEXANDER C, YEUNG P, et al.: Autoradiographic explanation for the uses of ^{99m}Tc in gastric scintiphography. *J Nucl Med* 14: 632, 1973
4. BERQUIST TH, NOLAN NG, STEPHENS DH, et al.: Radioisotope scintigraphy in diagnosis of Barrett's esophagus. *Am J Roentgenol Radium Ther Nucl Med* 123: 401–411, 1975
5. CHAUDHURI TK, CHAUDHURI TK, SHIRAZI SS, et al.: Radioisotope scan—A possible aid in differentiating retained gastric antrum from Zollinger–Ellison syndrome in patients with recurrent peptic ulcer. *Gastroenterology* 65: 697–698, 1973

Resolution Limit of Positron Cameras

Two recent publications (1,2) in the *Journal of Nuclear Medicine* have discussed the loss of spatial resolution in positron imaging devices due to the varying range of positrons of different energies in tissue or tissue-equivalent material. While this loss of resolution is fundamental in nature and will indeed influence to a large degree the ultimate achievable resolution, particularly at high positron energies, a second equally fundamental effect, which in many camera configurations results in a more serious loss of resolution, deserves mention.

Due to the motion of the center of mass of an annihilating pair, the two back-to-back 511-keV photons formed upon annihilation are not emitted at exactly 180° with respect to each other (3). The angular spread leads to a distribution that is roughly Gaussian in shape with a full width at half maximum (FWHM) of 0.6° . This effect can be particularly significant for a system with a large detector-

to-detector separation: for a positron source midway between two detector arrays separated by 80 cm, an angular spread of 0.6° results in a distribution which has a FWHM of 4.2 mm at the detector. The resulting error in reconstructing the location of the source will depend upon the particular geometry (size of detectors, position sensitive or discrete, etc.). Nevertheless, for many systems it will contribute approximately 2 mm (FWHM) to the system resolution.

While this effect is more significant than the positron range effect for most positron-emitters, it does not seriously degrade the resolution of existing positron imaging devices which have system resolutions between 8 and 11 mm FWHM.

G. MUEHLEHNER
Searle Analytic, Inc.
Searle Radiographics, Inc.
Des Plaines, Illinois

REFERENCES

1. PHELPS ME, HOFFMAN EJ, HUANG SC, et al.: Effect of positron range on spatial resolution. *J Nucl Med* 16: 649–652, 1975
2. CHO ZH, CHAN JK, ERICKSSON L, et al.: Positron ranges obtained from biomedically important positron-emitting radionuclides. *J Nucl Med* 16: 1174–1176, 1975
3. DE BENEDETTI S, COWAN CE, KONNEKER WR, et al.: On the angular distribution of two-photon annihilation radiation. *Phys Rev* 77: 205–212, 1950

Reply No. 1

Our paper on the effect of positron range on spatial resolution (1) was meant to point out the role of this single factor in the spatial resolution of positron imaging systems. For example, the line spread functions (LSFs) from the positron ranges of ^{18}F (0.633 MeV), ^{11}C (0.929 MeV), ^{67}Ga (1.90 MeV), and ^{86}Rb (3.15 MeV) have values at the full width half maximum (FWHM) and tenth maximum (FWTM) of 0.14 and 0.8 mm, 0.33 and 1.3 mm, 0.44 and 3.1 mm, and 0.61 and 5.6 mm, respectively (1,2). When these positron-range LSFs are convoluted with detector LSFs which have FWHM resolutions of 8–10 mm (FWTM of 15–18 mm), the positron-range effects are very small (1–3). However, as the inherent detector resolution is improved, the higher positron energies of ^{67}Ga and ^{86}Rb become more important. If a detector resolution of 4.0 mm FWHM and 7.3 mm FWTM is convoluted with the β^+ range LSF of ^{86}Rb , the resulting FWHM and FWTM are 4.6 mm and 9.2 mm, respectively. Thus, at a detector resolution of 4 mm FWHM, the positron ranges of some radiopharmaceuticals become appreciable, but they are still not very significant factors in image resolution.

As a result of previous discussions with Muehlechner and Buchin concerning the effect of the angular distribution of annihilation radiation on spatial resolution, we have investigated this effect (2). As Muehlechner states, the two 511-keV annihilation photons are not always emitted at 180° in a laboratory frame of reference (i.e., as opposed to the center-of-mass reference) (4). The shape of the angular distribution approximates an inverted parabola centered at 180° . The width of the distribution is a function of many variables and is particularly ambiguous for in vivo radiopharmaceuticals. Because of the heterogeneity of the body composition and the range of the β^+ , the local environment in which annihilation occurs is impossible to define. Never-