Lung Scintigraphy with ^{51}Cr-Erythrocytes in Goodpasture's Syndrome: Case Report

Rikushi Morita, Katsuji Ikekubo, Harumi Ito, Toru Mori, Ken Hamamoto, and Kanji Torizuka

Kyoto University School of Medicine, Kyoto, Japan

A lung scan using ^{51}Cr-labeled erythrocytes in a patient with Goodpasture's syndrome revealed radioactivity in the lung due to massive intrapulmonary hemorrhage.

J Nucl Med 17: 702–703, 1976

Goodpasture's syndrome is a disease in which recurrent episodes of pulmonary hemorrhage and anemia are accompanied by progressive glomerulonephritis. We performed lung scintigraphy with ^{51}Cr-labeled erythrocytes in a patient with Goodpasture's syndrome, and this procedure confirmed the x-ray evidence of massive intrapulmonary hemorrhage.

CASE REPORT

A 23-year-old Japanese woman was admitted on March 15, 1974, with cough, fever, anemia, and bloody urine of 10 days duration. She had a history of Graves' disease and had been taking methimazole. In August 1972 she had been hospitalized for cough, fever, bloody urine, and severe anemia. Methimazole was discontinued, and blood transfusion and steroid therapy were administered with subsequent clinical improvement. She was then prescribed propylthiouracil until June 1973, when a partial thyroidectomy was done. For the next 2 years she had recurrent sudden episodes of bloody urine, fever, and cough. There was no previous history of hemoptysis or bloody sputum.

On the present admission, she was quite pale and appeared chronically ill. Her blood pressure and pulse rate were within normal limits. Diffuse crepitations were audible over both lungs, and a chest x-ray showed diffuse mottled opacity over both lungs (Fig. 1). Blood studies gave pO_2 = 66 mm Hg, pCO_2 = 34 mm Hg, and pH = 7.40. The sputum contained macrophages laden with hemosiderin, and repeated cultures produced only normal organisms. Hemoglobin level was 6.9 gm per 100 ml, hematocrit 21%, and serum iron 75 μg per 100 ml. Detailed coagulation studies, mechanical and osmotic erythrocyte fragilities, lupus erythematosus cells, antinuclear factor, rheumatoid factor, Coombs' test, and cold agglutinins were all within normal limits. The urine contained protein, many erythrocytes, and granular and erythrocyte casts. The intravenous pyelogram was normal. The creatinine clearance was 31.6%. Renal plasma flow was 341 ml/min, glomerular filtration rate was 42 ml/min, and the filtration fraction was 0.12 as estimated with ^{131}I-hippuran and ^{131}I-iothalamate.

On the 3rd day after admission, 300 μCi of ^{51}Cr-labeled autologous erythrocytes was injected intravenously. Radioactivity was measured daily for 15 days by point counting over the right lung, liver, spleen, and sacrum, with correction for physical decay. Counts over the right lung showed a marked increase, whereas those over the liver, spleen, and sacrum stayed within the low normal range. Three days after the administration of ^{51}Cr-erythrocytes, lung scintigraphy was carried out with a dual-probe rectilinear scanner using a 5-in. coarse-focus medium-energy collimator. The scanning speed was adjusted to give an information density of 500 counts/cm^2. The scintigram showed diffuse uptake of the radionuclide throughout both lungs (Fig. 2); areas of markedly increased radioactivity were seen in the right upper lung, corresponding to the confluent opacities seen on the chest x-ray. The survival half-time for the ^{51}Cr-tagged circulating erythrocytes was markedly reduced (7.8 days).

On the 20th day, 10 μCi of ^{59}Fe-transferrin was injected intravenously and iron kinetics was studied. The half-time for ^{59}Fe clearance from plasma was 27 min, the plasma iron turnover rate was 1.58 mg/

Received Aug. 6, 1975; revision accepted Feb. 16, 1976.

For reprints contact: R. Morita, Dept. of Nuclear Medicine, University Hospital, Kyoto University, Kyoto 606, Japan.

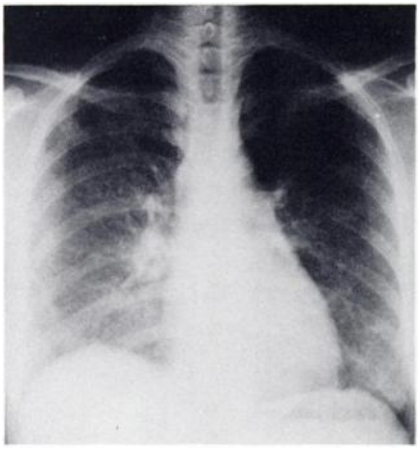

FIG. 1. Chest radiogram shows characteristic bilateral nodular infiltrative process, more nearly confluent in right upper lung field.

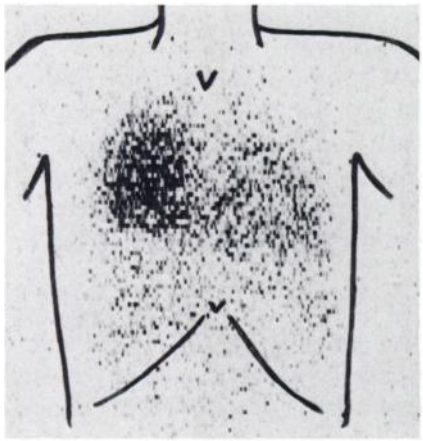

FIG. 2. Anterior chest scintigram shows diffuse uptake of radiochromium throughout both lungs, markedly increased in right upper lung field.

kg per day, and 100% of the ^{59}Fe was incorporated into the red blood cells. Radioactive counts for ^{59}Fe were also determined daily for 15 days over the right lung, sacrum, spleen, and liver and were corrected for physical decay. Counts over the right lung continued to increase, in contrast to the liver, spleen, and sacrum, all of which showed a gradual decrease in activity.

Treatment with prednisolone (40 mg daily) was started on the 5th day, followed by clinical improvement. The radiographic abnormality in the chest improved and urinalysis eventually showed only a trace of protein. The steroid was prescribed for continued daily use and the patient was discharged. She was readmitted on November 22, 1975, with an acute exacerbation of hemoptysis and urinary bleeding, and she died on the 3rd day after admission. Review of the autopsy sections of the lung showed extensive intra-alveolar hemorrhage and hemosiderin-laden macrophages. The kidney showed a diffuse proliferative glomerulonephritis with many epithelial crescents. There was no evidence of significant vasculitis. Immunologic studies showed a linear distribution of fluorescent antibody to gamma-globulin both in the alveolar septa and in the glomerular basement membrane.

DISCUSSION

Evidence for hemoptysis in Goodpasture's syndrome is abundant. Erythrocyte studies with ^{51}Cr variously report normal (*1*) and reduced (*2*) survival half-times; in the latter report, the shortened erythrocytic life span was ascribed to the loss of these erythrocytes into the lungs. In our case, the survival half-time for ^{51}Cr-erythrocytes was markedly reduced (7.8 days), and the ^{51}Cr activity in the lung continued to rise, while the liver and spleen activities remained within normal limits for the 15-day period of study. These findings indicated intrapulmonary hemorrhage. The ^{59}Fe activity in the lung also continued to increase during the period of examination.

Our data parallel those of other authors concerning ^{59}Fe organ distribution (*2,3*). Studies with ^{59}Fe are noninvasive techniques to show intrapulmonary hemorrhage, but they are time-consuming and are especially distressing for severely ill patients since they require daily counting for at least 15 days. The scintigram, obtained 3 days after the administration of ^{51}Cr-erythrocytes and during the phase of acute pulmonary hemorrhage, revealed the locations and extent of the on-going hemorrhage more clearly than the chest x-rays. The advantages of pulmonary scintigraphy with ^{51}Cr-erythrocytes in patients with intrapulmonary hemorrhage are that it provides useful information regarding the sites of on-going bleeding in the lungs and it is safer and technically easier than lung biopsy.

ACKNOWLEDGMENT

Thanks are due to M. Ohara of Kyoto University for assistance with the manuscript.

REFERENCES

1. Elder JL, Kirk GM, Smith WG: Idiopathic pulmonary haemosiderosis and the Goodpasture syndrome. *Br Med J* 2: 1152–1155, 1965

2. Apt L, Pollycove M, Ross JF: Idiopathic pulmonary hemosiderosis. Study of anemia and iron distribution using radioiron and radiochromium. *J Clin Invest* 36: 1150–1159, 1957

3. Azen EA, Clatanoff DV: Prolonged survival in Goodpasture's syndrome. *Arch Intern Med* 114: 453–460, 1964