Salivary Gland Uptake of ^{67}Ga-Citrate Following Radiation Therapy

Carlos Bekerman and Paul B. Hoffer

University of Chicago, Chicago, Illinois

Radiogallium uptake in the salivary glands is strongly correlated with prior therapeutic radiation which includes the cervical region. Fifteen of 17 patients with increased salivary gland uptake had such a history. An easily identified characteristic pattern of symmetric localization of ^{67}Ga occurs in the parotid and submandibular regions in these patients. This pattern must not be mistaken for recurrent tumor in the cervical region.

J Nucl Med 17: 685–687, 1976

Localization of ^{67}Ga-citrate in lymph nodes involved with Hodgkin's disease was first reported in 1969 by Edwards and Hayes (*1*). Since then, numerous investigators have confirmed the value of ^{67}Ga-citrate scans in the staging of Hodgkin's disease and certain other lymphomas (*2–6*). Recently, greater emphasis has been placed on the use of such diagnostic methods as ^{67}Ga imaging for the staging and early detection of tumor recurrence after therapy (*7*). A dramatic improvement in the survival rate of patients with Hodgkin's disease or other malignant lymphomas has been achieved with these more rigorous staging and treatment regimens. However, any changes in the distribution of ^{67}Ga-citrate in post-treatment scans must be carefully assessed if one is to determine whether these changes represent eradication, incomplete control, recurrence of disease, or benign changes induced by radiation or chemotherapy.

We have frequently observed salivary gland uptake of ^{67}Ga-citrate in scans performed on patients with Hodgkin's disease and malignant lymphomas following radiation therapy. Uptake in these areas may be confused with cervical node activity. Our purpose in this study was to determine whether there is an association between radiation therapy and increased salivary gland activity as seen on ^{67}Ga-citrate scans.

MATERIALS AND METHODS

Whole-body radiogallium scans were performed on 520 patients between January 1, 1974, and December 31, 1974. In these studies, 3–5 mCi of ^{67}Ga-citrate was administered intravenously 72 hr before scanning. (Currently we use a 10-mCi dose of ^{67}Ga-citrate for tumor evaluation in patients with tissue-proven malignancy.) The patients were given 60 cm^3 of castor oil on the evening before the scan and a cleansing enema a few hours before scanning. These scans were made on an Ohio-Nuclear rectilinear scanner with dual-probe 5-in. detectors. Three independent pulse-height analyzers were used with each detector to facilitate simultaneous detection of the 93-keV, 184-keV, and 296-keV photon emissions of ^{67}Ga. A medium-energy 38H collimator with a focal depth of 9 cm was used.

All scans were evaluated for the presence of symmetric activity in the cervical region consistent with salivary gland localization of ^{67}Ga-citrate.

RESULTS

In 17 of the 520 patients whose scans were reviewed, the salivary glands appeared to have increased uptake of the radionuclide. Thirteen of these 17 were men and four were women. Their ages ranged from 9 to 62 years. The patients' clinical and histologic diagnoses are listed in Table 1. Retrospective analysis of hospital charts showed that 15 of the 17 patients had previous radiation therapy. Fourteen of the 15 patients had had a ^{67}Ga scan prior to radiation therapy without evidence of increased salivary gland uptake (Fig. 1).

Received Nov. 14, 1975; revision accepted Jan. 30, 1976.

For reprints contact: Carlos Bekerman, Dept. of Radiology, University of Chicago, 950 East 59th St., Chicago, IL 60637.

TABLE 1. PATIENTS GROUPED BY CLINICAL AND HISTOLOGIC DIAGNOSIS

Hodgkin's Disease	
Nodular sclerosing type	10
Mixed cell type	3
Malignant Lymphomas	
Poorly differentiated lymphocytic lymphoma, nodular	1
Histiocytic lymphoma, diffuse	1
Systemic Lupus Erythematosus	1
Chronic Renal Failure	1
Total	17

The 15 radiogallium scans that showed bilateral symmetric cervical uptake of ^{67}Ga after radiation therapy also showed a characteristic bilateral accumulation of activity in the parotid glands. Increased uptake was seen in the submandibular regions, which were best visualized on the anterior projections. Lateral views of the head and neck (obtained in five cases) clearly showed that the areas of increased activity corresponded to the salivary glands (Fig. 2). Eleven of these 15 patients had additional postirradiation whole-body ^{67}Ga scans. The relative distribution of these scans, as a function of the time after radiation therapy, is given in Table 2. The activity in the parotid glands was relatively higher in the scans performed within 1 year after irradiation than in those performed in the subsequent years. No such relative decrease in activity was noted for the submandibular salivary glands.

A review of the radiation records revealed that, in 12 patients, the neck had been irradiated as part of an extended mantle field, with a total dose of approximately 4,000 rads delivered within 4–6 weeks. One patient received an additional 3,000 rads to the left cervical and supraclavicular region. In two patients, the oropharynx and upper neck were irradiated with opposing fields, with a total dose of 5,000 rads in 44 days. One patient had been treated at another institution with multiple portals, including the mediastinum, neck, axillary region, and epigastrium. All the patients had complained of oral discomfort such as dry mouth, swelling of the salivary glands, and loss of taste during the first 6 months after radiation therapy. Three patients had intercurrent buccal infections during the period of irradiation. At the time of the scan, no clinical evidence of tumor recurrence was found in the cervical region in any of the 15 patients.

No other type of therapy was found to be clearly associated with the increased uptake of ^{67}Ga-citrate by the salivary glands. Only two unirradiated patients showed bilateral salivary gland uptake of radiogallium on scan. The clinical diagnosis was chronic renal failure in one and systemic lupus erythematosus in the other.

DISCUSSION

Increased uptake of ^{67}Ga-citrate in the salivary glands after radiation therapy has been suggested previously but has not been well documented (*8,9*). No examples of this condition are given in the various descriptions of the normal distribution of this tracer (*10,11*). In 1911, Bergonie and Speder (*12*) reported 10 cases of salivary gland swelling within a few hours of irradiation. Evans and Ackerman (*13*) found that radiation changes in the salivary glands could result in the false clinical impression of cervical lymph-node metastases several months after radiation therapy. Rubin and Casarett (*14*) have described the clinical course, symptoms, and histologic changes in the salivary glands after ex-

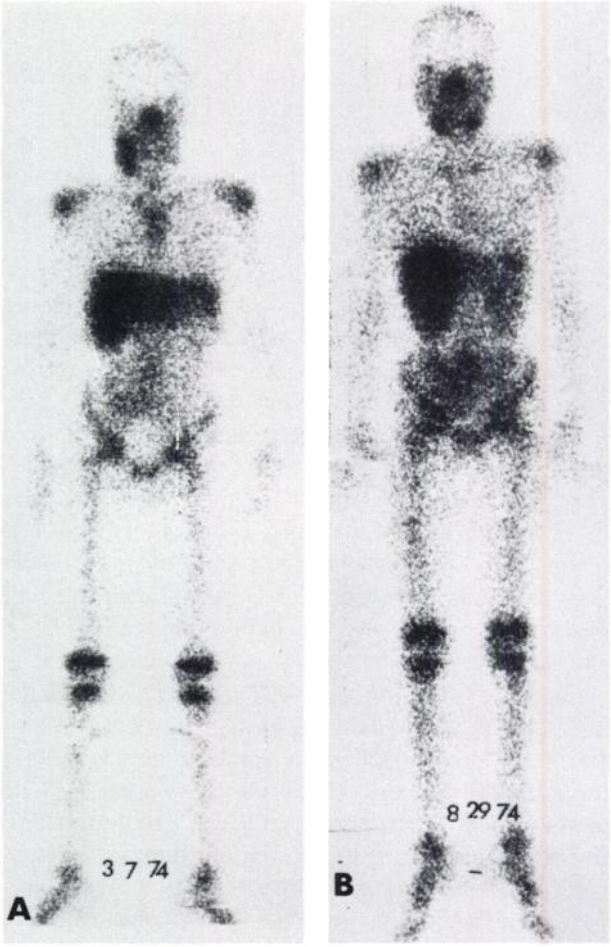

FIG. 1. (A) Gallium scan on 11-year-old child with Hodgkin's disease, performed before radiation therapy, shows mediastinal and right cervical lesions. Epiphyseal uptake is also seen. (B) Gallium scan on same patient after radiation therapy (4,000 rads in 4 weeks) shows bilateral salivary gland uptake. No clinical evidence of recurrence was present. This case is typical of 14 patients with scans before and after radiation therapy.

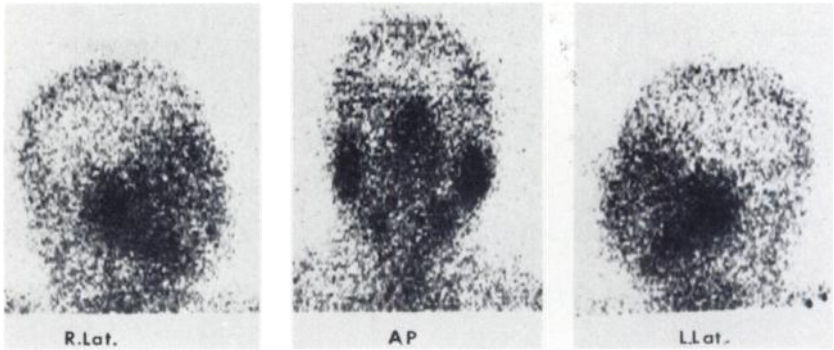

FIG. 2. Lateral and anterior projections of head and neck show increased activity in salivary glands.

TABLE 2. NUMBER OF SCANS PERFORMED AT VARIOUS INTERVALS AFTER RADIATION THERAPY

Acute clinical period (first 6 months)	12
Subacute clinical period (second 6 months)	9
Chronic clinical period (2–5 years)	5
Late clinical period (after 5 years)	0
Total	26

posure to radiation. The pathologic changes observed depend directly upon the quantity of radiation, the mode of irradiation (single or fractionated doses), and the time elapsed after radiation therapy.

The small-vessel endothelium of the salivary glands is moderately radiosensitive. Following irradiation, the permeability of the endothelium is increased, which leads to interstitial edema and perivascular inflammation and which directly affects the parenchymal cells. Interstitial fibrosis with infiltration by lymphoid and other "chronic" inflammatory cells occurs within 6 months after therapy. The increased accumulation of ^{67}Ga-citrate in the salivary glands observed in the 12 scans during the acute period following radiation therapy (up to 6 months) may be explained by the vascular and cellular changes described by Rubin and Casarett (*14*). From the sixth to twelfth month after irradiation (subacute phase), the inflammatory changes previously described are still present but are less pronounced. These changes could account for the lesser extent of ^{67}Ga-citrate uptake by the parotid glands seen in the scans performed during this period. The absence of clinical evidence of recurrent tumor in the cervical region at the time the scans were performed supports the conclusion that the increased uptake of radiogallium by the salivary glands is directly related to the changes produced by irradiation.

The increased activity in the salivary glands observed in two unirradiated patients could be explained by the vascular changes known to occur in the salivary glands in systemic lupus erythematosus and by the frequent intercurrent oral infections and parotitis in patients with chronic renal failure.

REFERENCES

1. Edwards CL, Hayes RL: Tumor scanning with ^{67}Ga-citrate. *J Nucl Med* 10: 103–105, 1969

2. Greenlaw RH, Weinstein MB, Brill BA, et al.: ^{67}Ga-citrate imaging in untreated malignant lymphoma: Preliminary report of Cooperative Group. *J Nucl Med* 15: 404–407, 1974

3. Hoffer PB, Turner D, Gottschalk A, et al.: Whole-body radiogallium scanning for staging of Hodgkin's disease and other lymphomas. In *International Symposium on Hodgkin's Disease. Stanford University School of Medicine, Stanford, California, March 20–24, 1972.* National Cancer Institute Monograph No 36, 1973, pp 277–285

4. Johnston G, Benua RS, Teates CD, et al.: ^{67}Ga-citrate imaging in untreated Hodgkin's disease: Preliminary report of Cooperative Group. *J Nucl Med* 15: 399–403, 1974

5. Turner DA, Pinsky SM, Gottschalk A, et al.: The use of ^{67}Ga scanning in the staging of Hodgkin's disease. *Radiology* 104: 97–101, 1972

6. Turner DA, Gottschalk A, Hoffer PB, et al.: Gallium-67 scanning in the staging of Hodgkin's disease. In *Medical Radioisotope Scintigraphy, 1972,* vol 2. Vienna, IAEA, 1973, pp 615–630

7. Henkin RE, Polcyn RE, Quinn JL: Scanning treated Hodgkin's disease with ^{67}Ga-citrate. *Radiology* 110: 151–154, 1974

8. Richman SD, Levenson SM, Jones AE, et al.: Radionuclide studies in Hodgkin's disease and lymphomas. *Semin Nucl Med* 5: 103–118, 1975

9. Frankel RS, Jones AE, Cohen JA, et al.: Clinical correlations of ^{67}Ga and skeletal whole-body radionuclide studies with radiography in Ewing's sarcoma. *Radiology* 110: 597–603, 1974

10. Johnston GS, Jones AE, eds: *Atlas of Gallium-67 Scintigraphy.* New York, Plenum, 1973

11. Larson SM, Milder MS, Johnston GS: Interpretation of the ^{67}Ga-photoscan. *J Nucl Med* 14: 208–214, 1973

12. Bergonie J, Speder E: Sur quelques formes de réactions précoces après des irradiations röntgen. *Arch Elect Med* 19: 241–245, 1911

13. Evans JC, Ackerman LV: Irradiated and obstructed submaxillary salivary glands simulating cervical lymph node metastases. *Radiology* 62: 550–555, 1954

14. Rubin P, Casarett GW: *Clinical Radiation Pathology.* Philadelphia, W. B. Saunders, 1968, chap. 7