

Radionuclide Venography: Significance of Delayed Washout; Visualization of the Saphenous System

U. Yun Ryo, Lelio G. Colombetti, Stanton G. Polin, and Steven M. Pinsky

Michael Reese Medical Center and Pritzker School of Medicine, University of Chicago, Chicago, Illinois

Venograms were obtained on dogs in which venous thrombosis had been surgically induced. Radionuclide venograms, obtained after injection of ^{99m}Tc-labeled microspheres or macroaggregated albumin, showed decreased radioactivity over the areas of venous thrombosis and increased radioactivity over areas of venous stasis. Scintigrams of veins excised after an injection of labeled particles did not delineate thrombi, areas of crush-injured vein, or the venous valves. Delay in the washout of radioactivity on a venogram indicates stasis due to impeded venous flow in the area of thrombosis. A modified technique was developed to obtain simultaneous images of the superficial and deep veins of the leg. Visualization of the superficial veins not only permits detection of superficial abnormalities, but also assists interpretation of the venographic observations of the deep veins.

J Nucl Med 17: 590-595, 1976

Since the introduction of radionuclide venography (1,2), its simplicity, effectiveness, and speed have made it useful in the evaluation of thrombosis of the deep veins of the pelvis and lower extremities (3,4). The procedure is simple because deep veins can be visualized after an injection of labeled albumin particles through the dorsal vein of the foot. Several reports testify to the effectiveness of the technique in showing areas of deep-vein thrombosis and consequent collateral blood flow (3-6). The speed of the procedure is shown by the fact that the results are available within 30 min after beginning the study.

Henkin et al (3) reported almost 100% agreement between radionuclide venograms and contrast phlebograms, and other published studies cite hot spots on the radionuclide venogram as evidence of venous thrombi (1,4,7). In numerous cases, however, venographic findings have failed to correlate with those of contrast phlebography, and the reason for this has yet not been elucidated (2,3,6,8). In our series of radionuclide venographic studies, we have experienced a considerable number of false-positive findings: cases of marked retention of radioactivity in a calf vein in which contrast phlebograms later showed venous insufficiency without any evidence of thrombophlebitis.

We attempted in this study to elucidate the mechanism(s) of positive findings by correlating radionuclide venograms with venous thrombi and endothelial injuries produced experimentally in dogs. This study also presents a technique that can show all normal and abnormal leg veins, both superficial and deep. Visualization of the superficial veins (the saphenous system) facilitates interpretation of radionuclide venograms.

METHODS

Animal experiments. Mongrel dogs of either sex, weighing 10-15 kg, were used. In five anesthetized dogs, the femoral veins of both legs were surgically exposed. Two areas of the wall of the common femoral vein were sutured with thrombin-soaked surgical silk (No. 30) to induce formation of a thrombus. A large surgical needle holder was used to induce a crush injury on an area of the venous wall at the junction of the common femoral vein and the long saphenous vein. Twenty-four hours

Received April 14, 1975; revision accepted Jan. 21, 1976.

For reprints contact: U. Yun Ryo, Michael Reese Hospital and Medical Center, Div. of Nuclear Medicine, 2901 S. Ellis Ave., Chicago, IL 60616.

TABLE 1. RESULTS OF RADIONUCLIDE VENOGRAPHY AND POSTMORTEM EXAMINATION OF DOGS

Dog No.	Leg*	Radionuclide venogram findings	Postmortem findings
1	R	Decreased activity over suture sites. Marked persistent retention of activity in deep veins below surgical site.	Large thrombi at suture sites. Venous lumen partially occluded. Large hematoma at surgical site.
	L	Decreased activity over suture sites. Clearance delayed between suture sites.	Small thrombus at lower suture site.
2	R	Clearance slightly delayed below upper suture site. Activity markedly retained in lower leg.	Multiple clots at suture sites. Venous lumen partially occluded.
	L	Five areas of retention; retention most pronounced between upper and lower suture sites.	Large thrombus at upper suture site. Smaller thrombus at lower site. Venous lumen partially occluded.
3	R	Decreased activity over both suture sites. Collateral flow from knee to proximal end of common femoral vein.	Large thrombi at both suture sites. Lumen partially occluded. Medium-sized hematoma at surgical site.
	L	Slight retention at distal part of femoral vein. Decreased activity over surgical site. Markedly increased activity below suture site.	Small thrombus at upper suture site. About 20 ml of exudate at surgical site with marked venous stasis.
4	R	Slightly decreased activity over surgical site. Collateral flows. Markedly decreased clearance from lower leg.	Small thrombi at suture sites and collateral veins.
	L	Decreased activity over suture sites. Collateral flows and marked retention in lower leg.	Multiple small thrombi at suture sites. Several collateral veins.
5	R	Decreased activity over suture sites. Slight retention at distal part of femoral vein. Collateral flows from popliteal vein to distal femoral vein and from distal femoral vein to hypogastric vein.	Small thrombi at suture sites. About 20 ml of fresh blood at surgical site, with marked venous stasis.
	L	Decreased activity over surgical site. Marked retention below surgical site. Collateral flows.	No thrombus found, but elongated clot in venous lumen. About 50-ml hematoma at surgical site.

* The right legs received macroaggregated albumin particles (MAA), and the left legs received microspheres (MS).

after surgery, the dogs were placed under a scintillation camera and 2 mCi of ^{99m}Tc -labeled albumin particles was injected into a superficial vein of each foot, with two tourniquets in place, one below the knee and the other above the ankle. Macroaggregated albumin (MAA) (Macrotec, Squibb & Sons, Princeton, N.J.) was used in the right leg and microspheres (MS) (Instant Microsphere, 3M Co., St. Paul, Minn.) in the left leg. These agents are in routine use for lung scintigraphy at our institution, and we find both satisfactory.

A Searle Radiographics HP scintillation camera with a low-energy diverging collimator was used to collect 10,000–20,000 counts for each image, these being displayed on Polaroid film. Serial images were obtained for 10 min, starting from the time of injection. Immediately after the scintigraphic studies of the living animals, the dogs were killed and the veins were excised from both legs. The isolated veins were placed on the surface of the collimator and scintigrams were obtained. Next, the veins were opened to check for thrombi and injured areas within the walls. Samples were examined under a light microscope. Some thrombi were immersed in a suspension of labeled particles and examined under a microscope without histologic slicing or staining.

Studies of patients. Just before a varicotomy was performed, 0.5 mCi of ^{99m}Tc -MAA was injected into the patient's distal saphenous vein. After the veins were excised by external stripping, they were placed on a collimator and scintigrams were immediately obtained.

In order to study the adherence of the labeled particles to a thrombus, clots obtained from the patients' blood samples were immersed for 10–15 sec in suspensions of ^{99m}Tc -MAA or ^{99m}Tc -MS in gently oscillating glass tubes. The clots were then removed from the suspension and examined under a microscope. The remaining samples of thrombosed veins removed from the experimental animals and the blood clots from patients were prepared routinely for hematoxylin–eosin staining and microscopic study. At magnifications of 100 or 200 diameters, the albumin particles (MAA and MS) could be easily differentiated from red blood cells, even in unstained preparations.

Radionuclide venography of patients. The following venographic procedure was developed to image the superficial as well as the deep veins of the legs. The patient was instructed to lie supine on an imaging table, and the lower halves of both legs were aligned in the field of view of the camera. Two tourni-

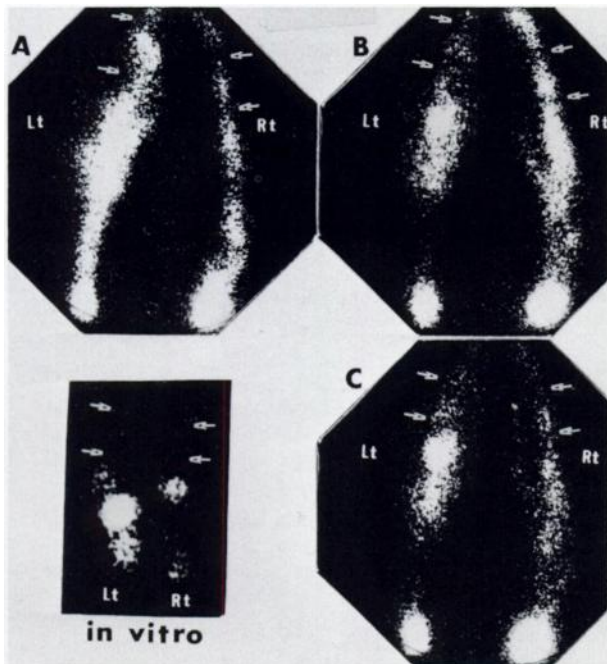


FIG. 1. Series of venograms (A-C) obtained from dog No. 3, 24 hr after surgery. Surgical sutures (arrows) were cold or cool throughout. Increased radioactivity below sutured sites is seen and abnormal collateral flows are noted. (In vitro) Venogram from both excised femoral veins.

quets were applied to each leg, one below the knee and the other above the ankle. Then, 2 mCi of ^{99m}Tc -MAA or ^{99m}Tc -MS was injected into the dorsal vein of each foot. After radioactivity from both deep calf veins appeared on a persistence scope, the tourniquet over the ankle was released. The patient's thighs were then positioned under the camera field, and images

of both femoral veins were obtained. Next, images of both iliac veins and of the distal part of the inferior vena cava were secured. Immediately after the pelvic view, the thighs were again positioned under the camera field, the below-knee tourniquets were released simultaneously with activation of the camera, and two or three serial scintigrams were obtained of the thighs and lower pelvic regions. These scintigrams show the femoral and the long saphenous veins if they are healthy. When one or more areas of radioactivity retention were detected, the patient was instructed to flex and stretch the knees. The lower legs were then again positioned under the camera, and a series of delayed images was obtained for 10-30 min.

RESULTS

Animal experiments. The studies on the five dogs are summarized in Table 1. All the postmortem examinations disclosed edematous change in the venous walls wherever sutures had been placed or crush injuries had been inflicted. Scintigrams of the 10 excised femoral veins from all five dogs showed the radioactivity distribution to be qualitatively different from that revealed by the corresponding venograms (Figs. 1 and 2). Large thrombi at the sites of sutures did not correlate with the areas of increased radioactivity on the venograms. Numerous microscopic examinations of the venous thrombi and injured venous walls removed from the dogs failed to show adhesion of either microspheres or macroaggregated albumin particles to the surface of these tissues (Fig. 3).

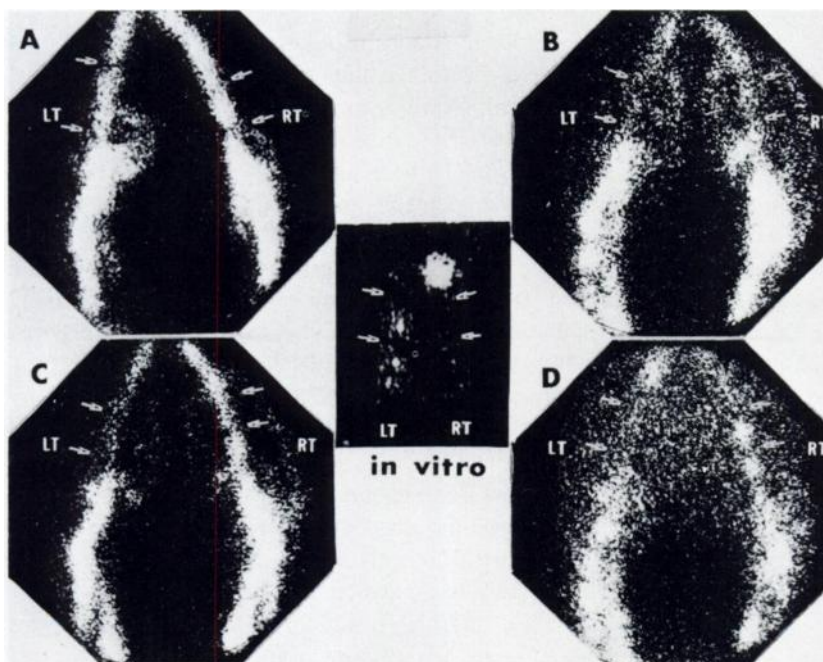


FIG. 2. Series of venograms (A-D) from dog No. 4. Arrows indicate areas of surgical suture applied on wall of femoral vein. Throughout study, sutured areas were cold or cool. Marked retention of radioactivity distal to sutured sites and many abnormal collateral paths are seen.

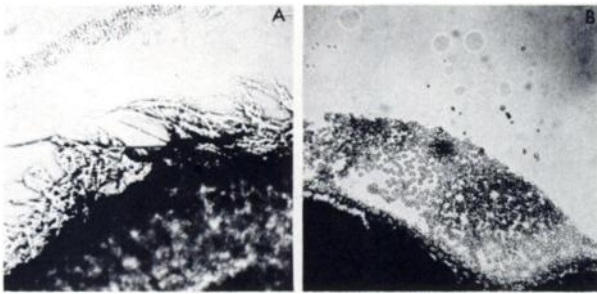


FIG. 3. Microphotographs from two excised venous thrombi from canine femoral vein fail to show adherence of labeled particles to surface. Thrombi were examined under microscope at 100 magnification without slicing or staining. (A) Thrombus removed from right femoral vein injected with MAA. (B) Thrombus removed from left femoral vein injected with MS.




FIG. 4. Excised human saphenous vein and its scintigram after injection of 0.5 mCi of ^{99m}Tc -MAA before varicotomy. Areas of varicosity (arrow) and venous valves failed to concentrate labeled albumin particles.



FIG. 5. Normal venogram. Distal end of inferior vena cava, iliac, common femoral, femoral, popliteal, and long saphenous veins are well visualized.

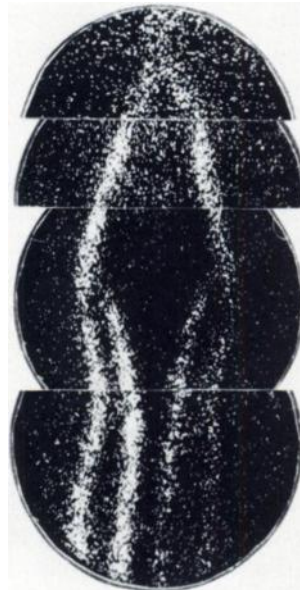


FIG. 6. Abnormal venogram. Right leg shows flow defect at proximal saphenous vein, with collateral flow. Flow from distal saphenous vein to popliteal vein is also noted, with flow defect at junction of tibial and popliteal veins.

Studies of patients. Superficial thigh veins isolated from two patients who underwent varicotomy after an injection of 0.5 mCi of ^{99m}Tc -MAA failed to show any recognizable collection of radioactivity in either normal or abnormal intravascular structures (Fig. 4).

Examination of the surface of blood clots immersed in suspensions of the labeled particles revealed that the particles do not adhere to those surfaces in the time period used.

Radionuclide venography was performed in 62 patients during 1974. All of these patients had recurrent pulmonary embolism or clinical signs and symptoms of deep or superficial leg-vein thrombophlebitis. Contrast venography was performed in six of these patients in whom the venographic findings were not in accord with the clinical findings. Two abnormal and four normal contrast venograms correlated with the venographic findings. No discrepancies were observed.

The long saphenous vein and the femoral vein could be clearly visualized on a normal venogram using the technique described here (Fig. 5). In several instances the venogram revealed some defect, such as abnormality in the long saphenous vein, an obstruction due to a venous thrombosis, a collateral flow, or an area of delayed washout (Fig. 6). The technique used to delineate the saphenous vein was helpful in orienting the venous structures anatomically. Abnormality of the femoral veins could be readily confirmed (Fig. 7).

In the series of images obtained over an interval of 10–30 min after dosing, most of the abnormal ac-

cumulations of radionuclide (hot spots) seen in the early images faded and disappeared within 30 min.

DISCUSSION

The development of a simple and effective procedure for the detection of venous thrombosis is one of the most urgent projects in medical research. The incidence of this condition is very high in surgical and obstetric patients, ranging over 28–65% (9,10), and it is clinically silent in 50–70% of the patients (5,11–13).

The detection of venous thrombosis with labeled fibrinogen might seem to be an ideal technique because fibrinogen is incorporated into thrombi (5,11,12,14). This procedure, however, has a number of disadvantages: it requires several days; the images are often poorly resolved, particularly in the pelvic region; transmission of disease is possible; and a relatively high radiation dose is imposed upon the patient.

If labeled particles do adhere to the thrombus or to the inflamed venous wall, as reported by many investigators (1,3,6), the venographic technique with ^{99m}Tc -labeled albumin would be an ideal procedure for detecting venous thrombosis. Data from our study, however, disagree with those reports: the labeled particles did not adhere readily to the surface of a thrombus. When blood is withdrawn into a syringe contained labeled particles, small highly radioactive clots immediately form; such clots are often responsible for the hot spots seen in lung scintigrams (15). Conceivably, this kind of "hot spot" or a larger aggregate of the labeled particles could easily be trapped at the area of thrombophlebitis because of the irregular and narrowed lumen and the sluggish flow. If a venographic hot spot were due to the adhesion of labeled particles to a thrombus, it should not disappear in 10–30 min. On the other hand, the narrow and irregular lumen of a thrombosed or varicose vein may temporarily trap particles, which may be slowly washed out by the continuous flow of blood. The delayed washout or the collection of activity seen on a venogram probably represents the trapping of labeled particles by a venous stasis due to partial occlusion of the lumen by thrombosis. When a vein is completely occluded, the labeled particles cannot reach the diseased area and it will remain cold on the venogram (8,16).

The labeled albumin particles vary widely depending on how they are prepared. For example, the consistency and particle size of macroaggregated albumin may be changed by altering the pH or the temperature of the medium (17). Tests in our laboratory show that albumin microspheres are readily aggregated during the labeling procedure when

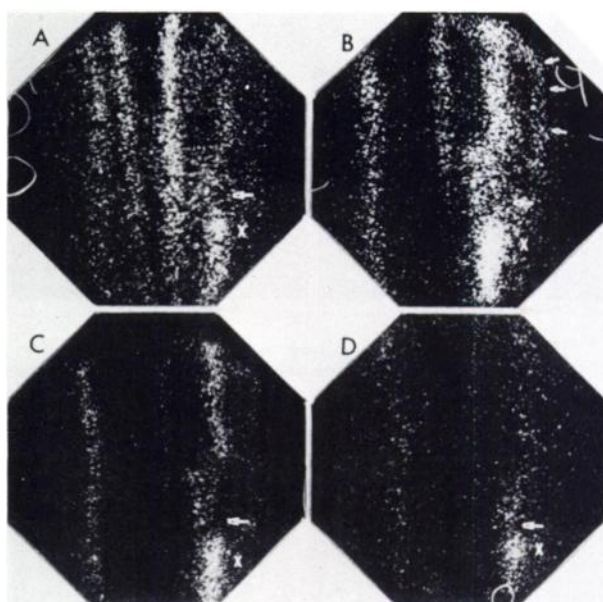


FIG. 7. Abnormal venogram. (A) Right leg shows no abnormality in femoral and saphenous veins, whereas left leg shows "cold" (arrow) and "hot" areas (cross) at popliteal region. (B) Collateral flow is seen from hot area to proximal femoral vein (arrows). (C,D) Cold and hot areas persist in later venograms, indicating that cold area is thrombosed and that stasis exists distal to thrombus.

heated for longer than 15 min. Although softer or larger albumin particles may adhere to thrombi, we have not noted any difference between labeled MS and MAA in producing positive venographic findings.

Webber et al (18) showed the affinity of a blood clot for MAA in vitro. They found that suspended albumin particles would aggregate if dropped onto the surface of a clot and left for 5 min, and they attributed this to the irregular surface of the particles, noting that the softer particles aggregated more readily. The same thing happened when the particles were mixed with the clot in the narrow tube of a hemocytometer. In addition, labeled particles aggregate readily when a suspension of them is left in a syringe or vial for more than a few minutes. These observations, however, probably do not explain the behavior of the labeled albumin particles in vivo. In this study we assumed that the flow time of injected particles through the diseased vein would not exceed 15 sec unless there were venous stasis. Such a brief exposure of a blood clot to a suspension of labeled particles is insufficient for binding to occur. Our study suggests that particles can be entrapped in the region of stasis and washed out gradually, although labeled particles may adhere to the thrombus if stasis prolongs the contact.

The results of the animal studies show that radioactive particles collect in areas of venous stasis. Partial occlusion of a vein by a thrombus always coincided with a collection of labeled particles distal to

the clot and distal to the origin of the collateral vein (Fig. 7B).

The incidence of thrombosis of the superficial veins of the legs appears to be higher than generally recognized. Saphenous vein thrombosis develops frequently in surgical and obstetric patients (19,20), and the extension of these thrombi into the common femoral vein increases the hazard of pulmonary embolism (21,22). Although contrast phlebography allows diagnostic examination of the deep venous system, diagnosis of thrombophlebitis of the superficial leg veins depends on the clinical signs and symptoms. Accordingly, the incidence of clinically silent thrombosis of the superficial veins is not known.

Simultaneous visualization of the great saphenous vein and the femoral vein is very useful in the following respects: In the conventional radionuclide venogram, which shows only one line of blood flow in the thigh region, the femoral vein and the long saphenous vein are not differentiated with certainty. The modified procedure we describe makes it possible to distinguish these two veins reliably. Simultaneous visualization of both veins occasionally shows an abnormal collateral flow from the femoral vein to the saphenous vein, although the initial venograms of the femoral vein alone may all look normal in these cases. Thrombosis of the saphenous vein can be detected on the venogram by abnormal collateral flow from the vein, interruption of the flow of radioactivity in the vein, or both.

CONCLUSIONS

The delayed washout of labeled particles just distal to the thrombus is most likely due to a combination of venous stasis and temporary concentration of the particles rather than to their adhesion to the thrombus.

No difference was noted between the quality of venograms obtained with ^{99m}Tc -MS and those obtained with ^{99m}Tc -MAA.

Scintigraphic evidence for venous thrombosis is: a region of decreased or absent radioactivity at the site of thrombosis, accompanied by a retention of radioactivity distal to the diseased area. Visualization of one or more collateral veins also indicates thrombosis.

Visualization of the saphenous vein by the modified venographic technique described in this report was very useful for better evaluation of the deep-vein venogram and for detection of abnormality in the superficial vein.

REFERENCES

1. WEBBER MM, BENNETT LR, CRAGIN M, et al: Thrombophlebitis. Demonstration by scintiscanning. *Radiology* 92: 620-623, 1969
2. ROSENTHALL L, GREYSON ND: Observations on the use of ^{99m}Tc -albumin macroaggregates for detection of thrombophlebitis. *Radiology* 94: 413-416, 1970
3. HENKIN RE, YAO JST, QUINN JE, et al: Radionuclide venography (RNV) in lower extremity venous disease. *J Nucl Med* 15: 171-175, 1974
4. DRIEDGER AA, REID BD, HEAGY FC: Lung and leg scanning with ^{99m}Tc -labeled albumin macroaggregates. *Can Med Assoc J* 111: 403-405, 1974
5. COON WW: Some newer developments in diagnosis and management of venous thromboembolism. *Univ Mich Med Cent J* 40: 3-7, 1974
6. DUFFY GJ, D'AURIA D, BRIEN TG, et al: New radioisotope test for detection of deep vein thrombosis in the legs. *Br Med J* 1: 712-714, 1973
7. RYO UY: Radionuclide venography. *J Nucl Med* 15: 915, 1974
8. ROSENTHALL L: Combined inferior vena cavography, iliac venography and lung imaging with ^{99m}Tc albumin macroaggregates. *Radiology* 98: 623-626, 1971
9. CHARKES ND, DUGAN MA, MAIER WP, et al: Scintigraphic detection of deep vein thrombosis with ^{125}I fibrinogen. *J Nucl Med* 15: 1163-1166, 1974
10. SEVITT S, GALLAGHER N: Venous thrombosis and pulmonary embolism. A clinico-pathological study in injured and burned patients. *Br J Surg* 48: 475-489, 1961
11. DUFFY GJ: A new bedside radioisotope test for detection of deep vein thrombosis. *Am Heart J* 88: 256-257, 1974
12. LAMBI JM, MAHAFFY RG, BARBER DC, et al: Diagnostic accuracy in venous thrombosis. *Br Med J* 2: 142-143, 1970
13. EVARTS CM, ALFIDI RJ: Thromboembolism after total hip reconstruction. Failure of low doses of heparin in prevention. *JAMA* 225: 515-516, 1973
14. KAKKAR VV: Deep vein thrombosis. *Circulation* 51: 8-19, 1975
15. PRESTON DF, GREENLAW RH: Hot spots in lung scans. *J Nucl Med* 11: 422-425, 1970
16. McDONALD GB, HAMILTON GW, BARNES RW, et al: Radionuclide venography. *J Nucl Med* 14: 528-530, 1973
17. COLOMBETTI LG, MOERLEIN S, PINSKY SM: Rapid and reliable preparation of macroaggregated albumin suitable for lung scintigraphy. *Int J Nucl Med Biol* 2: 180-184, 1975
18. WEBBER MM, VICTERY W, CRAGIN MD: Demonstration of thrombophlebitis and endothelial damage by scintiscanning. *Radiology* 100: 93-97, 1971
19. HAFNER CD, CRANLEY JJ, KRAUSE RJ, et al: A method of managing superficial thrombophlebitis. *Surgery* 55: 201-206, 1964
20. AARO LA, JUERGENS JL: Thrombophlebitis associated with pregnancy. *Am J Obstet Gynecol* 109: 1128-1136, 1971
21. GJÖRES JE: Surgical therapy of ascending thrombophlebitis in the saphenous system. *Angiology* 13: 241-243, 1962
22. ADAR R, SALZMAN EW: Treatment of thrombosis of veins of the left extremities. *N Engl J Med* 14: 528-530, 1973