

GALLIUM UPTAKE IN BENIGN

TUMOR OF LIVER: CASE REPORT

Martin A. Belanger, Jon M. Beauchamp, and Harold R. Neitzschman

Charity Hospital of Louisiana, New Orleans, Louisiana

A case of positive tracer localization in a benign tumor of the liver on a ^{67}Ga -citrate scan is reported. The authors were unable to find any previous reports of positive localization of gallium in this type of liver tumor.

Previous publications have reported a degree of accuracy approaching 100% for positive studies concerned with gallium (1). Other authors have reported never having seen a benign tumor localizing gallium (2). The mechanism of gallium localization, although related to tumor biology, is still unknown (3). The following case report describes a patient having a large area of diminished tracer localization on the $^{99\text{m}}\text{Tc}$ -sulfur colloid scan and showing a large area of increased tracer localization on the gallium scan. This difference in uptake of nuclide localization was determined by visual comparison between the tumor and normal adjacent liver tissue.

CASE REPORT

The patient, a 23-year-old woman, was admitted on February 18, 1973 with a history of fullness in the epigastrium for as long as she could remember.

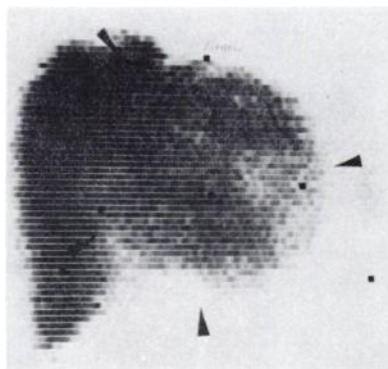


FIG. 1. Technetium-99m-sulfur colloid scan recording large area of diminished tracer localization in left lobe of liver. Lesion is delineated by arrows.

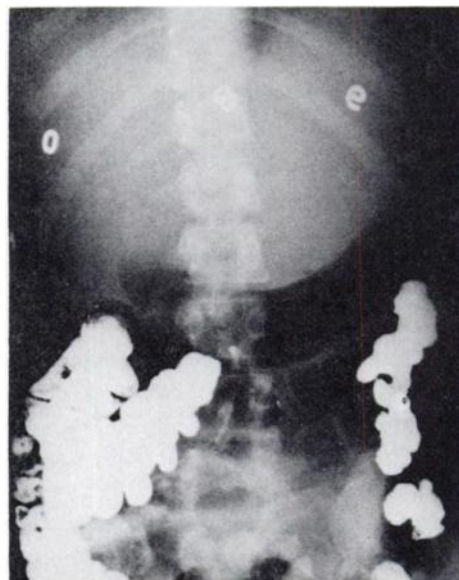

FIG. 2. Abdominal radiograph recording enlarged lobe of liver producing extrinsic pressure on lesser curvature of stomach.

Approximately 2–3 months prior to admission she noticed a slight weight gain which she described as being centered over the epigastrium. One week prior to admission she developed pressing pain in the epigastric area that radiated to her back and left shoulder. She had a palpable mass in the epigastrium that was described as being firm and mildly tender. An upper GI series recorded a large mass in the left lobe of the liver producing compression on the lesser curvature of the stomach; $^{99\text{m}}\text{Tc}$ -sulfur colloid liver scan recorded a large space-occupying lesion in the left lobe of the liver (Figs. 1 and 2). A gallium liver scan was then performed and the large mass lesion of the left liver lobe demonstrated increased uptake of gallium as compared with adjacent

Received Sept. 17, 1974; revision accepted Jan. 9, 1975.

For reprints contact: Martin A. Belanger, Nuclear Medicine, Charity Hospital of Louisiana, 1532 Tulane Ave., New Orleans, La. 70140.

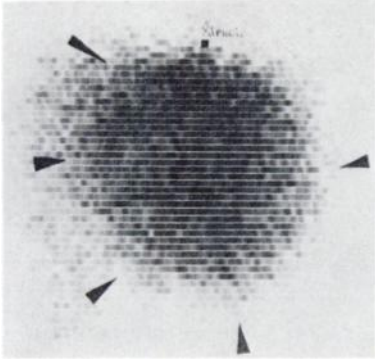


FIG. 3. Positive localization of ^{67}Ga -citrate in mass lesion of liver. Lesion is delineated by arrows.

normal liver (Fig. 3). In view of the scan findings, the provisional diagnosis prior to surgery was tumor of the liver, probably hepatoma. A left hepatic lobectomy was performed on February 26, 1973 and the patient has done well postoperatively. A pathol-

ogy report recorded hepatocellular adenoma—very well differentiated, virtually absent inflammatory cell infiltrate measuring $15 \times 12.5 \times 8.5$ cm with a weight of 580 gm.

DISCUSSION

A significant number of false-negative results with gallium liver scanning have been reported. This is an unusual case of positive localization in a benign tumor of the liver. The patient is now 18 months postoperative and in good health.

REFERENCES

1. GROVE RB, MADEWELL JE, RAPP GS, et al: Practical application of ^{67}Ga -citrate to the evaluation of liver pathology. *J Nucl Med* 14: 402, 1973
2. LARSON SM, MILDER MS, JOHNSTON GS: Interpretation of the ^{67}Ga photoscan. *J Nucl Med* 14: 208–214, 1973
3. DELAND FH, SAUERBRUNN BJL, BOYD C: ^{67}Ga -citrate imaging in untreated primary lung cancer: preliminary report of cooperative group. *J Nucl Med* 15: 408–411, 1974