

# PULMONARY ARTERIOVENOUS MALFORMATION: SCINTIGRAPHIC DEMONSTRATION AND ANALYSIS

Michael A. Weiss, Mordecai Koenigsberg, and Leonard M. Freeman

*Albert Einstein College of Medicine and The Bronx Municipal Hospital Center, Bronx, New York*

***Scintiphotographic demonstration of a pulmonary arteriovenous malformation in an 8-year-old child is presented. Using a data processor, the transit of radiopertechnetate through the lesion as well as various portions of the lung is shown. The "steal" of blood flow from the left lower lobe is documented.***

Since the first premortem diagnosis of pulmonary arteriovenous fistula was made in 1939 (1), interest in this entity has greatly increased as treatment of this condition (first resection in 1942) (2) has been shown to reduce or eliminate some of its significant complications. The introduction of radionuclide angiography adds an atraumatic technique that can be invaluable in establishing the diagnosis of pulmonary arteriovenous fistula (3). The availability of a data processor adds useful quantitative information concerning alterations in pulmonary blood flow associated with these lesions. The purpose of this report is to illustrate these points.

## CASE REPORT

NV, an 8-year-old Puerto Rican girl, came to the Bronx Municipal Hospital Center with a fever and a persistent cough. Cyanosis accentuated by physical activity was present since 6 months of age. Exertional dyspnea and easy fatigability also were noted. Physical examination revealed cyanosis of the lips, conjunctiva, and nail beds associated with slight clubbing. No telangiectasis was noted. A thorough cardiopulmonary exam was within normal limits. Pertinent laboratory results included a hematocrit of 54%, hemoglobin of 17.8 gm, and a normal white blood cell count. The ECG was normal.

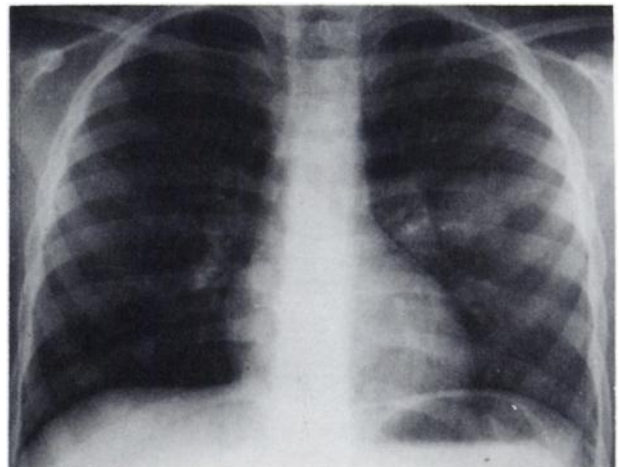
Roentgenographic examination of the chest (Fig. 1) revealed a posteromedial density in the left lung that remained unchanged on several followup examinations. The possibility of pulmonary arteriovenous malformation was strongly suspected. To confirm

this suspicion, radionuclide angiography was performed according to the method described by Oldendorf (4) with a 0.5-ml intravenous bolus containing 6 mCi of  $^{99m}\text{Tc}$ -pertechnetate. Serial scintiphotos were obtained at 2–3-sec intervals (Searle Pho/Gamma HP scintillation camera) while data were recorded on digital magnetic tape (Intertechnique Data Processing System) at the rate of two frames per second for subsequent retrieval and analysis.

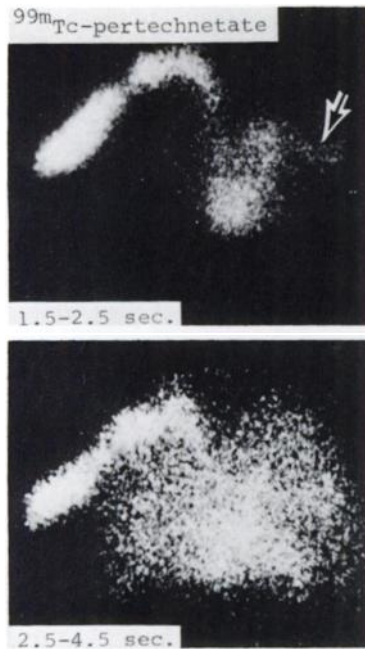The conventional scintiphotos (Fig. 2) revealed a band of increased vascular activity extending directly from the pulmonary artery to the abnormal area noted on x-ray. Using the data processor, areas over the arteriovenous malformation and lungs were selected with an index coordinate system (Fig. 3, top). Time-activity curves obtained from these regions confirmed the presence of intense activity in

Received Aug. 5, 1974; revision accepted Oct. 3, 1974.

For reprints contact: Leonard M. Freeman, Dept. of Radiology, Albert Einstein College of Medicine, 1300 Morris Park Ave., Bronx, N.Y. 10461.



**FIG. 1.** PA view of chest. Density (3 cm) is demonstrated in left lung adjacent to but separate from hilum.



**FIG. 2.** Scintiphoto composite after intravenous injection of  $^{99m}\text{Tc}$ -pertechnetate. Early filling of vascular structure directly from left pulmonary artery is demonstrated at 1.5-2.5 sec (arrow).

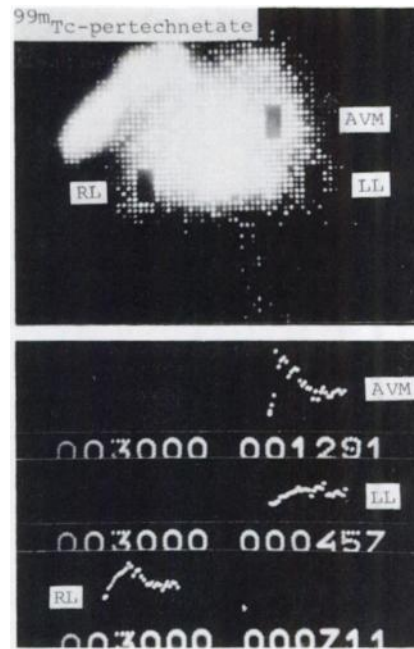
the lesion immediately after right heart filling but prior to significant pulmonary perfusion (Fig. 3, bottom). The rapid "washin" and "washout" phases shown in the curves obtained from the lesion are typical of arteriovenous malformation. Because of the subsequent overlying pulmonary activity, this latter piece of information could not be obtained from simple visual interpretation of the radionuclide angiogram.

To elucidate any redistribution in pulmonary blood flow caused by the arteriovenous malformation, a similar analysis of perfusion to both upper and lower lobes was performed, carefully avoiding the activity in the lesion (Fig. 4, top). Both the time-activity curves and numerical printout demonstrated marked diminution of perfusion to the left lower lobe as compared with the right lower lobe (Fig. 4, bottom). There is also asymmetric perfusion of both upper lobes indicating that a significant portion of the flow through the left pulmonary artery is diverted to the arteriovenous malformation.

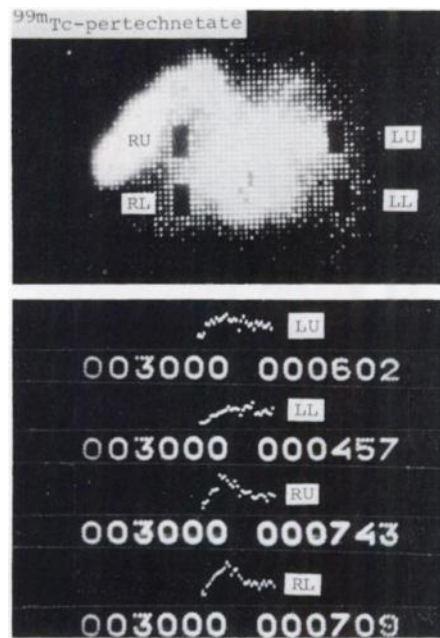Pulmonary angiography confirmed the presence of a large arteriovenous malformation in the apical segment of the left lower lobe (Fig. 5). A number of smaller, more peripherally situated lesions was demonstrated as well. Because of the patient's symptomatology and polycythemia, the major lesion was resected.

#### DISCUSSION

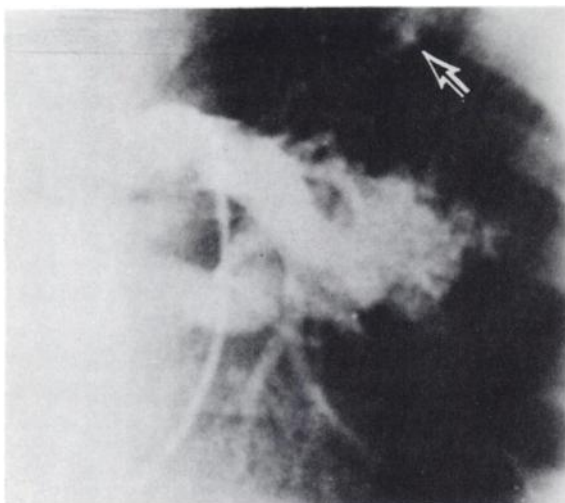
Pulmonary arteriovenous malformation is an uncommon disorder that can in some instances result in



**FIG. 3.** Using data processor and index coordinate system, symmetric areas of interest are chosen over both lower lobes and lesion (top). Time-activity curves generated from these areas of interest (bottom) demonstrate much earlier appearance (very steep slope) and disappearance of activity in lesion as compared with left or right lower lobes. Thirty frames were obtained since study was performed at two frames per second for 15 sec. Numbers on right represent total number of counts from each indicated area during this period.



**FIG. 4.** Symmetric areas of interest are chosen over right upper, right lower, left upper, and left lower lobes (top). Time-activity curves obtained from these "flagged" areas (bottom) suggest differences in rate of flow to two lungs, with right lung receiving more blood more rapidly. Digital analysis clearly demonstrates diminution in flow to left lower lobe as compared with right lower or left upper lobes. Left upper lobe shows milder diminution in flow.



**FIG. 5.** One frame from selective pulmonary angiogram demonstrating large arteriovenous malformation with prominent early draining vein. Also seen is small peripheral arteriovenous malformation near upper margin of field (arrow). Another small peripheral arteriovenous malformation was found in right lung.

complications as severe as bacterial endocarditis, rupture with massive hemoptysis, and central nervous system involvement with a cerebral embolism or abscess (5). The more common effects of pulmonary arteriovenous malformations are due to the presence of unsaturated blood or the resultant secondary polycythemia, as in the present case. Oxygen saturation usually varies from 50 to 80% (6). Unlike peripheral arteriovenous malformations, there usually is no significant alteration in cardiac output.

The lesions are frequently multiple; however, the clinical manifestations depend on the size and not the number of the malformations (7). One third are associated with telangiectasis elsewhere (6) as part of the Osler-Weber-Rendu syndrome. The onset of symptoms usually begins in the third decade. As in this case, however, approximately 30% are symptomatic from childhood. Symptoms include cyanosis, clubbing, dyspnea, weakness, and easy fatigability.

The frequent multiplicity of these lesions and occasional vascular supply from more than one bronchopulmonary segment (8) make extensive preoperative evaluation in symptomatic patients important. It must be remembered, however, that a small, hemodynamically unimportant pulmonary arteriovenous malformation may become symptomatic after the surgical removal of the larger lesion.

The scintiphotos obtained in this case clearly show a vascular structure filling directly from the pulmonary artery segment. Time-activity curves further demonstrate that the malformation was supplied by a left lower lobe pulmonary artery branch with resultant "steal" of most of the perfusion away from the remainder of the left lower lobe and to a lesser extent from the left upper lobe, a finding later confirmed by pulmonary arteriography. The simple, atraumatic radionuclide investigation served a dual purpose in this case: (A) it determined the vascular nature of the lesion and with reasonable accuracy its anatomic location and (B) it provided physiologic information concerning the perfusion of the lesion itself and the relative distribution of blood flow to different pulmonary regions.

The ability to obtain such useful morphologic and physiologic information with this noninvasive technique should prompt one to strongly consider its use in similar situations in the future.

#### ACKNOWLEDGMENT

This work was supported in part by USPHS Grant 5T01 GM 01582 from the National Institute of Medical Sciences.

#### REFERENCES

1. SMITH HL, HORTON BT: Arteriovenous fistula of the lung associated with polycythemia vera: Report of a case in which the diagnosis was made clinically. *Am Heart J* 18: 589-592, 1939
2. LINDGREN E: Roentgen diagnosis of arteriovenous aneurysm of the lung. *Acta Radiol* 27: 585-600, 1946
3. STEVENSON JS, MAYNARD CD, WHITLEY JE: Arteriovenous malformation of the lung—the use of radioisotope angiography. *Radiology* 99: 157-158, 1971
4. OLDENDORF WH, KITANO M, SHIMIZU S: Evaluation of a simple technique for abrupt intravenous injection of radioisotope. *J Nucl Med* 6: 205-209, 1965
5. HODGSON CH, KAYE RL: Pulmonary arteriovenous fistula and hereditary hemorrhagic telangiectasia—a review and report of 35 cases of fistula. *Dis Chest* 43: 449-455, 1963
6. MOYER JH, GLANTZ G, BREST AN: Pulmonary arteriovenous fistulas—physiologic and clinical considerations. *Am J Med* 32: 417-435, 1962
7. SAPRU RP, HUTCHISON DCS, HALL JI: Pulmonary hypertension in patients with pulmonary arteriovenous fistulae. *Br Heart J* 31: 559-569, 1969
8. BIRNBAUM GL: *Anatomy of the Bronchovascular System—Its Application to Surgery*. Chicago, Year Book, 1954