

LEAD-203 FOR SKELETAL IMAGING

Lead-203 has recently been proposed as a potential radionuclide for skeletal imaging (1). A whole-body image taken 3 days after intravenous injection of carrier-free ²⁰³Pb-acetate in a rabbit suggested localization in skeleton as well as residual activity in liver and kidneys. We have been able to confirm this finding using carrier-free ²⁰³Pb-chloride, and we have observed a relatively low liver uptake of radioactivity in the adult rat compared with the adult rabbit, suggesting a different body distribution of the radiopharmaceutical between the two species.

In addition, bone-to-soft-tissue ratios have been compared after intravenous injection of ^{99m}Tc-polyphosphate (obtained from New England Nuclear) and ²⁰³Pb-chloride (produced by Philips-Duphar) in adult rats. Tissue concentrations were expressed as radioactivity per gram tissue. One whole femur and thigh musculature were taken to determine skeletal and muscle activity, respectively. The results that were obtained are shown in Table 1.

Excellent bone visualization was seen at 72 hr after injection of ²⁰³PbCl₂ as shown in Fig. 1. The higher bone-to-muscle ratio after 72 hr was due to decreased muscle concentration of radioactivity. This observation combined with the higher bone-to-muscle ratios of ²⁰³Pb compared with ^{99m}Tc and the rela-

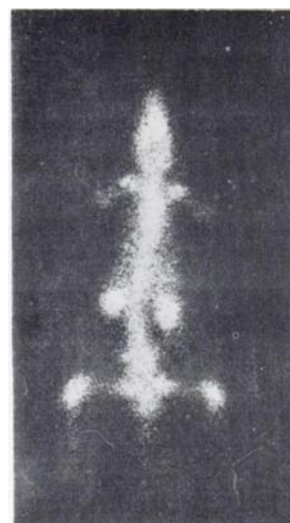


FIG. 1. Anterior image of rat, obtained using pinhole collimator, 72 hr after intravenous injection of ²⁰³PbCl₂.

tively long half-life of ²⁰³Pb (52 hr) suggests that ²⁰³PbCl₂ may have advantages over ^{99m}Tc-polyphosphate as a bone-seeker. Its usefulness may be limited to some extent by liver uptake of radioactivity although it has been suggested that the use of chelates of intermediate stability (e.g., ²⁰³Pb-HEDTA) may prevent colloid formation and reticuloendothelial localization (1,2).

JELTE HOVING
ALBERT VERSLUIS
MARTIEN G. WOLDRING
University Hospital
Groningen, The Netherlands

REFERENCES

1. RAO DV, GOODWIN PN: ²⁰³Pb: a potential radionuclide for skeletal imaging. *J Nucl Med* 14: 872, 1973
2. SUBRAMANIAN G, MCAFEE JG, BLAIR RJ, et al: ¹⁰⁷Dy-HEDTA for skeletal imaging. *J Nucl Med* 12: 558-561, 1971

TABLE 1. COMPARISON OF BONE-TO-SOFT-TISSUE RATIOS AFTER INTRAVENOUS INJECTION OF ^{99m}Tc-POLYPHOSPHATE AND ²⁰³Pb-CHLORIDE IN ADULT RATS

Ratios	Hr after injection		
	^{99m} Tc	²⁰³ Pb	²⁰³ Pb
Bone/muscle	31.4	69.7	188.6
Bone/liver	16.3	0.8	3.7
Bone/kidneys	0.9	0.2	0.4