

# SCINTIGRAPHIC APPEARANCE OF BIFRONTAL EPIDURAL HEMATOMA: CASE REPORT

John Rockett, Fred Hamilton, James Robertson, and M. Moinuddin  
*Baptist Memorial Hospital, Memphis, Tennessee*

*A bifrontal and parasagittal epidural hematoma was detected on the brain scan. The scintigraphic appearance of this rare lesion is described.*

Because of the acute nature of the injury and the rapid clinical deterioration usually seen with epidural hematomas, we rarely have the opportunity to observe the scintiphotographic appearance of these lesions.

Recently we encountered a patient with a sub-acute bifrontal epidural hematoma. The brain image findings in this case are reported below.

## CASE REPORT

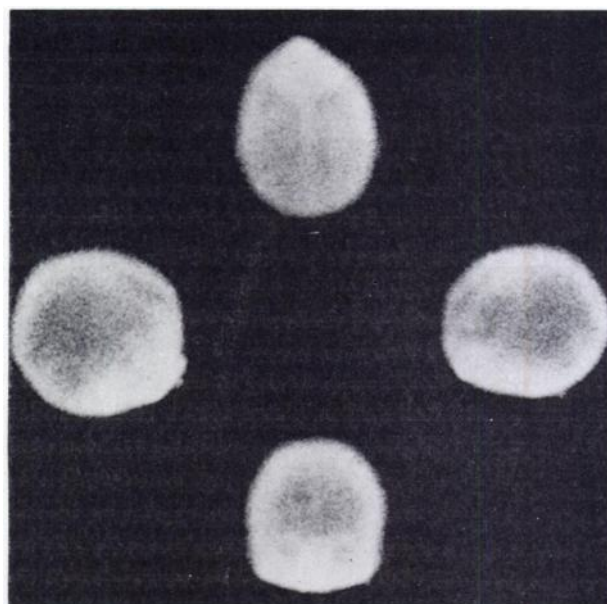
While operating a cotton gin press, a 17-year-old boy sustained a compression head injury without loss of consciousness.

Shortly after the incident, physical examination demonstrated no neurologic deficit. Later the same evening the patient began to have epistaxis and presented himself for treatment at a local hospital. Radiographs of the skull showed a 7-cm curvilinear, nondepressed skull fracture running transversely through the coronal sutures extending into both parietal areas.

Upon admission to the medical center, physical examination revealed a somewhat lethargic but oriented boy who complained only of a generalized headache. His blood pressure was 140/90 and pulse was 52 and irregular. Neurologic examination was normal.

The patient became progressively more alert. Seven days after admission the patient was ambulatory when he became nauseated and vomited. Although he complained of a stiff neck, his neurologic examination remained normal.

On the same day brain images (Fig. 1) revealed increased activity in the coronal suture area that corresponded to the site of the patient's fracture. A



**FIG. 1.** Vertex, lateral, and anterior brain scans demonstrating frontal "rim" signs on lateral views, thickened peripheral activity on anterior projection, and increased activity in frontal regions on vertex scan.

streak of increased activity resembling the so-called rim sign was seen in each frontal area on the lateral views. The abnormal accumulation of the radiopharmaceutical extended to the floor of the anterior fossa. On the anterior view, peripheral activity was thickened bilaterally. There appeared to be increased activity on the vertex view in both frontal regions, particularly in the left one. The frontal region was difficult to interpret on the vertex projection because of nasal activity. It was thought that the abnormalities in the frontal areas on the brain image were due to a bifrontal subdural hematoma.

Received Jan. 9, 1975; revision received April 30, 1975.

For reprints contact: John F. Rockett, Dept. of Nuclear Medicine, Baptist Memorial Hospital, 899 Madison Ave., Memphis, Tenn. 38146.

Retrograde right brachial and direct left carotid arteriograms demonstrated a large epidural hematoma overlying the convexity of both frontal areas. No significant midline vascular displacement was apparent due to the symmetrical nature of the lesion. There was some depression of the superior sagittal sinus typical of epidural hemorrhage.

A bifrontal craniotomy was performed the same day through a transcoronal incision with evacuation of a huge bifrontal and parasagittal hematoma estimated to be at least 250 cc. The massive epidural hemorrhage was depressing the frontal lobes and even extended subfrontally.

#### DISCUSSION

Epidural hematoma following head trauma is a relatively infrequent occurrence and bilateral extradural hemorrhage is distinctly rare (1). In his review of the literature, Soni recently reported a fifth individual case (2). Our own review of the literature fails to reveal a reported case of a bifrontal epidural hematoma detected by radionuclide imaging (3-11).

A bifrontal epidural hematoma nearly always results from a parietal skull fracture that crosses the midline. The skull fracture may be associated with a diastasis of the coronal suture. Bifrontal epidural hematomas are far less common than the temporo-parietal extradural hemorrhage.

The brain scan appearance of most reported epidural hematomas is the peripheral crescentic configuration identical to that usually seen in subdural hematomas (12,13). The "rim sign" has been described in a case of epidural hemorrhage (11). The rims of increased radioactivity are somewhat unusual in our case. They are more linear than usual and lie in a distribution similar to that of the anterior cerebral arteries on the lateral scintiphotos. Differentiation from anterior cerebral infarcts can be made on the anterior view. The infarct pattern is in or near

the midline while the extradural hematomas produce peripheral increase in activity on the frontal scan (14).

#### REFERENCES

1. MERRITT HH: *Textbook of Neurology*. Philadelphia, Lea & Febiger, 1959, p 369
2. SONI SR: Bilateral asymmetrical extradural hematomas. *J Neurosurg* 38: 647-649, 1973
3. FEINDEL W, ROVIT RL, STEPHENS-NEWSHAM L: Localization of intracranial vascular lesions by radioactive isotopes and an automatic contour brain scanner. *J Neurosurg* 18: 811-821, 1961
4. KRAMER S, ROVIT RL: The value of  $^{203}\text{Hg}$  brain scans in patients with intracranial hematomas. *Radiology* 83: 902-909, 1964
5. GILSON AJ, GARGANO FP: Correlation of brain scans and angiography in intracranial trauma. *Am J Roentgenol Radium Ther Nucl Med* 94: 819-827, 1965
6. CIRIC IS, QUINN JL, BUCY PC: Mercury 197 and technetium 99m brain scans in the diagnosis of non-neoplastic intracranial lesions. *J Neurosurg* 27: 119-125, 1967
7. MORLEY JB, LANGFORD KH: Abnormal brain scan with subacute extradural haematomas. *J Neurol Neurosurg Psychiatry* 33: 679-686, 1970
8. VON ORTNER WD, KOLLAR WAF: Infratentorielle epidurale Hämatome. *Munch Med Wochenschr* 114: 448-450, 1972
9. JAIN KK, SCHOBEL B: Diagnosis of extradural hematoma by brain scan. *Can Med Assoc J* 107: 218-219, 1972
10. SILBERSTEIN EB: Epidural hematoma with decreased radionuclide uptake. *J Nucl Med* 15: 712-713, 1974
11. TER BRUGGE KG, MEINDOK H: Rim sign in brain scintigraphy of epidural hematoma. *J Nucl Med* 14: 709-710, 1973
12. SY WM, WEINBURGER G, NGO N, et al: Imaging patterns of subdural hematoma—a proposed classification. *J Nucl Med* 15: 693-698, 1974
13. HEISER WJ, QUINN JL, MOLLIHAN WV: The crescent pattern of increased radioactivity in brain scanning. *Radiology* 87: 483-488, 1966
14. ROCKETT JF, KAPLAN ES, RAY M, et al: Scintiphotographic demonstration of bilateral infarction in the distribution of the anterior cerebral arteries. *Radiology* 112: 135-137, 1974