

**NASOGASTRIC SUCTION TO IMPROVE GASTROINTESTINAL SCANNING**

James P. Polga

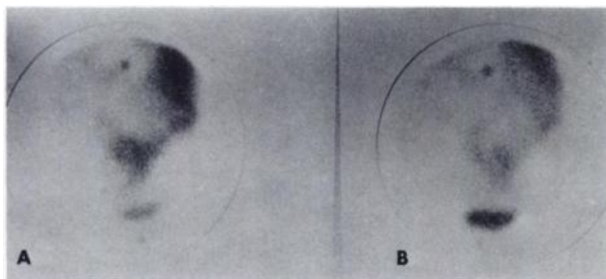
*Bethesda Lutheran Hospital, St. Paul, Minnesota*

***The validity of gastrointestinal imaging with  $^{99m}\text{Tc}$ -pertechnetate has been improved by preparatory nasogastric suction.***

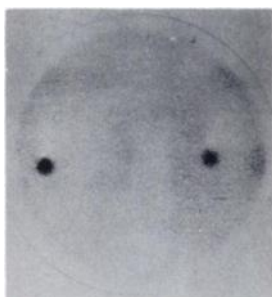Since the demonstration of positive scans in patients with Meckel's diverticulum as well as other conditions such as intussusception and small-bowel

obstruction,  $^{99m}\text{Tc}$ -pertechnetate gastrointestinal imaging has become an important part of the diagnostic workup at many centers, including our own, in patients with gastrointestinal bleeding in whom conventional examinations including barium and endoscopic examinations do not disclose a likely source of bleeding.

In our experience the most frequent cause of equivocally positive scans is activity in overlying small-intestinal loops. We therefore now routinely place a nasogastric tube in the stomach and put our patients on continuous low suction prior to the intravenous injection of the  $^{99m}\text{Tc}$ -pertechnetate. Most of the bowel activity which presumably arises from the gastric secretion of the pertechnetate is thereby removed. This has eliminated the problem of pooling in the bowel segments, thereby diminishing the changes of false-positive examinations (Figs. 1-2). Moreover, by eliminating this bowel activity the number of false-negatives will also be diminished because of relative image enhancement. Contraindications are only relative; it is rare that a nasogastric tube cannot be placed and maintained in position during examination. We have found this simple maneuver to be very useful in improving our diagnostic accuracy.



**FIG. 1.** Conventional imaging in patient demonstrating suspicious area of increased activity midway between umbilicus and pubic symphysis at 30 min (A) and 2-hr (B).



**FIG. 2.** Repeat imaging following placement of patient on nasogastric suction shows normal scan.

Received Nov. 3, 1973; original accepted Nov. 30, 1973.

For reprints contact: James P. Polga, Div. of Nuclear Medicine, Bethesda Lutheran Medical Center, St. Paul, Minn. 55101.