

# EFFECT OF GRANULOCYTOPENIA, MARROW SUPPRESSIVE DRUGS, AND INFECTION ON MARROW RETICULOENDOTHELIAL PATTERNS

Robert E. Henry, James W. Fletcher, Erica Solaric-George, and Robert M. Donati

*St. Louis Veterans Administration Hospital  
and St. Louis University School of Medicine, St. Louis, Missouri*

***RE marrow extension beyond the proximal one-third of the femur and humerus was observed in 19 of 38 studies performed on 26 patients with Hodgkin's disease or lymphoma. All of the patients demonstrating RE marrow extension had been treated with radiation, chemotherapy, or a combination of both. None of the untreated patients demonstrated RE marrow extension. A significant association with granulocytopenia was noted in patients with Hodgkin's disease or lymphoma demonstrating RE marrow extension. A similar association was seen in five additional patients with either renal transplant or metastatic carcinoma rendered granulocytopenic by immunosuppression or chemotherapy. Examination of an additional 13 patients with granulocytopenia not associated with chemotherapy did not reveal RE marrow extension. However, RE marrow extension in association with granulocytosis was observed in four of an additional seven patients with acute bacterial infection and no primary hematologic disease. Serial studies in patients with Hodgkin's disease or lymphoma revealed an association between the extending RE marrow pattern and intolerance to chemotherapy in three patients whereas three other patients without marrow extension tolerated chemotherapy well.***

***These data suggest that RE marrow extension following chemotherapy and radiation is due to compromised hematopoiesis reflected by granulocytopenia. The appearance of an extended RE marrow pattern following chemotherapy appears to be predictive of poor tolerance to further chemotherapy whereas nonextension of the RE marrow reflects adequate marrow granulopoietic reserve. Subclinical infection***

***cannot be completely excluded as a cause of RE marrow extension in patients with chemotherapy-associated granulocytopenia.***

Radiocolloids such as  $^{198}\text{Au}$ -colloid,  $^{113}\text{In}$ -ferrous hydroxide, and  $^{99\text{m}}\text{Tc}$ -sulfur colloid have been used clinically to delineate the spatial distribution of bone marrow on the assumption that the distribution of hematopoietic and reticuloendothelial (RE) tissue within the marrow is the same. In normal animals and man and in a variety of pathologic states, this association appears to be constant but as early as 1967 Van Dyke and his associates reported marked dissociation of marrow RE and erythropoietic activity in three patients: one with congenital red cell aplasia, a second with hypoplastic anemia, and a third with Hodgkin's disease who had been treated with radiation and chemotherapy (1). Despite this report, due to the absence of a readily available radiopharmaceutical to label adequately the granulocytic or erythropoietic tissue for marrow imaging, radiocolloids continue to be used as marrow imaging agents (2).

The purpose of this study was to determine whether the marrow pattern obtained with radiocolloid would provide information about hematopoietic function in patients with Hodgkin's disease or lymphoma who had undergone extensive radiotherapy or treatment with combinations of marrow toxic drugs.

## METHODS AND MATERIALS

Each patient was given 3 mCi of  $^{99\text{m}}\text{Tc}$ -sulfur colloid (Tesuloid®) intravenously. Fifteen minutes later

Received Sept. 4, 1973; revision accepted Dec. 3, 1973.

For reprints contact: Robert E. Henry (172-JC), St. Louis VA Hospital, St. Louis, Mo. 63125.

the liver and spleen were imaged using a gamma camera (Pho/Gamma III or Radicamera 5501). Anterior views of the shoulders, humerus, pelvis, hips, femurs, and knees, and a posterior view of the pelvis and lumbar vertebrae were obtained. If marrow was visualized in the midportions of the humerus or femur, additional distal views were obtained. A low-energy parallel-hole collimator was used and each image was accumulated for 200 sec to allow comparison of activity at different sites. The patients' charts were reviewed and diagnoses, therapy, blood counts, and other data were tabulated.

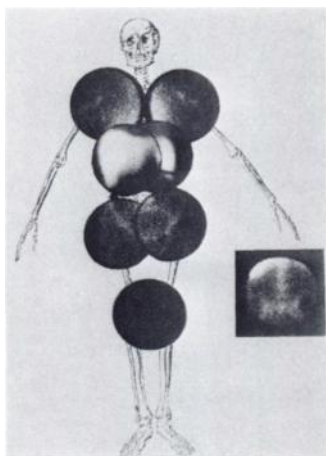
For purposes of this study, the marrow scans were evaluated without knowledge of the clinical data according to the following criteria:

Marrow patterns were considered to be *not extended* if the activity was limited to the axial skeleton with or without activity in the proximal one-fourth of the humerus and femur. The usual marrow RE distribution considered *not extended* is shown in Fig. 1.

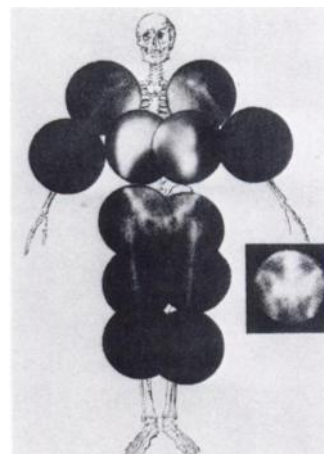
Marrow patterns were considered to be *extended* if there was visualization of marrow RE activity in the axial skeleton and beyond the proximal one-third of the humerus or femur as shown in Fig. 2.

Although focal defects associated with radiation therapy, metastatic disease, or Paget's disease were observed in the marrow pattern, these abnormalities are not considered in the present report.

Thirty-eight marrow scans were evaluated in 26 male patients with lymphoma or Hodgkin's disease. The patients were studied at the time of diagnosis



**FIG. 1.** Marrow pattern: not extended. This RE marrow pattern was obtained in 32-year-old male with untreated Stage IV Hodgkin's disease. Although hepatosplenomegaly is present, RE marrow is limited to axial skeleton and proximal one-quarter of humerus and femur. Inset is posterior view of lumbar vertebrae and sacrum.



**FIG. 2.** Marrow pattern: extended. This RE marrow pattern was obtained in 45-year-old male with lymphocytic lymphoma, poorly differentiated type, treated with combination chemotherapy for 18 months. Patient's course was complicated by granulocytopenia, thrombocytopenia, and frequent fever of unknown origin. In addition to visualization of axial skeleton, RE marrow is visualized beyond proximal one-third of humerus and femur. Inset is posterior view of lumbar vertebrae and sacrum.

or relapse, during chemotherapy or following completion of a course of chemotherapy. No patient was studied within 6 months of completing radiotherapy. Most of the patients had a complete blood count on the day of imaging. All patients had complete blood counts within 1 week of the time of imaging. Some patients were studied more than once and the additional studies were included if there had been a significant change in treatment, blood counts, or marrow RE pattern.

Marrow scintiphotos and clinical data were also evaluated in an additional 24 male patients. This group included 7 patients with acute pulmonary infection, 2 renal transplant patients on immunosuppressive therapy, 2 patients with adenocarcinoma receiving chemotherapy, and 13 patients with idiopathic granulocytopenia. The latter group included patients with unexplained granulocytopenia, familial neutropenia, or connective tissue disorders. All patients were studied only once and had complete blood counts within 7 days of imaging.

A prior (3) analysis of peripheral leukocyte counts of the racially mixed population at the St. Louis VA Hospital and the St. Louis University Hospitals established normal granulocyte counts for white males at  $4,463 \pm 1,374/\text{mm}^3$  and for black males at  $3,722 \pm 1,406/\text{mm}^3$ . In the present studies absolute granulocyte counts 1 s.d. below the mean were considered granulocytopenic. Therefore, values below 3,089 granulocytes/ $\text{mm}^3$  or below 2,316 granulocytes/ $\text{mm}^3$  were considered granulocytopenic for white males and black males, respectively.

All data were evaluated using the chi-square test

of significance. A p value of <0.05 was considered statistically significant.

RESULTS

Table 1 lists the initial RE marrow patterns associated with the mode of therapy in 26 patients with Stage III or IV Hodgkin's disease or lymphoma. All eight of the newly diagnosed, untreated patients had no extension of the marrow. Two of five patients who had been treated with radiation alone had marrow extension. Three of five patients who had completed or were undergoing chemotherapy had extended marrow patterns; seven of eight patients who had been treated with both radiation and chemotherapy had marrow RE extension.

Some of the patients with Hodgkin's disease or lymphoma were evaluated on more than one occasion. There were 12 instances of a significant change in therapy, blood counts, or marrow RE pattern during the clinical course of seven of these patients. Detailed temporal data on these 7 patients are presented later. However, all of the 38 examinations on patients with Hodgkin's disease or lymphoma are grouped in Table 2. These examinations were divided into two groups on the basis of extension or nonextension of the marrow patterns. The association between the marrow RE patterns and peripheral blood count abnormalities in these patients at the time of examination is also shown. Whereas anemia was present in both groups, the difference in the frequency of anemia was not significant. A few patients in each group were also thrombocytopenic at the time of examination. This finding was also not statistically significant. Fifty-three percent of the instances of an extended marrow RE pattern had granulocytopenia compared with only 21% of the instances without marrow extension. This difference was statistically significant. These results suggest that suppression of hematopoiesis, more particularly suppression of granulocytopenia as reflected by the peripheral blood counts, was associated with the extended marrow patterns observed. The marrow suppression and extended marrow pattern were frequent concomitants to aggressive combination chemotherapy.

Fifteen marrow RE patterns of patients with Hodgkin's disease, lymphoma, metastatic cancer, or renal transplant, who were granulocytopenic following aggressive chemotherapy were compared with patterns observed in 13 patients with granulocytopenia not associated with chemotherapy or radiotherapy (Table 3). Patients with leukemia, hemolytic anemia, myeloproliferative disorders, and vitamin B<sub>12</sub> or folic acid deficiency were excluded from consideration. Twelve of the 15 instances of granulocytopenia following chemotherapy showed

TABLE 1. INITIAL RE MARROW PATTERNS IN 26 PATIENTS WITH LYMPHOMA OR HODGKIN'S DISEASE\*

Therapy	Not		Total
	extended	Extended	
None	8	0	8
Radiation	3	2	5
Chemotherapy	2	3	5
Radiation and chemotherapy	1	7	8

\* Seven of these patients with significant change in therapy, complete blood counts, or marrow RE patterns had a total of 12 additional examinations (see Table 2).

TABLE 2. RE MARROW PATTERNS AND PERIPHERAL BLOOD ABNORMALITIES IN HODGKIN'S DISEASE OR LYMPHOMA\*

Marrow pattern	Examinations	Hemato-	Granulo-	Platelets
		crit <38 Vol%	cytopenia†	<150,000/mm <sup>3</sup>
Not extended	19	7 (37%)	4 (21%)	2 (11%)
Extended	19	9 (47%)	10 (53%)‡	6 (32%)

\* Thirty-eight examinations in 26 patients. Twelve instances of a significant change in therapy, blood counts, or marrow RE patterns which occurred in 7 patients are included (details of these 7 patients presented in Table 5).

† Below 3,089/mm<sup>3</sup> in white males or 2,316/mm<sup>3</sup> in black males.

‡ Statistically significant p < 0.05.

TABLE 3. MARROW RE PATTERNS IN GRANULOCYTOPENIA\*

	Chemotherapy induced†		No chemotherapy‡	
	Ex-extended	Not extended	Ex-extended	Not extended
Examinations	12 (15)	3 (15)	0 (13)	13 (13)
Anemia	9 (15)	0 (15)	—	2 (13)
Thrombocytopenia	9 (15)	1 (15)	—	5 (10)
Reticulocytopenia	6 (7)	—	—	0 (8)

\* Below 3,089 granulocytes/mm<sup>3</sup> in white males or 2,316 granulocytes/mm<sup>3</sup> in black males.

† Includes ten instances of Hodgkin's disease or lymphoma, 3 patients with metastatic carcinoma, and 2 patients with renal transplants.

‡ Includes 13 patients with unexplained granulocytopenia, familial neutropenia, or connective tissue disease.

|| Parentheses indicate number in which data was obtained.

extended marrow patterns. Usually, thrombocytopenia or anemia was also demonstrated. An inappropriate reticulocyte response to anemia was observed in six of seven instances in which reticulocyte counts were obtained. Conversely, in all 13 instances of granulocytopenia not associated with chemother-

apy no extension of the marrow pattern was present although anemia or thrombocytopenia was observed.

Five of the patients with chemotherapy-induced granulocytopenia and extended marrow RE patterns also had fever and toxicity at the time of imaging or shortly before. To evaluate the effect of infection on the marrow RE pattern, the bone marrow scintiphotos of seven patients without primary hematologic disease who had severe, acute pulmonary bacterial infections were evaluated (Table 4). Four of the seven patients had an extended RE marrow pattern and an absolute granulocytosis ( $>7,000/\text{mm}^3$ ). Two of the three patients without extended patterns had no granulocytic response to infection at the time of examination. These results suggest that the marrow RE activity extends into the peripheral marrow space in response to bacterial infection and associated granulocytic hyperplasia of the marrow.

**TABLE 4. RE MARROW PATTERNS AND PERIPHERAL BLOOD ABNORMALITIES IN SEVEN PATIENTS WITH ACUTE PULMONARY INFECTION**

Marrow pattern	Pa-tients exam-ined	Hemato-crit <38 vol%	Granulo-cytes >7000/ $\text{mm}^3$	Platelets <150,000/ $\text{mm}^3$
Not ex-tended	3	2	1	—
Extended	4	1	4	1*

\* Platelet counts were obtained in only 2 patients.

The relationship between the RE marrow pattern and peripheral blood counts was examined in seven patients with lymphoma or Hodgkin's disease in whom serial studies were performed following initiation or continuation of therapy (Table 5). Three patients (1–3) showed no extension of the marrow during or following chemotherapy. At the time of the last examination each patient had normal peripheral blood counts. Although all three patients had demonstrated transient granulocytopenia or anemia, it was not severe or of sufficient duration to alter the chemotherapeutic regimen. Three patients (4–6) who had extended RE marrow patterns when first examined developed further extension of the marrow RE phagocytic activity in association with continued administration of chemotherapy. All three patients were anemic, thrombocytopenic, or granulocytopenic for long periods of time during their course, which limited the amount of chemotherapy that could be administered.

One patient (7) was examined before and 8 months after completion of radiation therapy. At the time of the second examination the patient was anemic, granulocytopenic, and had developed an extended RE marrow pattern.

These data suggest that the extended RE marrow pattern in these patients (4–7) is associated with radiation or chemotherapy-induced marrow injury reflected by prolonged suppression of peripheral blood counts and limited marrow tolerance to chemotherapeutic drugs.

**TABLE 5. RE MARROW PATTERNS, THERAPY AND PERIPHERAL BLOOD ABNORMALITIES (PBA) IN SERIAL STUDIES ON SEVEN PATIENTS WITH HODGKIN'S DISEASE OR LYMPHOMA**

Patient	Prior therapy	Initial pattern	PBA	Interval/therapy	Second pattern	PBA	Interval/therapy	Third pattern	PBA	Interval/therapy	Fourth pattern	PBA
1	None	0	A	6 months/chemo	0	—						
2	Rad	0	—	10 months/chemo	0	A,G	6 months/none	0	—			
3	Chemo	0	G	18 months/chemo	0	—						
4	Chemo	+	—	6 months/chemo	++	G,T						
5	Chemo	+	A,G	5 months/chemo	+	A	5 months/chemo	++	G,T	5 months/chemo	++	A,G,T
6	Comb	+	—	9 months/chemo	+	A	13 months/chemo	+	G	2 months/chemo	++	A,T
7	None	0	—	12 months/rad	+	A,G						

Rad = Radiation therapy  
Chemo = Chemotherapy  
Comb = Combined radiation and chemotherapy

0 = No marrow extension  
+ = Marrow extension  
++ = Further marrow extension  
A = Anemia

G = Granulocytopenia  
T = Thrombocytopenia  
— = No PBA abnormalities

## DISCUSSION

Accelerated blood clearance of colloids has been reported in patients with lymphoma or Hodgkin's disease (4,5). In the present study a nonextended marrow RE pattern was observed in all untreated patients with Hodgkin's disease or lymphoma. An association of an extended RE marrow pattern was demonstrated in patients with lymphoma or Hodgkin's disease only following treatment with radiation, chemotherapy, or a combination of both radiation and chemotherapy. The marrow RE extension may be indicative of a generalized stimulation of the reticuloendothelial system. It has been suggested that marrow RE extension reflects a compensatory mechanism by which the hematopoietic tissue extends into the long bones to compensate for marrow cells ablated by radiotherapy or chemotherapeutic drugs (6,7). If the compensatory mechanism were effective, however, the peripheral blood counts of patients with extension of the marrow should be similar to blood counts of patients without extended marrow. In contrast, our results indicate an association between the extended marrow pattern and peripheral blood manifestations of drug-induced marrow suppression, specifically granulocytopenia.

That the observed RE marrow extension in patients with Hodgkin's disease or lymphoma is specifically associated with chemotherapy-induced granulocytopenia is further suggested by the lack of marrow RE extension in patients with granulocytopenia due to other causes and the demonstration of marrow RE extension in patients with renal transplants or metastatic carcinoma, granulocytopenic secondary to chemotherapy, or immunosuppression.

An alternative explanation for the marrow extension seen in patients treated with chemotherapeutic agents is superimposition of a subclinical infectious process. Augmented clearance of colloidal material from the blood of patients with bacterial infections has been reported previously (8) and may be related to increased marrow phagocytic activity as well as increased activity in the liver and spleen. This phenomenon appears similar to the extension of marrow RE activity observed with hemolytic anemia and erythroid hyperplasia (6,9). We observed marrow extension in four of seven patients with acute bacterial pulmonary infections. An association between the marrow RE extension and the presence of granulocytosis was seen in this patient group. Whereas these data in no way obviate the possibility that the marrow extension observed in patients with treated Hodgkin's disease or lymphoma was due to superimposed infection, there was no documentation of an infectious agent despite an intensive search in these patients.

Most of the patients with treated Hodgkin's disease or lymphoma who demonstrated extended marrow RE patterns had either intolerance to chemotherapeutic agents, manifested by prolonged and severe cytopenia, before imaging, or developed intolerance subsequently. In contrast, patients with nonextended marrow RE patterns had tolerated chemotherapy well up to the time of examination. This suggests that extension of the marrow RE pattern indicates the existence of a limited marrow tolerance to chemotherapy. Further support of this hypothesis is provided by the evaluation of sequential studies of seven patients during and following therapy. Three of these patients tolerated chemotherapy well and developed no extension of the RE marrow pattern. Three other patients tolerated chemotherapy poorly as manifested by prolonged and severe cytopenia which necessitated alteration in the chemotherapeutic regimen. The latter three patients demonstrated RE marrow extension when first examined and further extension as the chemotherapy was continued. One additional patient had no extension of the RE marrow pattern before treatment but 8 months following radiation therapy had developed an extended marrow pattern, anemia, and granulocytopenia.

It is possible that the extended RE marrow patterns observed may be associated primarily with advanced disease (4,5). Since this group of patients is most likely to receive combination chemotherapy, the association of the extended marrow RE pattern with intensive drug therapy may be incidental. The observation of extended marrow RE patterns in renal transplant patients treated with immunosuppressive therapy militates against this explanation.

The mechanism by which the bone marrow expands to the peripheral sites in association with anemia, granulocytopenia, or granulocytosis involves multiple factors. The role of opsonins, redistribution of colloidal particles, leukopoietins, and alterations in local regional blood flow remain to be elucidated. However, on the basis of the present data it appears that extension of the reticuloendothelial marrow pattern occurs in patients with Hodgkin's disease or lymphoma who have been treated with chemotherapy or radiation therapy. This extension is secondary to marrow injury and the presence of an extended pattern may be predictive of limited tolerance to chemotherapeutic agents. The presence of a nonextended marrow pattern in patients with granulocytopenia during chemotherapy may indicate transiency of the granulocytopenia and the presence of marrow reserve.

## ACKNOWLEDGMENT

This work was presented in part to the 20th Annual Meet-

ing of the Society of Nuclear Medicine, Bal Harbour, Florida, June 1973.

REFERENCES

1. VAN DYKE D, SHKURKIN C, PRICE D, et al: Differences in distribution of erythropoietic and reticuloendothelial marrow in hematologic disease. *Blood* 30: 364-374, 1967
2. KNISELEY RM: Marrow studies with radiocolloids. *Semin Nucl Med* 2: 71-85, 1972
3. BROUN GO, HERBIG FK, HAMILTON JR: Leukopenia in Negroes. *N Engl J Med* 275: 1410-1413, 1966
4. GROCH GS, PERILLIE PE, FINCH SC: Reticuloendothelial phagocytic function in patients with leukemia, lymphoma and multiple myeloma. *Blood* 26: 489-499, 1965
5. SHEAGREN JN, BLOCK JB, WOLFF SM: Reticuloendothelial system phagocytic function in patients with Hodgkin's disease. *J Clin Invest* 46: 855-862, 1967
6. ROSENTHALL L, CHARTRAND R: Radionuclide imaging of the bone marrow. *Can Med Assoc J* 100: 54-61, 1969
7. KNISELEY RM, ANDREWS GA, EDWARDS CL, et al: Bone marrow and skeletal scanning. *Radiol Clin North Am* 7: 265-280, 1969
8. WAGNER HN, IIO M, HORNICK RB: Studies of the reticuloendothelial system (RES) II. Changes in the phagocytic capacity of the RES in patients with certain infections. *J Clin Invest* 42: 427-434, 1963
9. VAN DYKE D, ANGER HO: Patterns of marrow hypertrophy and atrophy in man. *J Nucl Med* 6: 109-120, 1965

**NORTHERN AND SOUTHERN CALIFORNIA CHAPTERS  
SOCIETY OF NUCLEAR MEDICINE**

**Annual Conjoint Meeting  
San Francisco, California**

**October 25-26, 1974**

**Contact: CALVIN PLUMHOF, M.D.  
711 D St., San Rafael, Calif. 94901**