

showed that the number of scattered photons with energy between 125 and 140 keV was the same as the number of scattered photons with energy between 91 and 102 keV. The effective number of recorded scattered photons in the photopeak window can therefore be reduced by subtracting from the photopeak counting rate the counting rate simultaneously recorded in the scatter interval 91–102 keV. When this is done the corrected line-spread function be-

comes nearly the same as the “geometrical” component of the line-spread function. Since the modulation transfer function is the convolution of the line-spread function, a narrower line-spread function results in an improvement in the MTF.

PETER BLOCH

TOBY SANDERS

Hospital University of Pennsylvania
Philadelphia, Pennsylvania

ADDITIONAL DATA ON HEPATIC FLOW STUDIES

The increasing importance of hepatic flow studies with gamma camera is shown by the report of Waxman, Apau, and Siemsen (1).

Spencer had pointed out that abnormal intra-abdominal structures, other than within the liver, may be visualized during the flow study by filling of the radioisotope to an unusual area (2). It is

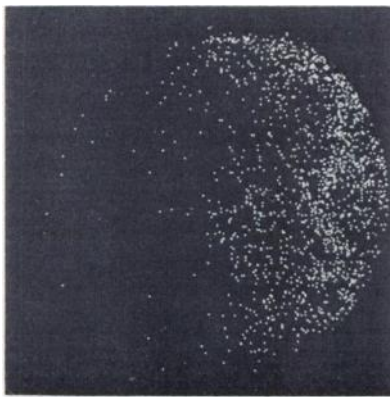


FIG. 1. Displacement of aorta to right is seen. Early flow right of aorta is due to diffusely enlarged liver with metastases.

also possible to recognize abnormal intra-abdominal masses otherwise than by filling of the radioisotope to that area.

An example is shown in Fig. 1. The examination was done after i.v. bolus injection of 10 mCi $^{99m}\text{TcO}_4^-$ in a 60-year-old woman. A displacement of the abdominal aorta to the right is seen in the picture. The early flow of the isotope at the right of the aorta is due to a diffusely enlarged liver with metastases. The displacement of the aorta was due to a left ovarian tumor proved by laparotomy.

VEHBI TIRNAKLI

ROLAND BLOCHEEL

Kliniek voor Radiotherapie en Kerngeneeskunde
State University-Akademisch Ziekenhuis
Ghent, Belgium

REFERENCES

1. WAXMAN AD, APAU R, SIEMSEN JK: Rapid sequential liver imaging. *J Nucl Med* 13: 522–524, 1972
2. SPENCER RP: Additional data on hepatic flow studies. *J Nucl Med* 14: 250, 1973

THE AUTHOR'S REPLY

We agree with the findings of Tirnakli. We have found displacement of the abdominal aorta in a variety of disorders including organomegaly, tumor, abscess, aneurysm of the aorta, and simply a tortuous aorta. We still prefer Tc-sulfur colloid as the isotope in all hepatic abdominal flows for reasons described in our reference in Tirnakli's letter.

ALAN D. WAXMAN

LAC/USC Medical Center
Los Angeles, California

REFERENCE

1. WAXMAN AD, APAU R, SIEMSEN JK: Rapid sequential liver imaging. *J Nucl Med* 13: 522–524, 1972

THE AUTHOR'S REPLY

Deviation of the aorta may be due to either defects in the vessel or to extrinsic factors (such as the tumor pointed out by Tirnakli). Several groups are now at work cataloging the incidence and significance of the finding of aortic deviation on flow studies. We would suggest that ^{99m}Tc -sulfur colloid is pref-

erable to pertechnetate since it allows a static image of the liver to be obtained for comparison with the flow.

RICHARD P. SPENCER

Yale University School of Medicine
New Haven, Connecticut