

RADIONUCLIDE SCANNING OF THE LIVER IN PRIMARY

HEPATIC CANCER: AN ANALYSIS OF 202 CASES

J. Levin, E. W. Geddes, and M. C. Kew

Johannesburg General Hospital and University of the Witwatersrand, Johannesburg, South Africa

**Radionuclide liver scans on 202 patients with primary cancer of the liver were reviewed. With one exception, all were abnormal. A single filling defect was present in 72% of the patients, two or more defects in 15%, and extensive patchy replacement of liver tissue in 12%. Two patients showed a picture indistinguishable from that seen in hepatic cirrhosis. The lesions occurred most commonly in the right lobe of the liver. The importance of doing a right lateral scan in addition to an anterior scan and of marking the palpable edge of the liver was emphasized by certain cases. Hepatic scintiscanning proved to be a more sensitive indicator of the presence of a primary hepatic tumor than biochemical disturbances. There were, however, no features on the scan which made it possible to distinguish between a primary tumor and other space-occupying or infiltrative lesions of the liver. No obvious correlation could be demonstrated between the presence of alpha-fetoprotein in the serum and the extent of the tumor on the scan. Hepatic scintiscanning is valuable in determining the optimal site for percutaneous biopsy and in assessing suitability for surgical resection.**

The value and limitations of hepatic scintiscanning in the diagnosis of metastatic liver disease have been established in several large studies (1,2). Less well documented is the place of the radionuclide liver scan in demonstrating the presence of primary hepatic cancer. This is due primarily to the rarity of the tumor in most parts of the world (3-5). Primary cancer of the liver is common in the indigenous population of Southern Africa (4,6), and many cases are encountered in black laborers employed in the South African gold-mining industry. It has therefore been possible to perform liver scans on a large series

of such patients, and in this paper the value of hepatic scintiscanning in the diagnosis of primary cancer of the liver is assessed.

MATERIALS AND METHODS

For the past 8 years any mineworker suspected of having primary hepatic cancer has been admitted to a central mine hospital. To date there have been 666 such patients, and radionuclide liver scans have been performed in 396. Of the latter, 209 were subsequently proven histologically to have primary cancer of the liver; the remainder were shown to have a variety of other causes for hepatomegaly including, most commonly and in order of frequency, cirrhosis, amebic abscess, metastatic liver disease, congestive cardiac failure, viral hepatitis, and tuberculous hepatitis. Initially  $^{131}\text{I}$ -rose bengal (dose 150  $\mu\text{Ci}$ ) was the radiopharmaceutical used, but this was soon replaced by  $^{198}\text{Au}$ -colloid (dose 150-250  $\mu\text{Ci}$ ). Lately  $^{99\text{m}}\text{Tc}$ -sulfur colloid (1.5-2.0 mCi) has been used. The scanning instruments used were a Picker 3-in. and a Siemens 5-in. rectilinear scanner, and assessments were made on both the photoscan and colorsan. For the first 2 years only an anterior scan was recorded; thereafter anterior and right lateral scans were performed. To ensure an objective assessment of the scans, all 396 were examined by two of the authors (JL and MCK) without knowing which of the patients had a primary tumor and which had another cause for hepatomegaly.

In almost all patients, the serum bilirubin, alkaline phosphatase, and transaminase levels at the time of hepatic scintiscanning were known. A comparison was made between the alkaline phosphatase level as an index of a space-occupying or infiltrative lesion

Received May 18, 1973; revision accepted Oct. 15, 1973.

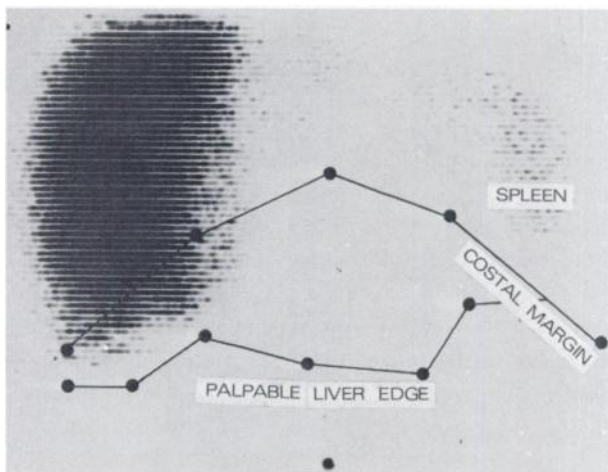
For reprints contact: M. C. Kew, Dept. of Medicine, University of Witwatersrand Medical School, Hospital St., Johannesburg, South Africa.

in the liver (7) and the findings on liver scan. The presence or absence of alpha-fetoprotein (AFP) in the serum was known in all but six patients, and this was correlated with the extent of the tumor as judged by the liver scan.

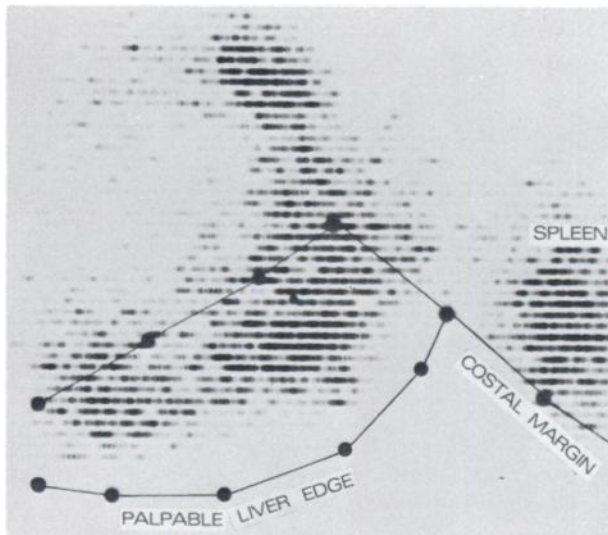
### RESULTS

Of the 209 scans belonging to patients in whom primary hepatic cancer was proven by percutaneous biopsy, laparotomy, or necropsy, 7 were technically poor and were discarded. Of the remaining 202 scans,  $^{198}\text{Au}$ -colloid was the radiopharmaceutical used in 121,  $^{99\text{m}}\text{Tc}$ -sulfur colloid in 50, and  $^{131}\text{I}$ -rose bengal in 31.

A single defect was demonstrated in 145 patients




**FIG. 1.** Anterior scan with  $^{198}\text{Au}$ -colloid showing single large filling defect in left lobe and medial segment of right lobe of liver.



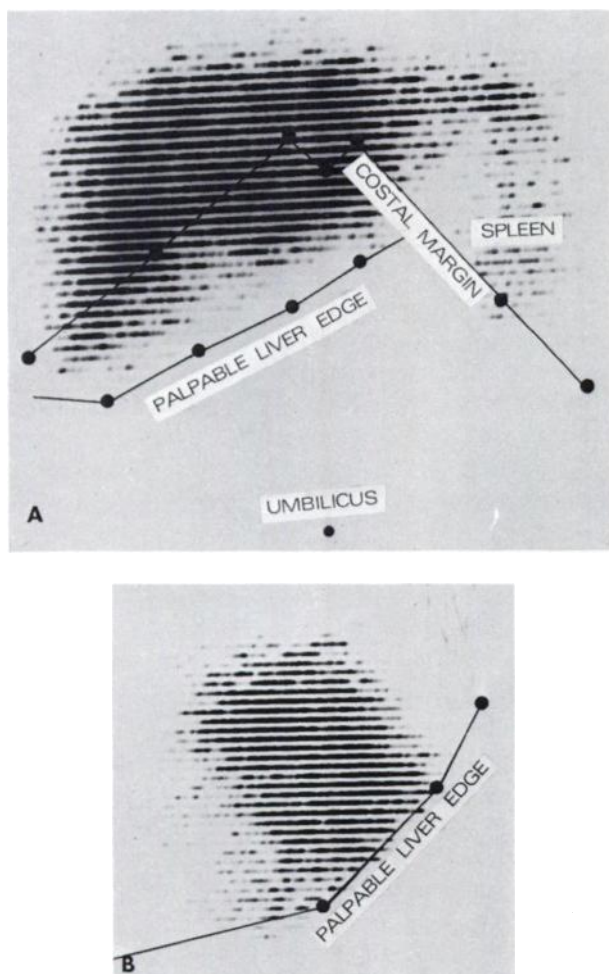
**FIG. 2.** Anterior scan with  $^{99\text{m}}\text{Tc}$ -sulfur colloid showing two large filling defects, one in right and other in left lobe.

(72%), 2 or more defects in 30 (15%), and extensive patchy replacement of liver tissue in 24 (12%). Examples are shown in Figs. 1–3. In two patients, a slight patchy decrease in uptake of the radiopharmaceutical was present, giving a picture indistinguishable from that seen in hepatic cirrhosis. Both were subsequently shown to have cirrhosis in addition to a primary tumor. The scan was thought to be normal in one patient. He presented with a swelling over the right scapula which was shown to be a metastasis from a primary cancer of the liver. In two patients the anterior scan was normal but an obvious posterior defect was visible on the lateral scan (Fig. 4). The single defects were frequently massive: 52 were complete (no or very little activity in the defect), 46 were partial (some radioactivity in the defect), and 48 were complete in some part and partial in the remainder. When there was more than one defect, these were either partial or mixed partial and complete, although two complete defects were present in three patients. In six patients with a single defect, the remaining liver tissue showed a mild patchy infiltration compatible either with many smaller neoplastic lesions or cirrhosis, or both. The filling defects were situated in both lobes of the liver in 39% of the patients, in the right lobe only in 57%, and in the left lobe only in 4%. In four patients the tumor was most obvious along the inferior border of the liver, and the defect would have been missed if the palpable edge of the liver was not marked (Fig. 5). The liver was enlarged (by impression only; no measurements were taken) in all but seven patients (96.5%).

The serum alkaline phosphatase, bilirubin, and transaminase levels were known in 181 patients. The



**FIG. 3.** Anterior scan with  $^{198}\text{Au}$ -colloid showing extensive patchy replacement of liver tissue.



**FIG. 4.** Anterior and right lateral scans with  $^{99m}\text{Tc}$ -sulfur colloid showing normal anterior scan but obvious posterior defect on right lateral scan.

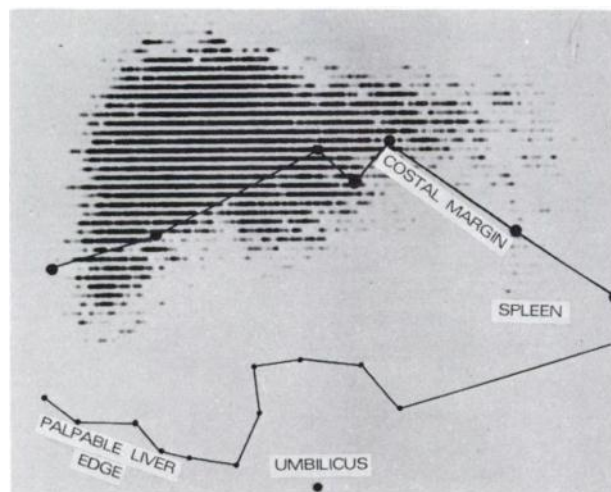
alkaline phosphatase level was raised in 156 (86%). In 95 (53%), it was significantly increased (greater than 20 King Armstrong units) with normal or only slightly raised serum bilirubin levels, a biochemical picture which indicates the presence of space-occupying or infiltrative disease of the liver (7). The liver scan was clearly abnormal in 85 patients (46%) in whom this biochemical evidence of space-occupying or infiltrative hepatic disease was lacking and in 16 patients (9%) in whom tests of liver function were completely normal. BSP excretion was, however, not measured in these patients. AFP was demonstrated in the serum of 69% of the patients. There was no obvious correlation between the presence of AFP and the extent of the tumor as judged by the liver scan.

#### DISCUSSION

Definitive diagnosis of primary cancer of the liver depends upon the histological demonstration of the features of the tumor. The condition can, however,

often be suspected from the clinical findings and the results of certain investigations (8,9). The presence of alpha-fetoprotein in the serum is strongly suggestive of primary liver cancer but its positivity rate has a striking geographical variation and in many parts of the world false-negative results are more common than positive ones. Occasional false-positive results have also been reported (8). Either coeliac axis arteriography or trans-splenic portal venography may show evidence of a malignant circulation or space-occupying lesion in the liver, but neither procedure is without discomfort or risk to the patient. Radio-nuclide scanning of the liver is simple and quick and involves minimal discomfort and negligible radiation hazard to the patient. Its value in demonstrating the presence of liver abscesses and metastases is well established. Less experience has been had in primary cancer of the liver, but here too it has proved useful in confirming the presence of a filling defect and indicating the best site for percutaneous biopsy (8-10).

In the present study based on 202 black patients with primary hepatic cancer, the liver scan was found to be abnormal almost without exception. This is in accord with previous experience. In two series from the United Kingdom, Kew, et al (8) and Sharpstone, et al (9) found one or more filling defects in 30 of 34 and 36 of 38 patients, respectively, and in a study on South African blacks Bieler, et al (10) found the scan to be invariably abnormal. A single filling defect was demonstrated in approximately three-quarters of the present patients and this was frequently massive; two or more defects were present in 15% and extensive patchy replacement of liver tissue in 12%. In a few patients the scintiscan picture was indistinguishable from that seen in hepatic cirrhosis. This may have been due



**FIG. 5.** Anterior scan with  $^{198}\text{Au}$ -colloid illustrating importance of marking palpable liver edge.

either to multiple small neoplastic lesions, cirrhosis, or both. Just over 50% of Southern African black patients with primary cancer of the liver have concomitant cirrhosis (11). In one instance the liver scan was judged to be normal. The disease was advanced in this patient as is shown by the fact that he had skeletal metastases at the time of his admission. The importance of doing a right lateral scan in addition to an anterior scan was illustrated in two patients in whom the anterior scan showed only a localized patchy decrease in uptake of the radionuclide but in whom an obvious posterior defect was demonstrated on the right lateral scan. This point has previously been made in relation to other space-occupying lesions in the liver (12). Another possible cause for misinterpretation of liver scans is failure to relate the scintiscan picture to the palpable edge of the liver; in some of our cases the tumor was most obvious along the inferior border of the liver and unless the palpable margin had been marked, the scan would have appeared normal. In these cases also, difficulty may be experienced in distinguishing between hepatic and extrahepatic lesions.

The liver scan proved to be a more sensitive indicator of an infiltrative or space-occupying lesion in the liver than the biochemical criterion of a significantly raised serum alkaline phosphatase level with a normal or only slightly increased serum bilirubin level (7). This is also true in the case of hepatic metastases (1). It has repeatedly been shown that small lesions (less than about 3 cm) will not be detected by hepatic scintiscanning and this applies equally to primary hepatic cancer. AFP is found in the serum of approximately 70% of South African blacks with primary liver cancer (13). No obvious correlation could be demonstrated between the presence of AFP in the serum and the extent of the tumor as judged by the scan. In many patients in whom AFP was not demonstrated, the scan was clearly abnormal.

As in previous studies, there were no features on the liver scan which distinguished between primary hepatic cancer and other space-occupying or infiltrative lesions of the liver. Nevertheless, the liver scan serves a most useful purpose in indicating the optimal site for biopsy and contributes significantly

to the high frequency with which a definitive diagnosis can be made by percutaneous biopsy.

With the present poor results obtained in treating this condition with cytotoxic drugs and radiotherapy, surgical resection of the tumor, if possible, offers the patient his best chance of survival. The scan may also be helpful in this respect.

#### ACKNOWLEDGMENTS

The South African Primary Liver Cancer Research Unit is supported by the South African Chamber of Mines and the National Cancer Association of South Africa. The authors are indebted to the mine medical officers for referring the patients and to the other members of the research group for their cooperation.

#### REFERENCES

1. NAGLER W, BENDER MA, BLAU M: Radioisotope scanning of the liver. *Gastroenterology* 44: 36-43, 1963
2. ACHAVAL A, TAUXE WN, GAMBILL EE: Scintillation scanning of the liver. *Mayo Clin Proc* 40: 206-215, 1966
3. HOYNE RM, KERNOHAN JW: *Arch Intern Med* 79: 532-554, 1947
4. BERMAN C: *Primary Carcinoma of the Liver*, London, Lewis, 1951, pp 5-18
5. MACDONALD RA: Primary carcinoma of the liver: a clinico-pathologic study of 109 cases. *Arch Intern Med* 99: 266-279, 1957
6. HIGGINSON J, OETTLÉ A: Cancer incidence in Bantu and Cape coloured races of South Africa. Report of a cancer survey in Transvaal; 1953-1955. *Natl Cancer Inst* 24: 589-671, 1960
7. ROSS RS, IBER FL, HARVEY AM: The serum alkaline phosphatase in chronic infiltrative disease of the liver. *Am J Med* 1: 850-856, 1956
8. KEW MC, DOS SANTOS HA, SHERLOCK S: Diagnosis of primary cancer of the liver. *Br Med J* 4: 408-411, 1971
9. SHARPSTONE P, RAKE MO, SHILKIN KB, et al: The diagnosis of primary malignant tumours of the liver. *Q J Med (New Series)* 41: 99-110, 1972
10. BIELER EU, MEYER BJ, JANSEN CR: Liver scanning as a method for detecting primary liver cancer. Report on 100 cases. *Am J Roentgenol Radium Ther Nucl Med* 115: 709-716, 1972
11. BERSOHN I, PURVES LR, GEDDES EW: Liver function tests in primary cancer of the liver in the Bantu. In *Liver Cancer*, Lyon, International Agency for Research on Cancer, 1971, pp 158-167
12. CUARON A, GORDON F: Liver scanning. An analysis of 2,500 cases of amebic hepatic abscesses. *J Nucl Med* 11: 435-439, 1970
13. PURVES LR, BERSOHN I, GEDDES EW: Serum alpha-fetoprotein and primary cancer of the liver. *Cancer* 25: 1261-1270, 1970