

# RAPID EVALUATION OF HEPATIC SIZE ON RADIOISOTOPE SCAN

Arthur T. Rosenfield and Peter B. Schneider

*Beth Israel Hospital and Harvard Medical School, Boston, Massachusetts*

***Multiple single measurements of hepatic size were performed on 100 random liver scans. These values were correlated with the presence or absence of hepatic disease. The best indicator of liver pathology is shown to be a vertical measurement halfway between the xiphoid and right liver margin. An upper limit of normal can be chosen which provides an index of hepatic disease when exceeded. In our series this upper limit was 15.5 cm but this number may vary with technique. Diagonal measurements, maximum vertical and horizontal measurements, and area calculations provided a less reliable upper limit in our series. Thus a simple technique has been defined which provides a valuable tool for radioisotope scan evaluation.***

Hepatic enlargement is an index of liver disease. Various approaches have been used to relate measurement of liver size on radioisotope scans to actual hepatic weight. Naftalis and Leevy have demonstrated that scan size measured by planimetry correlated well with hepatic size at autopsy (1). Yagan, et al devised a method using multiple levels of background erase and found a good correlation between scan and postmortem findings (2). Rollo and Deland in 1968 described a complicated approach to volume calculation using ellipses and lines drawn on AP and lateral scan projections (3). All three of these methods require too much effort to be used as a routine screening approach. In 1965 McAfee, et al advocated a formula encompassing maximum vertical and horizontal measurements of liver size on hepatic scan (4). In 1972 Drum, et al reviewed 650 liver scans (5) and used McAfee's method to determine hepatomegaly on a given scan. They found hepatomegaly defined by these criteria to be a major source of false-positive readings and suggested that "our criteria for hepatomegaly warrant re-evalua-

tion". All of these previous studies of liver size have concentrated on defining normal values for the particular measurement under consideration but have not examined the discrimination between the presence or absence of liver disease afforded by such measurements. The present study is an evaluation of various single rapidly obtained hepatic measurements on scan and their correlation with liver pathology.

One hundred liver scans were chosen randomly from studies performed on patients of the general medical and surgical services between 1967 and 1972 (age range of patients 24–85 with average 60 years). Approximately equal numbers of studies were done with colloidal  $^{198}\text{Au}$  and  $^{99\text{m}}\text{Tc}$ -sulfur colloid. The scans were performed on a 5-in. dual-head rectilinear scanner with the use of image diffusion (data blending) and similar technical factors were used in all cases. The xiphoid and the costal margin were indicated on the scan. Figure 1 shows the parameters which were noted. Measurement A represents the vertical dimension of the liver at a point halfway between the xiphoid and the right liver margin. Measurement B is the chord between the highest and lowest points of the liver projection. The maximum horizontal distance is represented by C and maximum vertical distance by D. Each patient's hospital chart was independently reviewed. All patients had determinations of SGOT and alkaline phosphatase and most also had leucine amino peptidase (LAP) determinations. For data analysis, the highest value of these enzymes recorded during the admission in which the scan was performed was noted. Autopsy or biopsy results, if done within 6 months of the scan, were noted.

Received May 11, 1973; revision accepted Oct. 15, 1973.

For reprints contact: Peter B. Schneider, Beth Israel Hospital, 330 Longwood Ave., Boston, Mass. 02215.

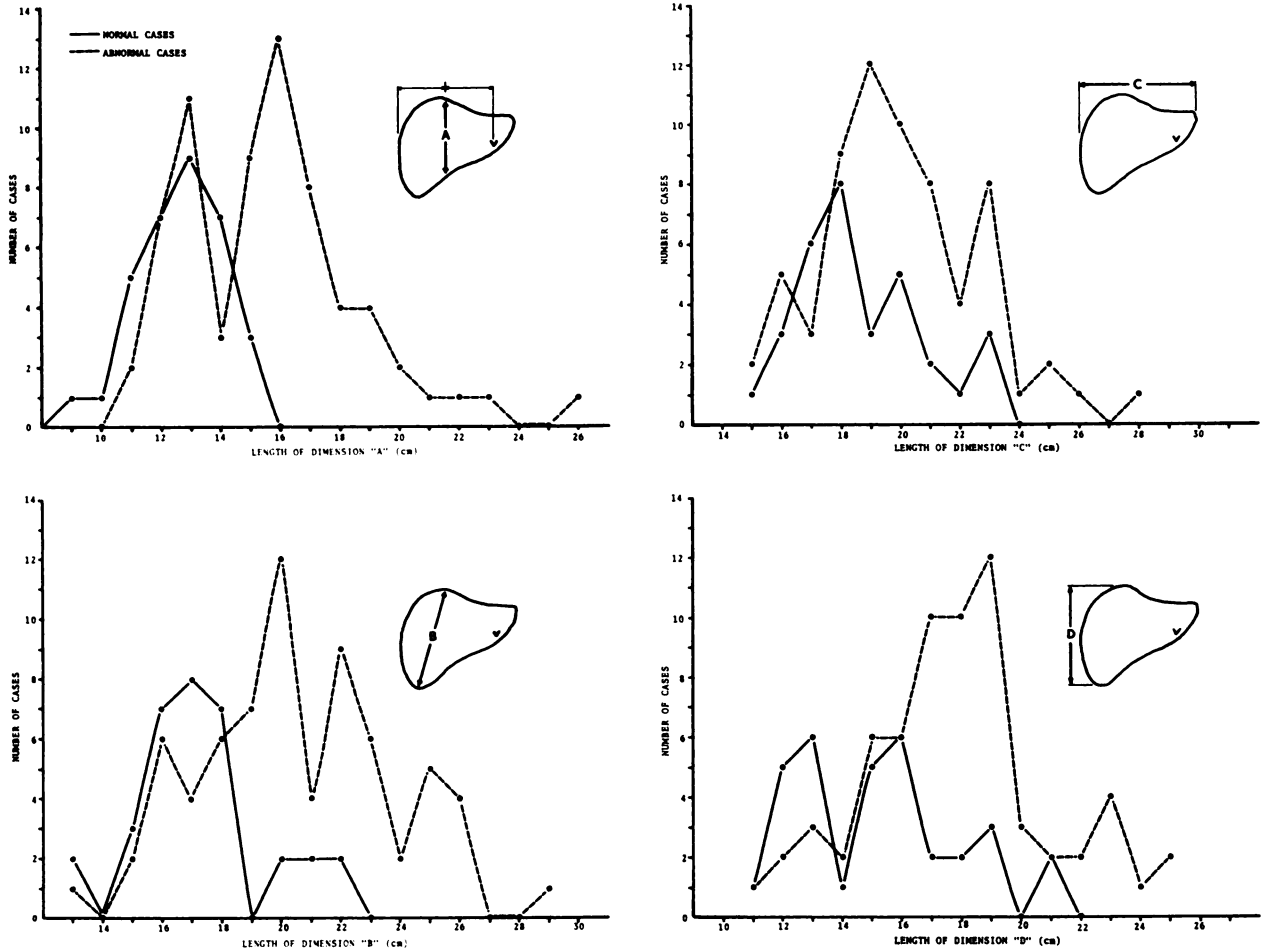


FIG. 1. Size distribution of normal (—) and abnormal (---) livers according to measurement of various dimensions.

Inset on each graph illustrates dimension measured. V on inset represents xiphoid.

## RESULTS

A liver was considered normal if it met all the following criteria:

1. Normal laboratory values (SGOT, LAP, alkaline phosphatase) during the entire hospital admission.
2. No tissue abnormality when tissue was obtained.
3. No focal abnormalities on scan.

Thirty-three of the 100 cases met these criteria. The remaining 67 livers were considered abnormal. Abnormal enzyme values without a tissue diagnosis (SGOT and/or LAP or alkaline phosphatase) were found in 35 of these cases, three had a positive tissue diagnosis of hepatic disease but normal enzyme studies, and 29 had both abnormal laboratory values and a positive tissue diagnosis. The tissue diagnosis included metastatic carcinoma, "fatty change", cirrhosis, chronic hepatitis, bile stasis due to common duct obstruction, and sclerosing angiohamartoma. The average age of our abnormal patients was 58

with a range of 25–84 while that of our normal group was 69 with a range from 24–85 years.

Figure 1A is a graph of the size distribution of the normal and abnormal livers using measurement A. It can be seen that no normal liver measured greater than 15.5 cm while 54% of the abnormal livers exceeded that figure. The scan size (mean  $\pm$  s.d.) of the normals was  $12.7 \pm 1.4$  cm while that of those that were abnormal was  $15.8 \pm 3.1$ . Table 1 shows the average size of the normal and abnormal livers by each of the other measurements. Although in each case the abnormal livers are slightly larger, it can readily be seen from Fig. 1 that measurements B, C, and D lead to significant overlap between normal and abnormal.

However, more important than finding a difference in mean values between abnormal and normal for the various measurements is the ability to determine the upper limit of normal. One can define a length for dimension A (i.e., 15.5 cm) above which 35 of the abnormal cases will fall without including

any of the normal ones and a smaller value (14.5 cm) for this limit will yield only three false-positive cases with 44 true positive ones. By contrast, for similar numbers, if dimension B is used, one must accept 4 false positives for 31 true positives. Dimension C leads to the inclusion of 11 false positives with 35 true positives and D includes 7 normal cases with 37 abnormal ones. For comparison we have also computed the area of the liver scans according to McAfee's formula (4) using dimensions C and D. The distributions of cases based on these areas are similar to those obtained with dimension D, and to discriminate 33 abnormal cases 6 false positives would be generated. No significant difference in size distribution of any of the measurements was found between the 35 livers which were abnormal by enzymes alone and the 32 livers with positive tissue diagnosis.

#### DISCUSSION

There may be wide variations in liver shapes (4), and one might not expect a single linear measurement of the anterior projection of the liver scan to give an accurate representation of liver mass in all cases. Thus a normal liver with a long narrow vertical or horizontal lobe will give a vertical or horizontal measurement that may be well outside of "normal" limits. Our study indeed demonstrates that reliance on these measurements (i.e., C or D) will not define "hepatomegaly" in a sense that allows much discrimination between normal and abnormal. A computation that includes both those dimensions to derive the area of the frontal projection of the scan (4) might be expected to be superior but in our series the area calculation did not provide an upper limit of normal which could discriminate better than the maximum vertical length alone. On the other hand, our dimension A proved empirically to be a more reliable index of liver pathology than the other linear or area measurements.

Since the lower liver edge on a scan may ascend at a steep angle, small horizontal variations in the placement of the line for measurement A may produce significant variations for the value of A in some cases. This may account for the finding that our mean for dimension A (12.7 cm) is smaller than the mean value for liver height (15 cm) in the midclavicular line reported in a series of ten normal liver scans (1). The placement of those vertical dimensions are similar but not exactly the same. Furthermore, the liver edge as it is seen on scan is never a sharp line and its actual placement will vary somewhat with the contrast properties of the final scan image. Thus our normal limits may not be exact for other scanning techniques but, for any

**TABLE 1. VALUES FOR SEVERAL LIVER SCAN DIMENSIONS IN NORMAL AND ABNORMAL CASES**

Dimension	Size (cm or cm <sup>2</sup> )	
	Normal cases	Abnormal cases
A	12.7 ± 1.4	15.8 ± 3.1
B	17.3 ± 2.1	20.0 ± 3.3
C	19.0 ± 2.6	20.2 ± 2.9
D	15.2 ± 2.6	17.7 ± 3.0
Area*	182 ± 45	228 ± 61

All values are mean ± s.d.

\* Area of frontal projection of scan calculated according to formula of McAfee, et al (4).

given technique, normal values may be determined and A would still be the best dimension for the definition of hepatomegaly.

Although no normal liver in our series gave a length of dimension A above 15.5 cm, we would expect that false positives will occur. In particular, a very prominent quadrate lobe could lead to a falsely elevated value for A. Conversely, obviously enlarged livers might give a normal value if dimension A should fall at a very deep incisura in the lower edge due, perhaps, to a prominent umbilical notch or gall-bladder fossa. In the face of such obvious variations of liver anatomy the interpretation of dimension A would have to be modified but our series indicates that strict adherence to the positioning of length A is the best strategy.

Average liver mass varies somewhat with body surface area although there is considerable overlap (6), but linear dimensions on liver scan appear unrelated to age and body build (4) and we would expect that the value of A would change only slightly, if at all, with variations in those factors.

Since many abnormal livers are normal in size, no scan measurement would rule out abnormality, and measurement A can only be used to discover pathology. This would be particularly useful in the evaluation of livers with normal colloid uptake and distribution. In such cases, using measurements C and D to determine hepatomegaly, Drum, et al (5) found 14% false positives. In our series nine such cases met the criterion for hepatomegaly based on length A with no false positives.

In conclusion, we have found that the most reliable simple measurement on the radioisotope scan to indicate hepatic disease is made vertically at a point halfway between the lateral liver edge and the midsternal line. This measurement for a given scanning technique can provide an upper limit of normal which provides an indication of hepatic disease when it is

exceeded. This is true even when no focal defects are present, making this method a valuable tool for scan evaluation.

REFERENCES

1. NAFTALIS J, LEEVY CM: Clinical estimation of liver size. *Am J Dig Dis* 8: 236-243, 1963
2. YAGAN R, MACINTYRE WJ, CHRISTIE JH: Estimation of liver size by multiple cut-off scintillation scanning technique. *Am J Roentgenol Radium Ther Nucl Med* 88: 289-295, 1962
3. ROLLO FD, DELAND FH: The determination of liver mass from radionuclide images. *Radiology* 91: 1191-1194, 1968
4. MCAFEE JG, AUSE RG, WAGNER HN: Diagnostic value of scintillation scanning of the liver. *Arch Intern Med* (Chicago) 116: 95-110, 1965
5. DRUM DE, CHRISTACOPOULOS JS: Hepatic scintigraphy in clinical decision making. *J Nucl Med* 13: 908-915, 1972
6. DELAND FH, NORTH WA: Relationship between liver size and body size. *Radiology* 91: 1195-1198, 1968