

SCINTISCANNING OF PULMONARY DISEASES

WITH ^{67}Ga -CITRATE

Fumio Kinoshita, Teruo Ushio, Akira Maekawa, Rokuro Ariwa, and Atsushi Kubo

Ohkubo Municipal Hospital and Keio University School of Medicine, Tokyo, Japan

Scintiscanning with ^{67}Ga -citrate was performed in 162 patients with various pulmonary diseases. Of the 70 cases of primary pulmonary carcinoma, 62 had a strongly positive and 7 a slightly positive scan and all 18 cases of metastatic pulmonary carcinoma had a positive scan, including a carcinoma of 1–2 cm in diam. According to the histopathological findings, the positive rate for squamous cell carcinoma and undifferentiated carcinoma tended to be higher than that for adenocarcinoma. By indicating the presence of infiltration of lymphatic metastasis in the mediastinum for which the roentgenologic diagnosis is difficult or a tumor which overlaps the heart shadow or is hidden in a large hydrothorax, ^{67}Ga -citrate scanning has contributed valuable information on which to base a decision for operating or choice of surgical method and the establishment of the range of radiotherapy. Otherwise inflammatory lesions (pneumonia, purulent pulmonary infection, pulmonary tuberculosis, etc.) and sarcoidosis had more clearly positive scans in the acute stage than did carcinoma.

Radiopharmaceuticals selectively taken up by malignant tumors have been studied by many investigators. However, they have found none which would be taken up at a consistently high rate and show a clearly positive scintigram so that it might be used extensively for general clinical tests.

Edwards reported in 1969 that ^{67}Ga -citrate accumulated in the lymph nodes of Hodgkin's disease in a larger amount than any other pre-existing nuclide (1). Subsequent studies were performed by many investigators (2–10). The authors have been using this radiopharmaceutical for various malignant tumors, particularly of the lung, since October 1969 (4). The present report concerns the results of tumor

scintigrams using ^{67}Ga -citrate in various pulmonary diseases including 80 cases of pulmonary carcinoma.

MATERIALS AND METHODS

Subjects were in- and out-patients who came to the Ohkubo Municipal Hospital in the period October 1969 to October 1972, consisting of 70 cases of pulmonary carcinoma, 10 of metastatic pulmonary carcinoma after irradiation with ^{60}Co , 18 of metastatic pulmonary carcinoma, 1 of pulmonary metastatic carcinoma after irradiation with ^{60}Co , 4 of pneumonia, 1 of pneumonia after recovery, 4 of bronchiectasis, 2 of lung abscess, 1 of radiation pneumonitis, 12 of pulmonary tuberculosis, 1 of pulmonary granuloma, 3 of mediastinal tumor, and 3 of sarcoidosis, a total of 130.

Intravenous injection of 2 mCi of ^{67}Ga -citrate (supplied by the Philips-Duphar Cyclotron) was followed by scanning 48 hr later in the majority of cases (24 or 72 hr later in the remainder).

The equipment used was Toshiba scintillation scanner 2×2 in. crystal, 19-hole honeycomb collimator with a focal length of 10 cm. At the scan speed of 60 cm/min all of the gamma rays above 80 keV were measured.

RESULTS

Pulmonary carcinoma. There were 70 cases of pulmonary carcinoma, 52 males and 18 females. Those receiving radiotherapy and chemotherapy with various anticarcinogens were excluded (Table 1). Only one had a negative, 7 a slightly positive, and 62 (90%) a strongly positive scan.

Scintigrams in various histopathological types. The histopathological diagnosis could be obtained by exploratory thoracotomy, lymph node broncho-

Received June 15, 1973; original accepted Aug. 31, 1973.

For reprints contact: F. Kinoshita, Department of Radiology, Ohkubo Municipal Hospital, 1-461, Nishiohkubo Shinjyuku, Tokyo, Japan.

TABLE 1. ^{67}Ga ACCUMULATION IN VARIOUS PULMONARY DISEASES

	No. pa- tients	^{67}Ga accumulation		
		(-)	(+)	(++)-(+++)
Lung cancer	70	1	7	62
Lung cancer (after ^{60}Co therapy)	10	5	5	0
Metastasis in the lung	18	0	1	17
Metastasis in the lung (after ^{60}Co therapy)	1	0	1	0
Pneumonia	4	0	1	3
Pneumonia (healing)	1	1	0	0
Lung abscess	2	0	0	2
Radiation pneumonitis	1	0	0	1
Pulmonary tuberculosis (active)	5	0	0	5
Pulmonary tuberculosis (old)	7	6	1	0
Lung granuloma	1	1	0	0
Sarcoidosis	3	0	0	3
Bronchiectasis	4	0	2	2
Mediastinal tumor	3	0	0	3
Total	130	14	18	98

TABLE 2. ^{67}Ga ACCUMULATION IN VARIOUS PULMONARY DISEASES WITH HISTOPATHOLOGICAL FINDINGS

Tumor type	No. pa- tients	^{67}Ga accumulation (%)			
		(+++)	(++)	(+)	(-)
Adenocarcinoma	22	6(27)	15(68)	0(0)	1(5)
Squamous cell carcinoma	12	8(67)	4(33)	0(0)	0(0)
Anaplastic carcinoma	5	3(60)	1(20)	1(20)	0(0)
Oat cell carcinoma	1	1(100)	0(0)	0(0)	0(0)
Alveolar cell carcinoma	1	0(0)	1(100)	0(0)	0(0)

scopic biopsy, and autopsy after pneumonectomy in 41 cases which consisted of 12 of squamous cell carcinoma, 22 of adenocarcinoma, 5 of undifferentiated carcinoma, 1 of alveolar cell carcinoma, and 1 of oat cell carcinoma. Table 2 shows the positive rate in each type, the positive rate in squamous cell carcinoma and undifferentiated carcinoma tending to be higher than that of adenocarcinoma. One case showing a negative picture was found to have papillary tubular mucocellular adenocarcinoma.

Pulmonary metastasis of pulmonary carcinoma.

All of the cases of primary pulmonary carcinoma with intrapulmonary metastasis observed had a clearly positive scan not only in the primary lesion but also in the intrapulmonary metastasis.

Case 1. A 35-year-old woman had complained of cough for several months. Chest x-ray showed nu-

merous sharply demarcated proliferative shadows of varying sizes in the entire lung field bilaterally (Fig. 1). Bronchoscopy revealed discontinuation of the branch of the right B₆. Scintigram showed positive pictures bilaterally in the entire lung field, which appeared like the pulmonary scintigrams with ^{131}I -MAA. Autopsy revealed a primary lesion in the S₆ of the right lower lobe, all others being metastatic adenocarcinoma.

We observed three other cases showing a similar picture.

Metastasis of pulmonary carcinoma into lymph nodes. Demonstration of the primary site of pulmonary carcinoma is relatively easy by means of various roentgenologic diagnoses but it is frequently difficult to learn the presence or absence of lymphatic metastasis in the mediastinum. Such a demonstration is often possible by the scintigram with ^{67}Ga -citrate which provides useful information for operative indication, choice of surgical procedure, and range of radiotherapy (Fig. 2).

Case 2. A 61-year-old woman had a diagnosis of pulmonary carcinoma originating in the B₆ of the right lower lobe. After irradiation of 3,000 rads of telecobalt, hydrothorax was observed in the opposite side, and scintigram was clearly positive in the upper part of the right hilus, mediastinal center, and inside

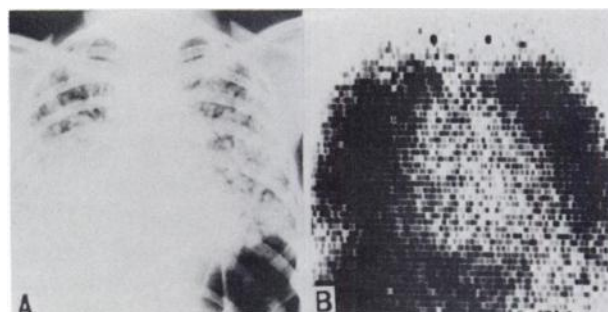


FIG. 1. (A) Chest x-ray shows numerous shadows of varying sizes in entire lung field. (B) Scintigram with ^{67}Ga -citrate is positive in entire lung field similar to pulmonary scintigram with ^{131}I -MAA.

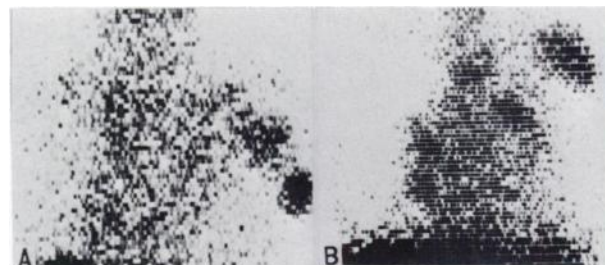


FIG. 2. (A) Scintigram illustrates lymphatic metastasis in axillary lymph node. (B) Scintigram shows pulmonary carcinoma of left B₁₋₂ suggesting presence of lymphatic metastasis in left hilus, right hilus, and region below hilus.

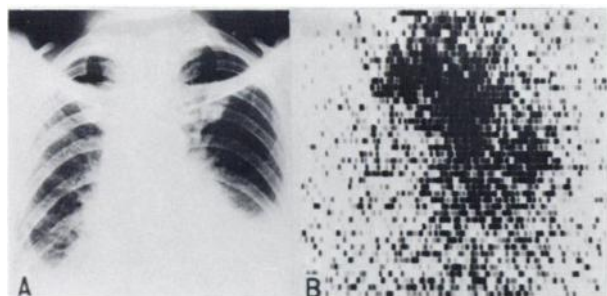


FIG. 3. (A) Chest x-ray shows hydrothorax bilaterally but can not detect metastasis in mediastinum precisely. (B) Scintigram shows positive in upper part of right hilus, mediastinal center, and inside left lower lung as autopsy revealed.

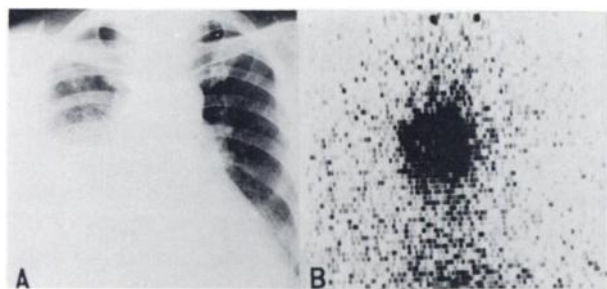


FIG. 4. (A) Chest x-ray shows hydrothorax in right lower lung field. (B) Scintigram clearly demonstrates localized tumor within shadow of hydrothorax.

the left lower lung (Fig. 3). The patient died 2 weeks after the scintiscanning and autopsy revealed a pigeon egg-sized carcinoma in the S_6 of the right lower lobe, a palm-sized tumor in the bronchial branching part and the posterior mediastinal lymph node, and a tumor protruding into the left thoracic cavity in the left posterior side of the heart which agreed well with the findings of the scintigram. The histopathological diagnosis was adenocarcinoma.

Hydrothorax with pulmonary carcinoma. It occurs not infrequently that the affected side of a pulmonary carcinoma is accompanied by voluminous hydrothorax, making it difficult to see the condition of the lung fields by x-ray examination. Of our present cases, there were four in which the entire lung field of one side was not demonstrated at all due to a large amount of hydrothorax or in which bronchoscopy could not be performed due to dyspnea or failed to show the site and extent of the lesion which could be demonstrated by scintigram.

Case 3. A 55-year-old woman had chest pain and cough. Hydrothorax was observed in the right lower lung field on chest x-ray films but bronchoscopy did not visualize the branches of the right middle lobe. Scintigram demonstrated a localized tumor within the shadow of the hydrothorax below the right hilus (Fig. 4). Based on the scintigram, the area for pre-

operative irradiation was determined. Thoracotomy revealed an atelectatic and slightly hard middle lobe and an infiltrative tumor in the base of the right main bronchus and the heart sac in front of the middle lobe.

The histopathological diagnosis was adenocarcinoma.

Pulmonary carcinoma after irradiation with ^{60}Co . There were ten cases of pulmonary carcinoma given radiotherapy. The dose was 3,000–7,000 rads/5–7 weeks and as a rule a total of 5,000–7,000 rads was delivered.

The scintigrams taken after irradiation were only slightly positive (five cases) or negative even in the cases which were strongly positive before treatment.

This was in agreement with reduction or disappearance of tumor on x-ray film after irradiation with ^{60}Co ; thus the radiotherapeutic effect and the decrease in positivity were thought to parallel each other.

Case 4. A 56-year-old woman had a chest x-ray taken because of cough, sputum, and chest pain. There was a large shadow of uneven contour along

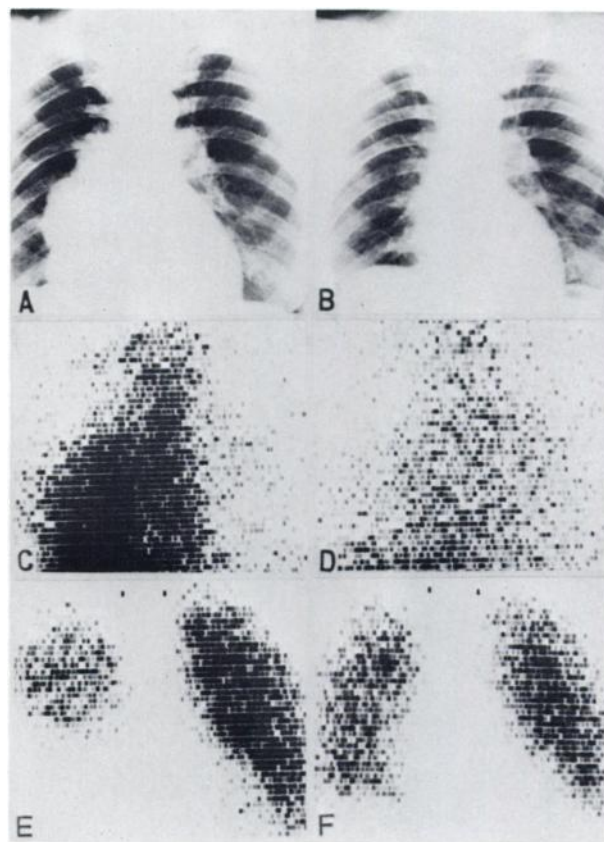


FIG. 5. (A) Chest x-ray shows large shadow along margin of heart in right lower lung field. (C) Scintigram with ^{67}Ga -citrate is strongly positive. (E) Pulmonary scanning with ^{131}I -MAA shows defect in middle and lower lung fields. (B,D,F) Abnormal shadow in chest x-ray and scintigram almost disappeared and returned to normal after treatment.

the margin of the heart in the right lower lung field (Fig. 5A). On lateral film and tomography a shadow of uneven contour was located inside the right lower lung field posteriorly. Bronchography did not visualize B₃. Scintigram was strongly positive in agreement with the above-mentioned tumor shadow (Fig. 5C). After hospitalization, 6,000 rads of ⁶⁰Co was given and the shadow in the chest x-ray and scintigram almost disappeared in both after treatment (Figs. 5B, 5D).

In pulmonary scanning with ¹³¹I-MAA the middle and lower lung fields showed a defect prior to treatment but returned to normal after treatment (Figs. 5E, 5F).

The histopathological diagnosis was squamous cell carcinoma.

Metastatic carcinoma in the lungs. The primary sites of pulmonary metastatic carcinoma in 18 cases were the uterus and breast in 4 cases each, kidney and parotid glands in 2 cases each, and the esophagus, stomach, chorioepithelioma, large intestine, urinary bladder, and submaxillary gland in 1 case each.

The rate of positive scans was 100% and except for one case of esophageal carcinoma, all of the 11 cases showed strongly positive scans. The scan of even a small tumor of 1.5 cm in diam was clearly positive.

Although it is difficult to obtain a positive scan in carcinoma of the abdominal viscera such as gastric carcinoma, colonic carcinoma, and uterine carcinoma, these cases with pulmonary metastases all had clearly positive scans. In gastric carcinoma for which a positive scan is difficult to obtain in general, abdominal scanning was performed in one case 48 hr after the intravenous injection of ⁶⁷Ga-citrate, and after gastrectomy, scanning was performed on the resected specimens. A slightly positive scan in agreement with the tumor in the resected stomach was obtained while demonstration of the tumor was obscure on abdominal scintigram (Fig. 6).

Case 5. A 52-year-old woman was examined at the urological department with left abdominal pain as the chief complaint and with the diagnosis of

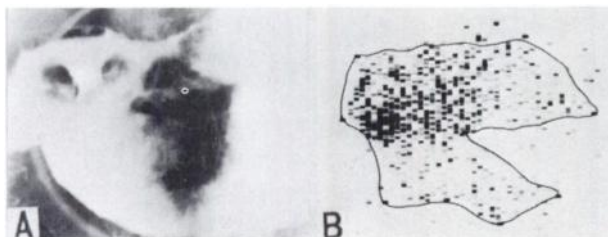


FIG. 6. (A) X-ray shows multiple defects in antrum region of stomach. (B) Scintigram is slightly positive in resected stomach.

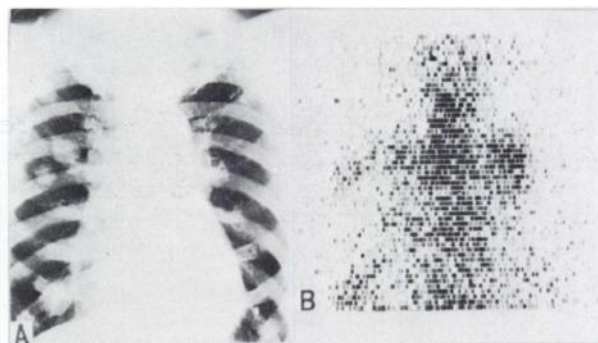


FIG. 7. (A) Chest x-ray shows round shadow in right middle and lower lung fields and left hilar region. (B) Scintigram is positive even with tumor shadow 1.5 cm in diam.

renal carcinoma as a result of detailed examination underwent removal of the left kidney. Chest x-ray taken 3 months later showed round shadows in the right middle and lower lung fields and the left middle field which were thought to be metastases (Fig. 7A). Scans were positive in agreement with the shadow of the chest x-ray film; even a tumor shadow 1.5 cm in diam was well demonstrated (7B).

The histopathological diagnosis was clear cell carcinoma.

Pneumonia. In the four cases of pneumonia, except for a slightly positive scan in one, scans were strongly positive. In the maximum stage of inflammation, they showed more uptake and were more strongly positive than in cases of pulmonary carcinoma. The uptake gradually fell with subsidence of inflammation and the positive scans disappeared with recovery.

Case 6. A 66-year-old woman came to the hospital with chief complaints of high fever and dyspnea. Chest x-ray film showed exudative lesion containing cavities in the left middle and lower lung fields and cavities in the right middle lung field (Fig. 8A). Sputum test showed staphylococcus aureus (++) . Scintigram was clearly positive in agreement with the shadows in the left middle and lower lung fields and in the right middle and lower lung fields (Fig. 8C). After admission, chemotherapy with aminobenzyl penicillin resulted in a favorable response. On chest x-ray, almost all of the shadows other than some in the left middle lung field disappeared (Fig. 8B). The positive scan before treatment almost disappeared after chemotherapy with ampicillin (Fig. 8D).

Purulent pulmonary infection. Two cases of purulent pulmonary infection had strongly positive scans similar to pneumonia.

Case 7. A 72-year-old man had chief complaints of voluminous, malodorous sputum, high fever, and dyspnea. Chest x-ray revealed dense and diffuse shadows in the left lower lung field (Fig. 9A). The

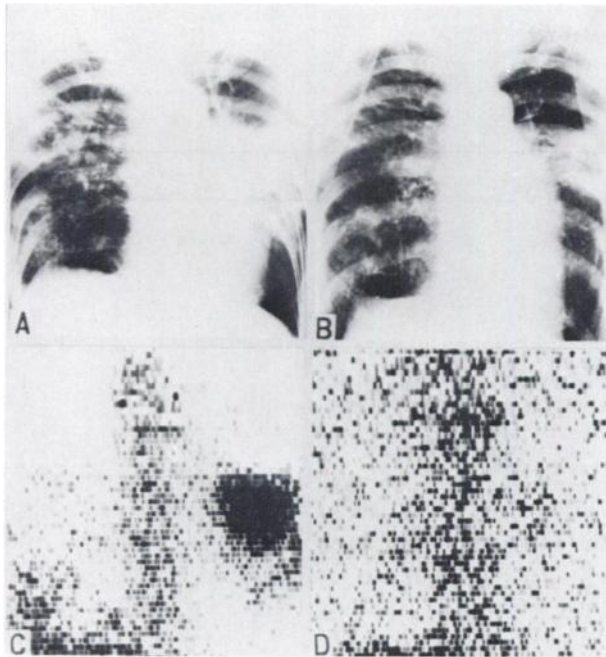


FIG. 8. (A) Chest x-ray shows exudative lesion containing cavities in left middle, left lower, and right middle lung field. (C) Scintigram is clearly positive. (B,D) After chemotherapy with ampicillin almost all of x-ray shadows or positive scan disappeared.

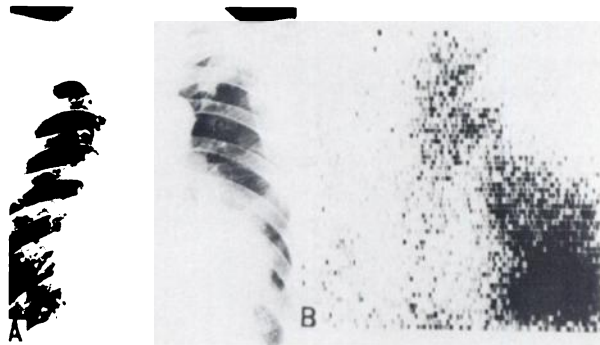


FIG. 9. (A) Chest x-ray shows dense and diffuse shadows in left lower lung. (B) Scintigram is clearly positive.

sputum showed numerous staphylococci albus and streptococci.

Scintigram was clearly positive in agreement with the shadow on the chest x-ray film (Fig. 9B).

Bronchiectasis. Since all of the three patients with bronchiectasis came to the hospital with chief complaints of cough, sputum, bloody phlegm, and fever, there was a strong suspicion that they had been complicated by infection.

Scintigram was slightly positive in one case and strongly positive in two.

Case 8. A 63-year-old woman came to the hospital with chief complaints of cough and bloody phlegm. Chest x-ray revealed dense shadows in the right upper lung field suggestive of pneumonia, and bronchography revealed a typical bronchiectatic pic-

ture in the branches of the right upper lobe (Fig. 10A). Scintigram was strongly positive, corresponding to the shadow in the right upper lung field (Fig. 10B).

Pulmonary tuberculosis. There were 12 cases of pulmonary tuberculosis which were roughly divided into exudative pulmonary tuberculosis, fibrotic pulmonary tuberculosis, and tuberculoma. All of the five patients with exudative pulmonary tuberculosis had positive scans which nearly paralleled the degree of inflammation. Six of the seven patients with sclerotic pulmonary tuberculosis had negative scans and only one had a slightly positive scan. Both of the two patients with tuberculoma had negative scans. In the patient with fibrotic pulmonary tuberculosis with a slightly positive scan, the possibility that exudative lesions were present cannot be ruled out though fibrotic lesions were evident on chest x-ray.

Case 9. A 48-year-old man came to the hospital with night sweats, low-grade fever, and sputum. Chest x-ray revealed exudative lesions in the left upper and middle lung fields (Fig. 11A); tomography revealed cavities; and the sputum smear showed tubercle bacilli. The scan was markedly positive in agreement with the aforementioned shadow (Fig. 11B).

Sarcoidosis. Three cases of sarcoidosis which we observed showed a typical swelling of the lymph nodes in the bilateral hilar regions and the ⁶⁷Ga-

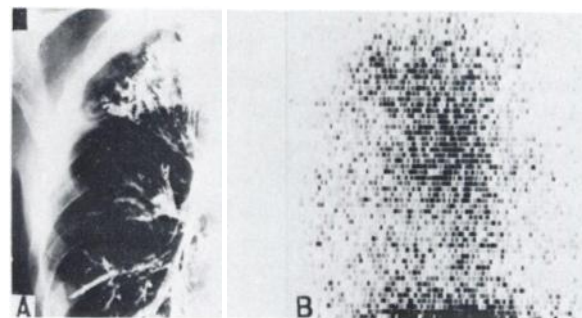


FIG. 10. (A) Bronchogram shows typical bronchiectatic picture in branches of the right upper lobe. (B) Scintigram is strongly positive.

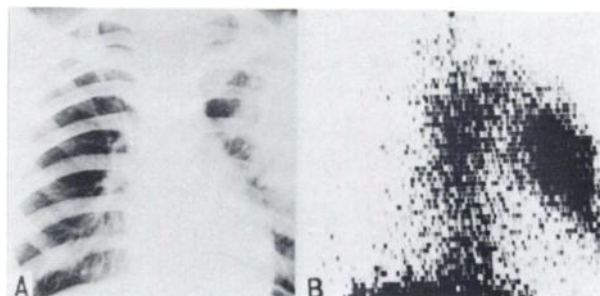


FIG. 11. (A) Chest x-ray shows exudative lesions in left upper and middle lung field. (B) Scintigram is strongly positive.

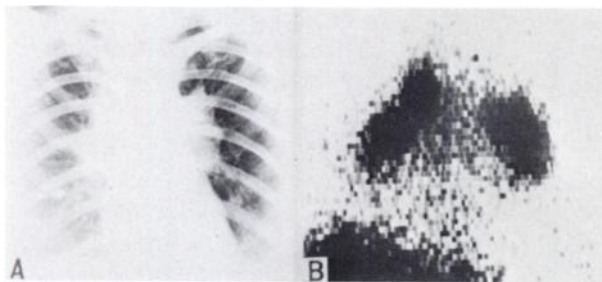


FIG. 12. (A) Chest x-ray shows typical shadows of sarcoidosis in hilar region. (B) Scintigram is strongly positive.

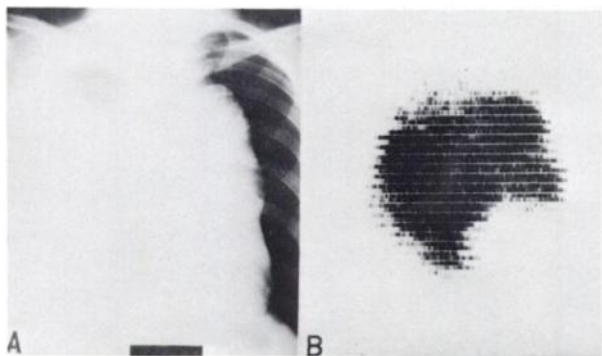


FIG. 13. (A) Chest x-ray shows large mediastinal shadow and right hydrothorax. (B) Scintigram is strongly positive.

citrate scan was strongly positive in the region of the lesion. The uptake rate seemed rather higher than that of cases of pulmonary carcinoma, showing a clearer scan.

Case 10. A 34-year-old woman came to the hospital because chest x-ray revealed large swelling of the lymph nodes in the hilar regions of both sides, leading to a suspicion of sarcoidosis (Fig. 12A). Kveim's reaction was positive and simultaneously uveitis was observed. The scan was strongly positive in agreement with the nodular shadow in the hilar region bilaterally (Fig. 12B).

Mediastinal tumor. In three cases of intramediastinal tumor, scans were strongly positive. Although it is difficult to know the accurate location, size, and extent of infiltration of intramediastinal tumor by roentgenologic studies on a ^{67}Ga -citrate scan, tumor alone appears positive and this would be the most suitable method for obtaining such information.

Case 11. A 16-year-old man was noted to have enlargement of the mediastinal shadow on chest x-ray during the group examination at school (Fig. 13A). Various roentgenologic tests, bronchoscopy, and mediastinoscopy revealed a large mediastinal tumor which was determined to be inoperative and was lymphosarcoma pathologically. The scan was strongly positive (Fig. 13B).

DISCUSSION

Of the 70 cases of primary pulmonary carcinoma, there was only one case which did not show a positive picture (Table 1). This high rate may be due to the fact that all cases in which radiotherapy and chemotherapy had been performed were excluded from our series. In the case of pulmonary carcinoma, in contrast to carcinoma of other organs, particularly carcinoma of intraperitoneal organs, there is interference only from uptake of ^{67}Ga -citrate by vertebrae, allowing a satisfactory detection of slightly positive scans in the lungs.

Since the positive rate of all cases of pulmonary carcinoma was high, the positive rate was further divided for examination. As Table 2 shows, the positive rate of squamous cell carcinoma and undifferentiated carcinoma seemed higher than that of adenocarcinoma with more uptake in the former than in the latter (Table 2). Since the number of our cases is still small it is difficult to compare them with the report of Langhammer, et al (2).

As to the limit of the size of solitary tumor of pulmonary carcinoma and metastatic pulmonary carcinoma, there was no small tumor in the initial stage. Most tumors were advanced to some extent in our series since most of the cases of primary pulmonary carcinoma examined at our hospital are referred for radiotherapy. Therefore, the smallest with a positive scan was 2.0 cm in diam.

With metastatic pulmonary carcinoma, a tumor 1.5 cm in diam was the smallest which could be demonstrated. Although theoretically tumors smaller than 1.5 cm can be demonstrated as long as the uptake is high, in our experience around 1 cm in diam is the smallest detectable.

One of the greatest advantages of pulmonary tumor scanning with ^{67}Ga -citrate is that it is possible to detect lymphatic metastasis in the mediastinum for which the established diagnosis by other roentgenologic studies is difficult, tumor of the site overlapping the heart shadow, and the presence or absence and the infiltrative extent of tumor in a large hydrothorax (Figs. 2-4, 13).

When pulmonary carcinoma is treated with radiation, the uptake of ^{67}Ga -citrate is generally lowered similarly to chemotherapy with anticarcinogen, and as in Fig. 5, the positive scan becomes fainter or disappears in accordance with the reduction or disappearance of the tumor observed on x-ray. Although there are differences according to the radiosensitivity of tumor, the picture becomes fainter by about 3,000 rads than that before treatment, and 5,000-6,000 rads results in a slightly positive scan or negative scan in most cases. It is possible to utilize this for radiotherapy, and when 5,000 rads still shows

a slightly positive scan, additional radiation should be performed. If the picture is negative after 4,000 rads, irradiation could be discontinued at 5,000 rads.

In spite of the variation of the primary site of tumor in metastatic pulmonary carcinoma including the esophagus, stomach, large intestine, parotid gland, uterus, urinary bladder, and breast and the high incidence of carcinoma of abdominal organs which are difficult to demonstrate by scanning with ⁶⁷Ga-citrate, pulmonary metastatic lesions were demonstrated in all cases. Based on this experience, we thought that the difficulty of demonstrating carcinoma of the abdominal organs, gastric carcinoma in particular, was due to the low uptake of ⁶⁷Ga-citrate by carcinomatous lesions and the interfering images of the peripheral organs such as the liver, kidneys, pancreas, intestines, and vertebrae which take up ⁶⁷Ga-citrate, as Edwards, et al (1,10) pointed out. In the case of Fig. 6 we scanned the resected gastric carcinoma and were able to demonstrate the tumor as a slightly positive scan which could not be demonstrated in vivo. The positive rate of carcinoma of digestive organs, gastric carcinoma in particular, with ⁶⁷Ga-citrate scans in Japan is markedly lower than that reported by Langhammer, et al (2).

Based on past experience it was postulated that the radionuclide taken up well by tumor would also be taken up by inflammation. We happened to scan a case of incurable bronchopneumonia of long duration with ⁶⁷Ga-citrate in order to rule out carcinoma and obtained a clearly positive scan (Fig. 8). The administration of ampicillin in this case resulted in the disappearance of the shadow on the chest film several months later together with the positive scan. The patient improved and was discharged. From the experience in this case, we performed a followup examination on bronchopneumonia and purulent pulmonary infection. Uptake of ⁶⁷Ga-citrate was higher than that of pulmonary carcinoma in the maximum stage of inflammation, showing a strongly positive scan. Accordingly, it was confirmed that the ⁶⁷Ga-citrate scan is not suitable for the differentiation of acute inflammation from carcinoma.

Furthermore, we examined the results with ⁶⁷Ga-citrate in cases of pulmonary tuberculosis, particularly tuberculoma, as representative of chronic inflammation. As stated previously, all of the four cases of exudative pulmonary tuberculosis were positive and showed a high uptake in a relatively acute stage with pronounced exudative changes similar to pneumonia (Fig. 11), and with lessening of the inflammation the positive scan became fainter or disappeared. Although the lesion of sclerotic pulmonary tuberculosis in which the pathological changes have

almost recovered showed a negative scan, partially active pathological lesions showed a slightly positive scan according to the extent of the activity. Conversely, this suggested that the present method would give information indicating the degree of activity of pulmonary tuberculosis.

Differentiating between tuberculoma and pulmonary carcinoma is frequently a clinical problem since in our experience of several cases we observed a positive scan in a pulmonary carcinoma 2.0 cm in diam and in a metastatic lesion 1.5 in diam (Fig. 7) whereas tuberculoma was negative, it would be possible to differentiate between tuberculoma and pulmonary carcinoma of some size. However, it should be taken into consideration that this is influenced by the extent of the activity of focus in the tuberculoma.

Although all three cases of bronchiectasis have positive scans, it was highly possible that they had been complicated by infection at the time of examination, and therefore the uptake of ⁶⁷Ga-citrate by inflammation was possible. It was thought that the positive or negative scan merely suggested the presence or absence of infection.

All three cases of sarcoidosis showed strongly positive scans in agreement with the shadow of the specific tumor in the hilar region observed on x-ray (Fig. 12). In view of other reports in Japan it was thought that when the scan was not strongly positive, sarcoidosis could be ruled out even when there was a suspicion of this diagnosis.

REFERENCES

1. EDWARDS CL, HAYES RL: Tumor scanning with ⁶⁷Ga-citrate. *J Nucl Med* 10: 103-105, 1969
2. LANGHAMMER H, GLAUBITT G, GREBE SF, et al: ⁶⁷Ga for tumor scanning. *J Nucl Med* 13: 25-30, 1972
3. HIGASI T, IKEMOTO S, NAKAYAMA Y, et al: Diagnosis of malignant tumor with ⁶⁷Ga-citrate. *Jap J Nucl Med* 6: 217-226, 1969
4. KINOSHITA F, MAEKAWA A, KUBO A, et al: Diagnosis of malignant tumors with ⁶⁷Ga-citrate. *Jap J Clin Radiol* 15: 583-597, 1970
5. HISADA T, HIRAKI T: Limit and significance of ⁶⁷Ga for diagnosis of malignant tumors. *Igaku no Ayumi* 72: 590-592, 1970
6. EDWARDS CL: Tumor scanning with Gallium-67. *Oak Ridge Associated Universities, 1970 Research Report ORAU-113*: 100-115, 1970
7. HIGASI T, NAKAYAMA Y, MURATA A, et al: Clinical evaluation of ⁶⁷Ga-citrate scanning. *J Nucl Med* 13: 196-201, 1972
8. HIGASI T, HISADA T, NAKAYAMA Y, et al: Diagnosis of malignant tumor with ⁶⁷Ga-citrate (2nd report). *Radioisotopes* 19: 17-24, 1970
9. MIYAMAE T, WATARI T, MOMOSE I, et al: Evaluation of tumor scanning with ⁶⁷Ga-citrate. *Jap J Clin Radiol* 15: 598-608, 1970
10. EDWARDS CL, HAYES RL: Scanning malignant neoplasms with gallium-67. *JAMA* 212: 1182-1190, 1970