

SUBCUTANEOUS EXTRAVASATION OF CSF DEMONSTRATION BY SCINTICISTERNOGRAPHY

D. Front and L. Penning

University Hospital, Groningen, The Netherlands

*The scinticisternographic findings in a case of traumatic subcutaneous extravasation of CSF into the facial region are described. This extravasation has to be differentiated from local accumulation of radioactivity inside the CSF spaces.*

Scinticisternography is considered to be a useful method for detecting CSF rhinorrhea (1,2). We report here an unusual case of leakage of CSF into the soft tissues of the face demonstrated by scinticisternography.

CASE REPORT

A 72-year-old man collided with a car while riding his scooter. On admission to hospital he showed signs of mild brain contusion, but there were no focal neurological signs. He was noted to have swelling of the right lower part of the face. X-ray pictures of the skull revealed fractures of the floor of the anterior fossa and of the zygomatic bone on the right side and a Le Fort Type II fracture without dislocation. Air was present in the frontal cranial region. In view of the fractures, IHSA cisternography was performed in a search for CSF leakage despite the fact that no overt rhinorrhea was found. The 4-hr pictures showed an abnormal accumulation of radioactivity below and to the right side of the base of the skull. In the 24-hr study (Fig. 1A,B) a large amount of abnormal radioactivity had accumulated in the region of the right cheek and zygomatic bone. At followup scinticisternography 14 days after the first examination, this abnormal accumulation of radioactivity had disappeared (Fig. 1C,D). After 40 days the patient was discharged from the hospital in good condition. He did not report for a followup check.

DISCUSSION

Scinticisternography in this case demonstrated leakage of CSF through the fractured floor of the

anterior fossa into the subcutaneous tissues of the right side of the face. The leakage manifested itself as a well-defined abnormal accumulation of radioactivity outside the CSF spaces. To the best of our knowledge no such case has been reported before.

Scinticisternography, which shows up normal and abnormal CSF flow (3-5), is probably the only method suitable for demonstrating subcutaneous extravasation of CSF. In this case it demonstrated the presence of a connection between the CSF spaces and extracranial structures although there were no overt clinical signs of leakage. Such a connection may be a source of ascending infection.

The abnormality had disappeared at followup scinticisternography after 2 weeks, probably due to local arachnoidal adhesions obstructing flow of CSF out of the subarachnoid spaces. This spontaneous arrest of CSF leakage suggests the desirability of early investigation when an external opening of the CSF spaces is being sought.

Such an abnormal collection of radioactivity outside the skull has to be differentiated from a local accumulation of radioactivity inside the CSF spaces such as appears in cases of porencephalic cysts (6) and leptomenigeal cysts (7).

ACKNOWLEDGMENT

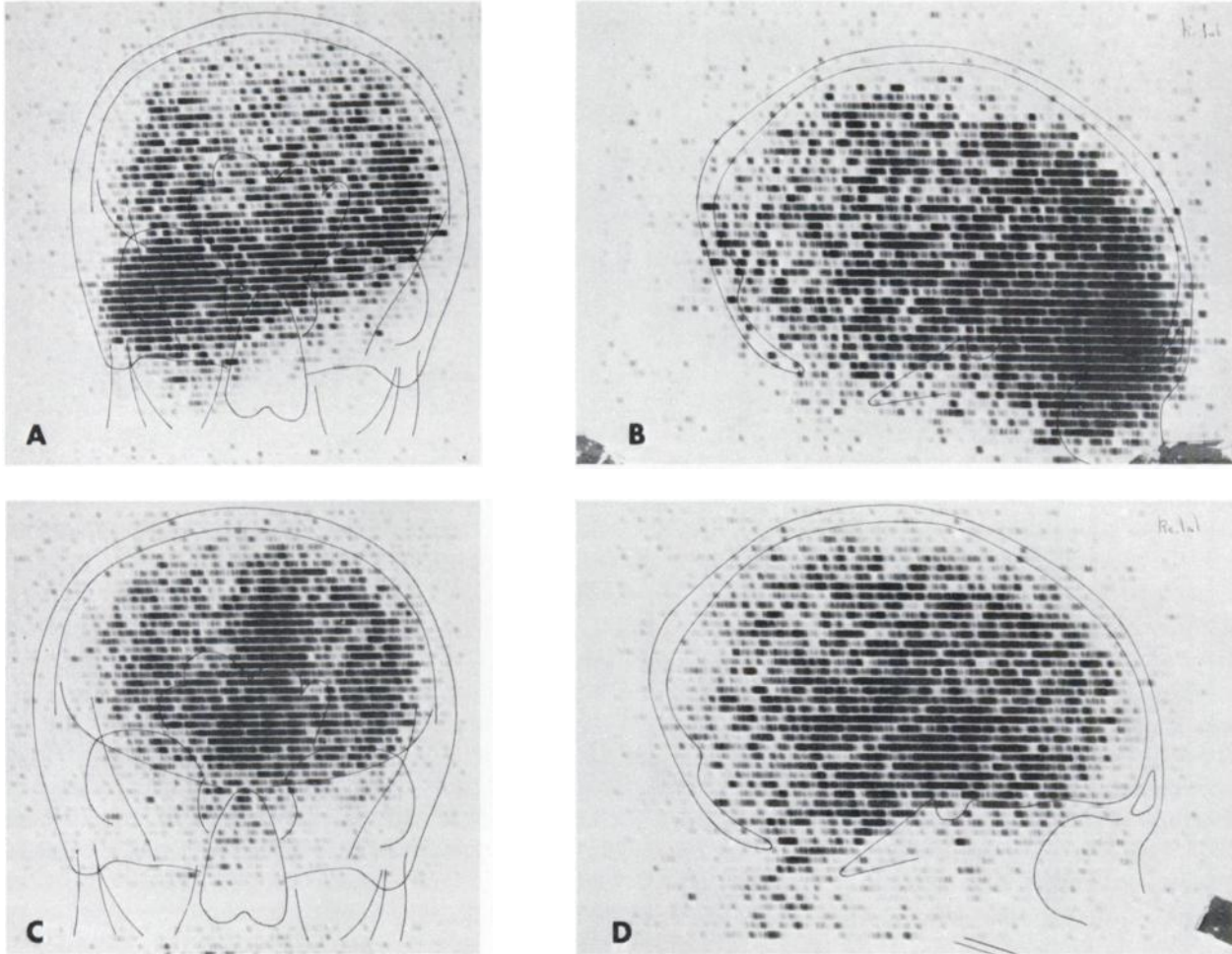
The investigation was performed in the Central Isotope Laboratory of the University Hospital of Groningen, M. G. Woldring, under the supervision of Dr. H. Beekhuis.

REFERENCES

1. ASHBURN WL, HARBERT JC, BRINER WH, et al: Cerebrospinal fluid rhinorrhea studied with the gamma scintillation camera. *J Nucl Med* 9: 523-529, 1968

Received July 9, 1973; original accepted Sept. 5, 1973.

For reprints contact: L. Penning, Dept. of Neuroradiology, University Hospital, Groningen, The Netherlands.



**FIG. 1.** (A and B): IHS cisternography in anterior and lateral view 24 hr after lumbar intrathecal injection. A large abnormal accumulation of tracer is seen in right zygomatico-orbital region.

Anatomical landmarks show that abnormal accumulation is outside normal CSF spaces. (C and D): Anterior and lateral 24-hr views 2 weeks later. Abnormal collection has disappeared.

2. DI CHIRO G, OMMAYA AK, ASHBURN WL, et al: Isotope cisternography in the diagnosis and follow up of cerebrospinal fluid rhinorrhea. *J Neurosurg* 28: 522-529, 1968

3. DI CHIRO G, REAMES PM, MATHEWS WB: RISA ventriculography and RISA cisternography. *Neurology* 14: 185-195, 1964

4. DI CHIRO G: Movement of cerebrospinal fluid in human beings. *Nature* 204: 290-291, 1964

5. FRONT D: Scintiscisternography and scintiventriculography. Thesis, University of Groningen, 1971

6. FRONT D, BEKS JWF, PENNING L: Porencephaly diagnosed by isotope cisternography. *J Neurol Neurosurg Psychiatr* 35: 669-675, 1972

7. FRONT D, MINDERHOUD JM, BEKS JWF, et al: Leptomeningeal cysts diagnosed by isotope cisternography. *J Neurol Neurosurg Psychiatry*: to be published