

IMPROVING THE ^{99m}Tc -PHOSPHATE BONE SCAN

The introduction of ^{99m}Tc -labeled phosphate compounds in bone scanning is a real achievement toward the search for an ideal radiopharmaceutical. However, certain difficulties are occasionally met. The presence of free pertechnetate ion is the main problem. It is reflected on the scan picture as increased uptake in the salivary glands, thyroid, and gastric mucosa (Fig. 1). This may result either from incomplete reduction of the pertechnetate or having been reduced, it is reoxidized before combining with the phosphate polymer. This may be the result of a defect in the various commercial kits or it may be related to the time elapsed after preparation of the vial and withdrawal of multiple doses. To avoid this problem either all of the agent must be used soon

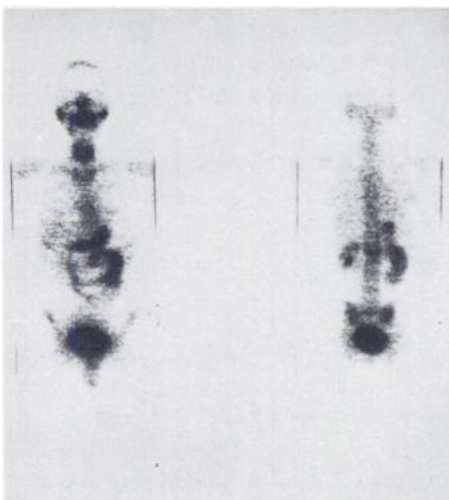


FIG. 1. Anterior and posterior views ^{99m}Tc -polyphosphate total-body bone scan done 3 hr after injection of 10 mCi intravenously with no previous preparation. Note increased radioactivity in regions of salivary glands, thyroid, stomach, and small intestines.

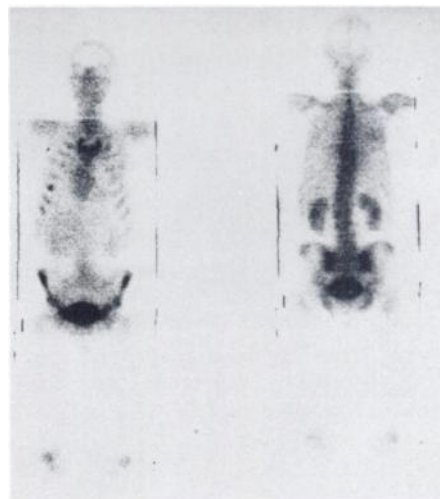


FIG. 2. Anterior and posterior views ^{99m}Tc polyphosphate total-body bone scan done 3 hr after injection of 10 mCi intravenously. Potassium perchlorate (400 mg) was given orally 15 min before.

after its preparation or the vials must be purged with N_2 gas without adding air to the vial when withdrawing individual doses. In some institutions where the kits are received previously labeled by a central distributing radiopharmacy, this time elapsed between labeling and injection may be as long as 1–2 hr, whereby an appreciable percentage of free pertechnetate ion is usually found. The blocking of the salivary glands, thyroid, and the stomach with either 400 mg potassium perchlorate orally 15 min before or 0.5 gm sodium iodide intravenously 5 min before injecting the labeled kit has been helpful in improving the quality of the bone scan (Fig. 2).

HUSSEIN M. ABDEL-DAYEM
 GEORGE J. ALKER, JR.
 State University of New York at Buffalo
 Edward J. Meyer Memorial Hospital
 Buffalo, New York

PROLONGED RETENTION OF RADIOACTIVITY IN ABNORMAL LUNG SCANS

In a recent article Busse and coworkers reported on "Prolonged retention of radioactivity following perfusion lung scan in asthmatic patients" (1). I read their communication with great interest as we have been involved in studying aggregate clearance from the lungs for nearly 5 years. I was pleased to see that their findings were in good agreement with

our previously published results (2–4) as well as with those observed by Spencer (5). Although our work did not deal specifically with asthmatics, it did cover numerous pathologic pulmonary conditions and the authors do comment on the nonspecificity of the retention phenomenon. I believe that a comprehensive article of this nature should have in-