

# RADIONUCLIDE CEREBRAL ANGIOGRAPHY IN DIAGNOSIS AND EVALUATION OF CAROTID-CAVERNOUS FISTULA

Philip Matin, David A. Goodwin, and Som N. Nayyar

*Veterans Administration Hospital and  
Stanford University School of Medicine, Palo Alto, California*

***The use of radionuclides and the gamma camera for the visualization of cerebral blood flow is useful in the diagnosis and followup of patients with carotid-cavernous fistula. The procedure involves an intravenous injection of a small bolus of  $^{99m}\text{Tc}$ -pertechnetate followed by rapid-sequence images of the flow of the label through the cerebral vessels. This technique is simple, safe, and may be repeated at frequent intervals.***

The standard method of diagnosing and evaluating carotid-cavernous fistulas has been x-ray cerebral angiography using contrast media (1-9). However, improvements in nuclear medicine techniques in recent years have provided the ability to perform radionuclide cerebral angiography with a high degree of accuracy (10-15). It is a benign procedure that does not require catheterization or radiologic contrast media. The technique has been used with great success in detecting arteriovenous malformations. It is ideal in cases which require frequent or periodic analysis of cerebral blood flow before and after treatment and has been used as a screening test prior to x-ray contrast angiography.

This paper describes the use of radionuclide cerebral angiography in the diagnosis and treatment evaluation of three patients with carotid-cavernous fistulas.

## METHOD

Radionuclide cerebral angiography was performed preoperatively and postoperatively in three adult male patients with signs suggestive of carotid-cavernous fistula. The procedure was performed with a Searle Radiographics Pho/Gamma III scintillation camera. The detector was positioned over the anterior surface of the patient's head with the upper neck included in the field of view. Fifteen mCi of  $^{99m}\text{Tc}$ -pertechnetate were administered rapidly in an

antecubital vein in a volume of less than 2 ml. The flow of injected activity was observed on a persistence oscilloscope while permanent images were recorded. Images were obtained on Polaroid film and on 35-mm film at 2-sec intervals after the arrival of the bolus at the carotid arteries. The Polaroid film was exposed manually whereas the 35-mm exposures were obtained with a photographic camera utilizing a motor-operated shutter and advance mechanism. Images were obtained for at least 20 sec after injection.

The patients were also studied preoperatively with x-ray contrast angiography.

## CASE REPORTS

**Case 1.** Two weeks after returning from Viet Nam, a 22-year-old data processor was a passenger in a car that was involved in a major accident. Immediately after the accident, he was comatose with right-sided weakness. There were multiple lacerations of face and neck with a compound fracture of his mandible. X-ray films of the skull, cervical spine, and chest were normal. Mandible x-rays showed bilateral fractures. Bifrontal burr holes revealed a swollen brain with very thin subdural blood collections. Tracheostomy was done. Within 24 hr he began to respond to simple commands.

Two days later he was lethargic. He had a short attention span and was responsive to some auditory stimuli but followed commands poorly. Cerebrospinal fluid drained from his left ear; retrotympenic blood was noted on the right. Gaze was dysconjugate with no eye movement to command. Left corneal response was decreased. There was left periorbital edema. Purposeful movement was present in all four extremities with a right Chaddock's sign.

Received May 29, 1974; original accepted June 27, 1974.

For reprints contact: Philip Matin, Nuclear Medicine Dept., Roseville Community Hospital, Roseville, Calif. 95678.

Five days after the accident, bilateral chemosis with a bruit over a pulsating left eye was evident. The left pupil remained larger than the right. There were subhyaloid and subretinal hemorrhages in both eyes. A loud systolic bruit was heard over both orbits, which became inaudible with occlusion of the left internal carotid artery. A radionuclide cerebral angiogram was performed which revealed a left carotid-cavernous sinus fistula. This was confirmed by retrograde femoral catheterization of both carotid arteries. He became disoriented, confused, and hallucinatory with a flattened effect and an expressionless voice. He had surgery 6 days after the accident.

At surgery a No. 3 F. balloon catheter was placed within the cavernous carotid under radiographic control. The balloon was inflated with 0.15 ml of Renographin which permitted its visualization. The proximal catheter tubing was secured into the common carotid wall through which it was introduced. Once the balloon was inflated, there was immediate cessation of the bruit. The left external, internal, and common carotid arteries were doubly ligated. In the immediate postoperative period turgidity and proptosis of both eyes decreased in association with improvement in the patient's level of consciousness. Over the subsequent weeks, his cerebation and sensory and motor function returned to normal. Bilateral third nerve function returned although lateral gaze paresis remained in both eyes. Restoration of visual acuity remained incomplete, probably secondary to vitreous hemorrhages.

**Case 2.** The second patient was a 77-year-old man with advanced generalized arteriosclerosis who was admitted for treatment of congestive heart failure and hypertension. His blood pressure on admission was 180/115. The left carotid artery had a slightly decreased pulsation but no bruits were heard. He was somewhat obtunded but followed simple commands.

The patient was being treated with diuretics, digitalization, and antihypertensive agents with some success when he suddenly developed progressive exophthalmus of the left eye. There was a systolic bruit over the eye but no evidence of pulsation. His degree of obtundation became somewhat greater than that prior to the development of the proptosis. No distinct lateralizing neurologic findings were present.

Radionuclide cerebral angiography showed a carotid-cavernous fistula. Radiographic angiography showed the cause to be a large intercavernous aneurysm of the left internal artery, which had ruptured.


The patient underwent surgery where the left common, internal, and external carotid arteries were ligated and small pieces of muscle embolized through the common carotid artery. The patient subsequently developed a right hemiparesis and aphasia. He became unconscious and died 4 days later.

**Case 3.** A 27-year-old man was involved in an automobile accident resulting in loss of consciousness for 30 min and extensive injuries to the face. He noticed "swishing noise" in the head, diminished vision in the left eye, and diplopia. He gradually developed proptosis of the left eye, bilateral chemosis, and an atrophic left optic disk. A loud, harsh, systolic murmur was present over the entire head and was loudest over the lateral canthus of the left eye. It was readily abolished by compression of the left carotid artery.

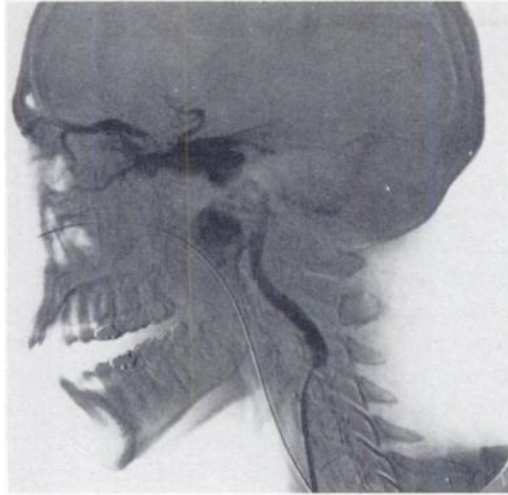Radionuclide angiography showed increased flow in the region of the left cavernous sinus which was ascribed to a carotid-cavernous fistula. This diagnosis was confirmed by transfemoral cerebral arteriography. The patient underwent surgery with arteriographic monitoring until the fistula was obliterated by ligation of the left common, external, and internal carotid arteries in the neck and supraclinoid clipping of the left ophthalmic and internal carotid arteries. Postoperative radionuclide angiography no longer showed increased blood flow in the left parasellar region noted in the preoperative study. Rather, it showed a general decrease in flow to the left cerebral hemisphere. The patient made a complete recovery except for marked diminution of vision in the left eye.

## RESULTS

The first patient was studied shortly after the development of proptosis. The radionuclide cerebral angiogram (Fig. 1) showed greater blood flow through the left carotid artery than the right. This is best seen in the early frame obtained 6-8 sec after injection. It also showed a marked concentration of radioactivity in the vicinity of the left cavernous sinus with extension of activity into the right



**FIG. 1.** Preoperative radionuclide cerebral angiogram on Patient No. 1 indicating left carotid-cavernous sinus fistula. Note persistent increased activity at base of brain in region of cavernous sinus and decreased activity in major cerebral vessels.



**FIG. 2.** Left lateral view, subtraction technique, of x-ray contrast carotid arteriogram. Study shows rupture of internal carotid artery into cavernous sinus.

cavernous sinus. Although activity in the cerebral hemispheres was diminished, it was symmetric. The pattern persisted throughout the study. Arteriograms through retrograde femoral catheterization of both carotid arteries confirmed the left carotid-cavernous fistula (Fig. 2).

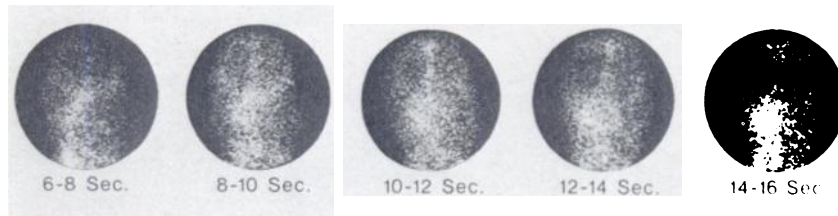
Following the surgical procedure in which the left carotid artery was occluded with the balloon of a Fogarty catheter, the radionuclide angiogram showed absence of blood flow through the left carotid artery (Fig. 3). The cavernous sinus activity was no longer

present and blood flow to both cerebral hemispheres was symmetric. The patient's symptoms began to decrease at this time. He was restudied with radionuclide angiography 6 weeks later (Fig. 4). At this time the study showed continued absence of flow through the left carotid artery although there was some reflux filling of the distal left internal carotid. The middle and anterior cerebral arteries were well seen in the 6-8 sec frame and appeared symmetric. Flow to the cerebral hemispheres was also symmetric in this successful case.

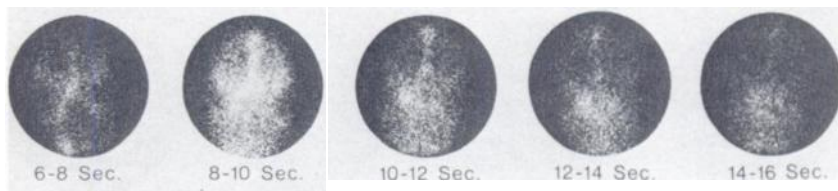
The second patient was also studied shortly after the development of proptosis. The radionuclide cerebral angiogram (Fig. 5) showed greater blood flow through the left carotid artery and marked concentration of activity in the vicinity of the cavernous sinus. In this case, the activity in the right carotid was not as prominent and activity persisted in the cavernous sinus region for a longer time. As in the first case, the diagnosis of left carotid cavernous fistula was suggested by cerebral radionuclide angiography and confirmed by x-ray contrast angiography. In this patient, however, bilateral carotid catheterization through the right femoral artery revealed aneurysms of both internal carotid arteries. An aneurysm of the left carotid had ruptured into the cavernous sinus (Fig. 6).

The patient was restudied by cerebral radionuclide angiography following his surgery. The study showed the expected absence of blood flow through the left carotid artery (Fig. 7). However, there was now a

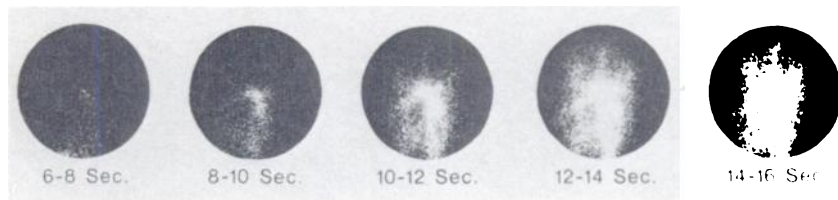**FIG. 3.** Postoperative radionuclide cerebral angiogram on Patient No. 1 after left carotid artery had been occluded. Note absence of flow through left carotid artery but symmetric flow to both cerebral hemispheres. Increased activity at base of brain is no longer present.

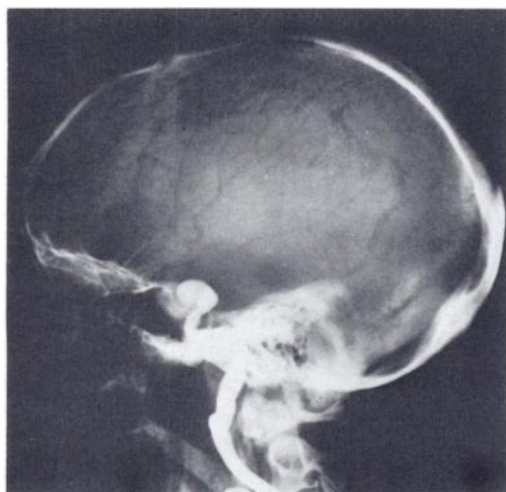

**FIG. 4.** Followup radionuclide cerebral angiogram on Patient No. 1 performed 6 weeks after occlusion of left carotid artery. Note symmetric blood flow to both cerebral hemispheres although blood flow through left carotid artery is absent.



**FIG. 5.** Preoperative radionuclide cerebral angiogram in Patient No. 2. Study shows decreased blood flow through major cerebral arteries with increased blood flow near base of brain indicating left carotid-cavernous sinus fistula.





**FIG. 6.** Left lateral view of x-ray contrast arteriogram on Patient No. 2 showing aneurysm of internal carotid artery with rupture into cavernous sinus. Internal carotid artery is quite tortuous.

very marked decrease in blood flow to the left cerebral hemisphere.

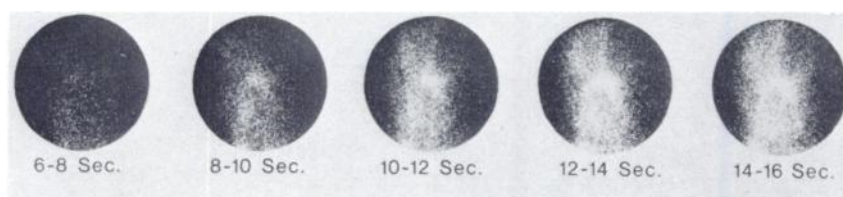The third case showed a similar preoperative radionuclide angiogram (Fig. 8). There was increased blood flow through the involved left carotid artery and a pattern of increased activity in the low frontal region. The x-ray study indicated a traumatic carotid-cavernous fistula. The postoperative radionuclide study (Fig. 9) showed absence of blood flow through the ligated left carotid artery. Although there was delayed arterial flow in the left

cerebral hemisphere, the patient had no neurologic symptoms.

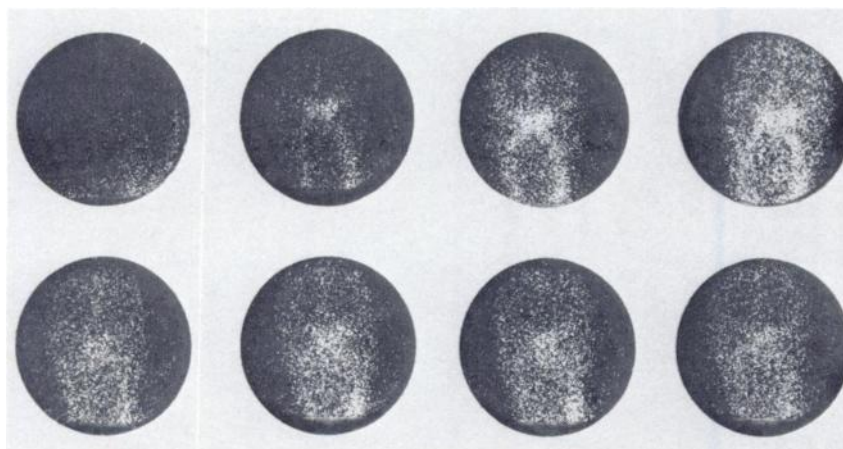
**COMMENT**

The use of radionuclides and nuclear medicine imaging devices for the visualization of cerebral blood flow has become widespread in clinical practice in the past few years. The procedure involves an intravenous injection of a small bolus of <sup>99m</sup>Tc-per-technetate and is usually performed at the time of injection for routine brain scanning. The carotid arteries and the larger vessels arising from the circle of Willis are usually well visualized in these studies. Although it is not possible to obtain the resolution found in direct x-ray contrast arteriography, radionuclide arteriography offers many advantages. The study is extremely easy to perform, it presents negligible risk to the patient, and it may be repeated at frequent intervals. These factors make the radionuclide angiogram extremely useful in cases where repeated blood flow studies are desired. An example of the type of case for which repeated blood flow studies are required is the carotid-cavernous sinus fistula.

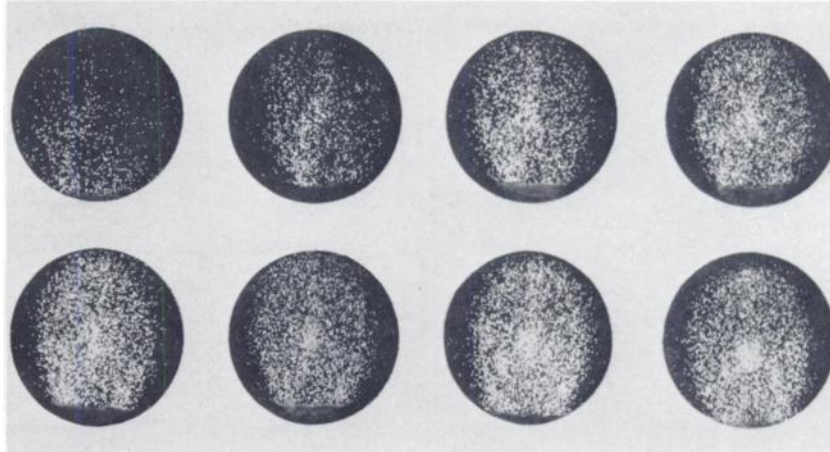
The diagnosis and treatment of carotid-basilar venous plexus fistulas has been the subject of many studies during the past few years. This type of arteriovenous fistula can arise spontaneously or from trauma and is often a diagnostic dilemma. We have presented three cases in which cerebral radionuclide angiography correctly diagnosed a carotid-cavernous fistula. Two cases arose from trauma and were suc-



**FIG. 7.** Postoperative radionuclide cerebral angiogram on Patient No. 2, indicating absence of flow through left carotid artery secondary to surgical occlusion. Note marked decrease in blood flow to left cerebral hemisphere. This is most evident in frames 10-12, 12-14, and 14-16 sec.



**FIG. 8.** Preoperative radionuclide cerebral angiogram on Patient No. 3 showing increased blood flow through left carotid artery as compared with right, with increased blood flow in region of carotid-cavernous fistula.



**FIG. 9.** Postoperative radionuclide cerebral angiogram on Patient No. 3. Note absent flow through ligated left carotid artery. Third and fourth frames show decreased blood flow to left cerebral hemisphere. However, by capillary and venous phases, there is symmetric activity in both cerebral hemispheres.

cessfully treated. The second case was of spontaneous origin and unfortunately ended in death after an unsuccessful attempt to repair the lesion. In all cases the patients were also studied by x-ray contrast angiography of the carotid arteries through femoral artery catheterization prior to surgery. The advanced arteriosclerosis of the older patient was considered prior to catheterization and it was performed only after direct carotid injection failed. This consideration did not apply after surgery since the followup studies were performed by cerebral radionuclide angiography, which only requires venipuncture.

The followup studies were performed shortly after surgery in all cases to evaluate the results of the procedure. In the two trauma cases there was no longer evidence of blood flow into the cavernous sinus since the left carotid artery had been successfully occluded. In the third patient the abnormal flow was no longer seen but, in addition, the study also showed a marked decrease in blood flow to the left cerebral hemisphere. This explained the patient's suddenly increasing symptoms and death due to left cerebral infarction.

#### REFERENCES

1. PROLO DJ, HANBERY JW: Intraluminal occlusion of a carotid-cavernous sinus fistula with a balloon catheter. *J Neurosurg* 35: 237-242, 1971
2. STERN WE, BROWN WJ, ALKSNE JF: The surgical challenge of carotid-cavernous fistula: the critical role of intracranial circulatory dynamics. *J Neurosurg* 27: 298-308, 1967
3. DAVIE JC, RICHARDSON R: Distal internal carotid thromboembolectomy using a Fogarty catheter in total occlusion. *J Neurosurg* 27: 171-177, 1967
4. EL GINDI S, ANDREW J: Successful closure of carotid-cavernous fistula by the use of acrylic: case report. *J Neurosurg* 27: 153-156, 1967
5. ISHIMORI S, HATTORI M, SHIBATA Y, et al: Treatment of carotid-cavernous fistula by gelfoam embolization. *J Neurosurg* 27: 315-319, 1967
6. KESSLER LA, WHOLEY MH: Internal carotid occlusion for treatment of intracranial aneurysms: A new percutaneous technique. *Radiology* 95: 581-583, 1970
7. GRAF CJ: Carotid-basilar venous plexus fistulas. *J Neurosurg* 33: 191-197, 1970
8. PARSON TC, GULLER EJ, WOLFF HG, et al: Cerebral angiography in carotid-cavernous communications. *Neurology* 4: 65-68, 1954
9. BENNETT DR, VAN DYK HJL, DAVIS DO: Carotid cavernous sinus fistula closure following angiography. *JAMA* 224: 1637-1639, 1973
10. STRAUSS HW, JAMES AE, HURLEY PJ, et al: Nuclear cerebral angiography. *Arch Intern Med* 131: 211-216, 1973
11. MAYNARD CD, WITCOFSKI RL, JANEWAY R, et al: "Radioisotope arteriography" as an adjunct to the brain scan. *Radiology* 92: 908-912, 1969
12. BURKE G, HALKO A: Cerebral blood flow studies with sodium pertechnetate Tc99m and the scintillation camera. *JAMA* 204: 319-324, 1968
13. CURL FD, HARBERT JC, LUESSENHOP AD, et al: Radionuclide cerebral angiography in a case of bilateral carotid-cavernous fistula. *Radiology* 102: 391-392, 1972
14. MOODY D, MATIN P, GOODWIN DA: An improved method for visualizing carotid blood flow in the neck. *J Nucl Med* 12: 520-522, 1971
15. LUBIN E, DUJOVNY M, ISRAELI J, et al:  $^{113m}\text{In}$  scanning for visualizing and evaluating giant intracranial aneurysm postoperatively. *J Nucl Med* 12: 88-89, 1971