

2. BRAUNSTEIN P, KOREIN J, KRICHEFF I, et al: A simple bedside evaluation of cerebral blood flow in the study of cerebral death: A prospective study on 34 deeply comatose patients. *Am J Roentgenol Radium Ther Nucl Med*

118: 757-767, 1973

3. NORDLANDER S, WIKLUND PE, ÅSARD PE: Cerebral angioscintigraphy in brain death and in coma due to drug intoxication. *J Nucl Med* 14: 856-857, 1973

RADIONUCLIDE VENOGRAPHY

It always has been my feeling that radionuclide venography is a highly recommended procedure for a patient with clinical evidence of pulmonary embolism because of its simplicity and usefulness. It was delightful, therefore, to read the article by Henkin, et al (1). In our series of radionuclide venographies, we have some findings that are not described in their rather extensive studies. An example is the visualization of the popliteal veins for more than 30 min after the injection of ^{99m}Tc -HAM. At an early stage of the study when radionuclide activity was confirmed in the femoral vein, tourniquets were removed from both ankles. The early dynamic scintiphotogram showed a slight decrease in the blood flow through the right iliac vein (Fig. 1A). As the camera field was moved over the thigh, the femoral and saphenous veins appeared to be normal in both sides except for a delayed flow (Fig. 1B).

However, images of the popliteal veins obtained at a later stage were grossly abnormal showing retention of the radionuclide and development of collateral flow (arrows, Fig. 1C). In this particular case, markedly delayed clearance or hangup of the radionuclide in the popliteal veins was visualized up to 30 min after the injection.

Rosenthal has described visualization of trapped ^{99m}Tc -human albumin macroaggregates at the region of thrombi, 7 min after the injection (2). It is apparent that a search for areas of delayed radionuclide clearance in the lower leg is a recommended practice, particularly when radionuclide venography over the pelvis and thigh is negative.

In view of the significant increase in field size, I prefer to use a 140-keV diverging-hole collimator despite considerable loss in sensitivity. With a dose of 1 mCi or more of ^{99m}Tc -HAM in each leg, the

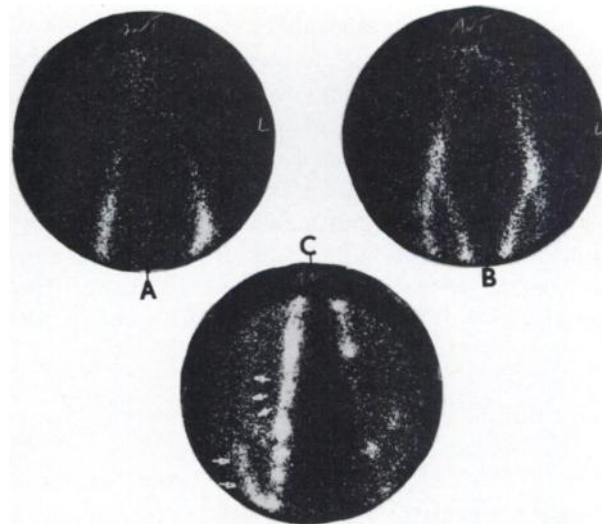


FIG. 1. Radionuclide venogram obtained from Pho/Gamma HP camera with 140-keV diverging-hole collimator. Two millicuries of ^{99m}Tc -HAM were injected into dorsal vein of each foot. (A) Scintiphotogram of both iliac veins recorded 20 sec after injection. (B) Scintiphotogram of femoral and saphenous veins in both legs recorded about 1 min after injection. (C) Images of right and left popliteal veins recorded 25 min after injection.

lower sensitivity of the diverging-hole collimator has never been a problem in our venography series.

U. YUN RYO

Michael Reese Hospital and Medical Center
Chicago, Illinois

REFERENCES

1. HENKIN RE, YAO JST, QUINN JL, et al: Radionuclide venography (RNV) in lower extremity venous disease. *J Nucl Med* 15: 171-175, 1974
2. ROSENTHALL L: Combined inferior vena cavography, iliac venography and lung imaging with ^{99m}Tc -albumin macroaggregates. *Radiology* 98: 623-626, 1971

THE AUTHORS' REPLY

We are encouraged to see that other institutions are adopting what we have found to be an excellent technique for the evaluation of deep venous thrombosis (DVT) of the lower extremities.

Different institutions may employ slightly differ-

ent methodology in performing radionuclide venograms. It would appear that the method employed by Dr. Ryo resembles that of McDonald (1) more than the method we described (2).

We have, however, made observations similar to

those of Dr. Ryo. Indeed, one of the criteria we described for identifying thrombi was persistence of activity ("hot spots") for 5 min or longer.

The popliteal region is a difficult region in which to identify obstruction with certainty since when the patient's legs are extended, tension may be placed on the popliteal veins which impedes flow through this region. Our criteria for popliteal obstruction include visualization of collaterals on the dynamic study. If the activity appears to stop at the popliteal fossa and no collaterals are seen, then we repeat the injection with the patient's leg flexed.

Using the double tourniquet technique described, we visualize the superficial circulation so infrequently that we now consider its appearance abnormal.

With regard to the choice of collimators for venography, each institution must decide based on its own preferences what collimation suits its needs. Our experience with the multiple-injection technique and

various collimators (including the 140-keV diverging) has left us with the opinion that the limiting factor in the image quality of venograms is counting statistics. We have therefore chosen the high-sensitivity (140 keV) collimator. Although it takes somewhat longer to perform the study we are able to keep our doses low and obtain excellent images.

ROBERT E. HENKIN
JAMES S. T. YAO
JAMES L. QUINN III
JOHN J. BERGEN
Northwestern Memorial Hospital
Chicago, Illinois

REFERENCES

1. McDONALD GB, HAMILTON GW, BARNES RW, et al: Radionuclide venography. *J Nucl Med* 14: 528-530, 1973
2. HENKIN RE, YAO JST, QUINN JL, et al: Radionuclide venography. *J Nucl Med* 15: 171-175, 1974

¹³¹I-IHSA VERSUS ¹⁶⁹Yb-DTPA FOR "CISTERNOGRAPHY"

For radioactive tracer studies of the cerebrospinal fluid compartment to have any meaning, a clear understanding is required of just what is being measured by the tracer used.

In general, such studies are aimed at providing information on either the anatomy or the kinetics of the CSF compartment. The first category comprises qualitative imaging studies, i.e., CSF compartment scans, whereas the second category comprises quantitative nonimaging studies, i.e., CSF compartment kinetics. Although the two types of study may both be performed with the scintillation camera (functioning, respectively, in analog and digital capacities), CSF compartment kinetics may be investigated by direct sampling of the CSF (1) or vascular (2,3) compartments.

CSF compartment scans require a radiopharmaceutical which will be distributed throughout the CSF compartment. Almost any radiopharmaceutical that is moderately well retained in the CSF compartment will do (provided it fulfills the usual criteria for safety and has a radioactive label with reasonably suitable physical characteristics) since distribution of tracer throughout the CSF compartment is accomplished by what has been termed "bulk flow" of CSF.

In contrast, CSF compartment kinetics depend on diffusion and active transport as well as on bulk flow and hence depend on the physical and chemical properties of the constituent molecules of the CSF.

Clearly, there is no single appropriate tracer for investigating the kinetics of the CSF since the CSF consists of a heterogeneous mixture of solute molecules (electrolytes, proteins, sugars, etc.) dissolved in a solvent (water). Each of the components has its own characteristic molecular properties and it follows that each of the components has its own characteristic kinetics. It is a fundamental axiom of tracer kinetics that the tracer used should accurately duplicate the behavior of the molecule under study in the physical or biologic system concerned. An appropriate tracer for CSF sodium is therefore ²⁴Na, for CSF albumin, ¹³¹I-IHSA, for CSF glucose, ¹⁴C-glucose, etc. Radiopharmaceuticals such as ¹⁶⁹Yb-DTPA and ¹¹¹In-DTPA, although satisfactory radiopharmaceuticals for CSF compartment scans, cannot be regarded as satisfactory tracers for CSF compartment kinetics unless they can be shown to duplicate accurately the behavior of one of the constituents of the CSF.

Comparative studies of inulin and albumin (4,5) suggest that clearance of a tracer from the CSF compartment varies with the size of the tracer molecule. Ytterbium-169-DTPA has a molecular weight of ~600 and albumin a molecular weight of ~69,000 and it is inconceivable that the kinetics of the two molecules are the same. Hosain, et al (1) measured clearance of ¹⁶⁹Yb-DTPA and ¹³¹I-IHSA from the cisterna magna of dogs over 5 hr after cisternal injection of a mixture of the two radiopharmaceuticals.