

2. BRAUNSTEIN P, KOREIN J, KRICHEFF I, et al: A simple bedside evaluation of cerebral blood flow in the study of cerebral death: A prospective study on 34 deeply comatose patients. *Am J Roentgenol Radium Ther Nucl Med*

118: 757-767, 1973

3. NORDLANDER S, WIKLUND PE, ÅSARD PE: Cerebral angioscintigraphy in brain death and in coma due to drug intoxication. *J Nucl Med* 14: 856-857, 1973

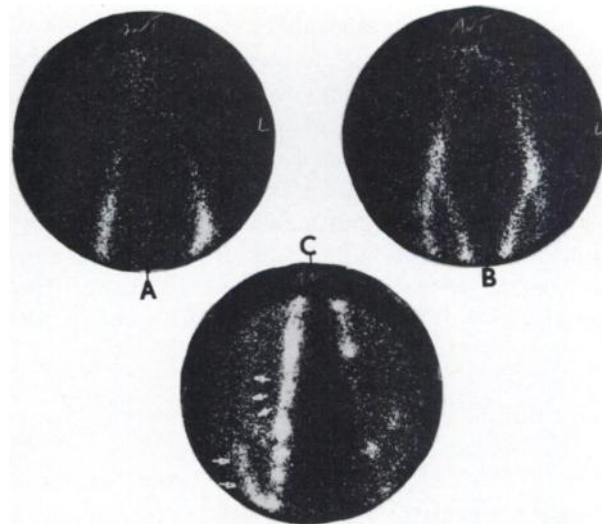
## RADIONUCLIDE VENOGRAPHY

It always has been my feeling that radionuclide venography is a highly recommended procedure for a patient with clinical evidence of pulmonary embolism because of its simplicity and usefulness. It was delightful, therefore, to read the article by Henkin, et al (1). In our series of radionuclide venographies, we have some findings that are not described in their rather extensive studies. An example is the visualization of the popliteal veins for more than 30 min after the injection of  $^{99m}\text{Tc}$ -HAM. At an early stage of the study when radionuclide activity was confirmed in the femoral vein, tourniquets were removed from both ankles. The early dynamic scintiphotogram showed a slight decrease in the blood flow through the right iliac vein (Fig. 1A). As the camera field was moved over the thigh, the femoral and saphenous veins appeared to be normal in both sides except for a delayed flow (Fig. 1B).

However, images of the popliteal veins obtained at a later stage were grossly abnormal showing retention of the radionuclide and development of collateral flow (arrows, Fig. 1C). In this particular case, markedly delayed clearance or hangup of the radionuclide in the popliteal veins was visualized up to 30 min after the injection.

Rosenthal has described visualization of trapped  $^{99m}\text{Tc}$ -human albumin macroaggregates at the region of thrombi, 7 min after the injection (2). It is apparent that a search for areas of delayed radionuclide clearance in the lower leg is a recommended practice, particularly when radionuclide venography over the pelvis and thigh is negative.

In view of the significant increase in field size, I prefer to use a 140-keV diverging-hole collimator despite considerable loss in sensitivity. With a dose of 1 mCi or more of  $^{99m}\text{Tc}$ -HAM in each leg, the



**FIG. 1.** Radionuclide venogram obtained from Pho/Gamma HP camera with 140-keV diverging-hole collimator. Two millicuries of  $^{99m}\text{Tc}$ -HAM were injected into dorsal vein of each foot. (A) Scintiphotogram of both iliac veins recorded 20 sec after injection. (B) Scintiphotogram of femoral and saphenous veins in both legs recorded about 1 min after injection. (C) Images of right and left popliteal veins recorded 25 min after injection.

lower sensitivity of the diverging-hole collimator has never been a problem in our venography series.

U. YUN RYO

Michael Reese Hospital and Medical Center  
Chicago, Illinois

## REFERENCES

1. HENKIN RE, YAO JST, QUINN JL, et al: Radionuclide venography (RNV) in lower extremity venous disease. *J Nucl Med* 15: 171-175, 1974
2. ROSENTHALL L: Combined inferior vena cavography, iliac venography and lung imaging with  $^{99m}\text{Tc}$ -albumin macroaggregates. *Radiology* 98: 623-626, 1971

## THE AUTHORS' REPLY

We are encouraged to see that other institutions are adopting what we have found to be an excellent technique for the evaluation of deep venous thrombosis (DVT) of the lower extremities.

Different institutions may employ slightly differ-

ent methodology in performing radionuclide venograms. It would appear that the method employed by Dr. Ryo resembles that of McDonald (1) more than the method we described (2).

We have, however, made observations similar to