

HEPATIC CAVERNOUS HEMANGIOMA PRESENTING AS AN "AVASCULAR MASS" IN A NEWBORN

Wassel Beal, Jagmeet S. Soin, and John A. Burdine

Baylor College of Medicine and Ben Taub General Hospital, Houston, Texas

A case of hepatic cavernous hemangioma complicated by bleeding in a 1-day-old child is presented. Radionuclide images suggest that bleeding hemangioma may present as an avascular mass in the liver.

Hepatic tumors in infants and children are rare but when present provide a serious clinical challenge (1). Diagnostic procedures such as angiography give useful information regarding vascular characteristics and enable us to differentiate hepatic masses such as hepatomas, cysts, and cavernous hemangiomas (2). However, contrast angiography is a direct and hazardous procedure particularly in the newborn. The noninvasive technique of hepatic scanning using ^{99m}Tc-sulfur colloid combined with sequential hepatic blood-pool imaging can be very helpful in studying such lesions (3). Hepatoma and hemangioma are usually vascular (4) and cavernous hemangiomas are particularly easy to diagnose because of their highly vascular nature (5-7). By contrast, when bleeding is present around a small hemangioma, the circulation may be compromised resulting in decreased activity on the blood-pool images. The following case illustrates this point.

CASE HISTORY

A 1-day-old, full-term 6-lb 5-oz girl born to a gravida-4, para-3 mother who had no prenatal care was noted to have a mass measuring approximately 7 × 9 cm in the mid and right upper quadrant of the abdomen. On clinical examination, the mass was firm and nonmobile. The remainder of the physical examination was unremarkable. Laboratory data, including hemoglobin and hematocrit, were within normal limits.

The patient was referred to the nuclear medicine department for a liver scan. Following an intravenous injection of 120 μCi of ^{99m}Tc-sulfur colloid, multiple

views of the liver and spleen were obtained using a scintillation camera. A mass lesion occupying a portion of the right liver lobe and also impinging upon the left was revealed (Fig. 1A). The following day, the patient received 900 μCi of ^{99m}Tc-pertechnetate for dynamic blood-pool imaging. The previously described abdominal mass appeared as an area of decreased vascularity (Fig. 1B).

Received Dec. 27, 1973; revision accepted April 29, 1974.

For reprints contact: John A. Burdine, Nuclear Medicine Section, Dept. of Radiology, Baylor College of Medicine, 1200 Moursund, Houston, Tex. 77025.

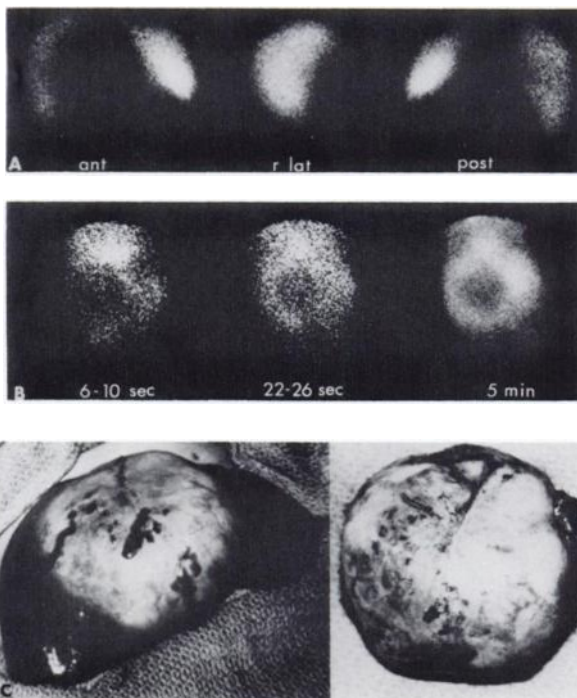


FIG. 1. (A) ^{99m}Tc-sulfur colloid liver scan, anterior, right lateral, and posterior views. Note decreased radioactivity in region of right and left liver lobes. (B) Rapid sequence hepatic scintigraphy reveals total avascularity in that region. (C) Shows actual mass in the liver. On resection, encapsulated hematoma around a small hemangioma (arrow) was seen.

The patient underwent abdominal exploration and a 5 × 7-cm mass weighing approximately 75 gm was removed from the liver. Ninety percent of the pathologic specimen consisted of organized blood clot whereas the actual cavernous hemangioma was comparatively small (Fig. 1C).

DISCUSSION

Liver scanning after the intravenous injection of radioactive colloid is a useful screening test to detect hepatic masses. Because radiocolloids delineate the distribution of functioning reticuloendothelial system, any lesion that displaces or replaces the normal liver tissue appears as an area of diminished reticuloendothelial activity, thus making the scan a sensitive though not a specific laboratory test. Recently, hepatic blood-pool scintigraphy (5-7) has been used to increase the specificity of liver-scanning techniques. This technique has been particularly helpful in separating vascular hepatic masses such as hepatoma and hemangioma from avascular masses such as cysts and abscesses. The decreased blood-pool activity in the area of the hepatic mass in this newborn proved to be misleading since it apparently decreased the possibility of a cavernous hemangioma.

Because bleeding is a frequent complication of cavernous hemangioma, it is well to keep in mind that diminished vascularity in the area of a hepatic mass does not necessarily exclude the presence of hemangioma.

REFERENCES

1. EDMONDSON HA: Differential diagnosis of tumors and tumor-like lesions of liver in infancy and childhood. *Am J Dis Child* 91: 168-186, 1956
2. GRAIVIER L, VOTTELER TP, DORMAN GW: Hepatic hemangiomas in newborn infants. *J Pediatr Surg* 2: 299-307, 1967
3. FREEMAN LM, MANDELL CH: Dynamic vascular scintigraphy of the liver. *Semin Nucl Med* 2: 133-138, 1972
4. LUBIN E, LEWITUS Z: Blood pool scanning in investigating hepatic mass lesions. *Semin Nucl Med* 2: 128-132, 1972
5. YEH SH, SHIH WJ, LIANG JC: Intravenous radionuclide hepatography in the differential diagnosis of intrahepatic mass lesions. *J Nucl Med* 14: 565-567, 1973
6. GORDON F, CUARAN A, MUÑOZ JR, et al: Scanning of the hepatic blood pool in the differential diagnosis of space-occupying lesions of the liver. *Ann Intern Med* 78: 247-250, 1973
7. FREEMAN LM, BERNSTEIN RG, HAYT DB: Diagnosis of hepatic hemangioma with combined scanning technique. *Radiology* 95: 127-128, 1970