

QUANTITATIVE ANALYSIS OF BRAIN SCANS

En-Lin Yeh and Robert C. Meade

Wood Veterans Administration Center and the Medical College of Wisconsin, Milwaukee, Wisconsin

Brain scans were done on 38 patients without evidence of organic brain disease or scalp lesion. The means and standard deviations of the difference between bilateral peripheral activity were $0.2 \pm 2.7\%$ and $0.2 \pm 2.6\%$ for the anterior and posterior views, respectively. In a normal person, a rotated posterior brain scan usually showed higher activity on the side to which the sagittal sinus was shifted (83%). Therefore, if activity is higher on the side opposite the sagittal sinus, abnormality may exist. In the anterior view rotation caused no consistent asymmetry. On the lateral view all but one of 70 scans showed normal frontal lucency. This study confirms the validity of this normal sign.

In the brain scan reading, symmetry of the bilateral peripheral activity on the anterior or posterior view is one of the normal diagnostic criteria. Asymmetry, such as a crescent pattern, could be due to a subdural hematoma, granulomatous pachymeningitis, scalp trauma, craniotomy defect, cerebral ischemia, metastatic carcinoma, unilateral Paget's disease, or occlusion of the carotid artery (1). In a normal person, however, the brain scan may show asymmetry if the head is incorrectly positioned during scanning (2). A mild asymmetry may be read as normal or abnormal depending on the subjective impressions of different readers. Computer interpretation of the brain scan may be based on the quantitative comparison of bilateral activities (3,4). We attempted to get a normal range of difference between the bilateral peripheral activity on both the anterior and posterior views for an objective interpretation of asymmetry of the brain scan.

This study was undertaken to find the answers to the following questions: (A) In the patients without definite evidence of organic brain disease, how symmetric is the brain scan on the anterior and posterior views? (B) Does rotation of the head cause asymmetry in a predicted manner as to the side of increased uptake and degree of asymmetry? (C) How significant is frontal lucency on the lateral views?

MATERIAL AND METHOD

Thirty-eight patients were selected for this study by the following criteria: (A) Symptoms were non-specific, such as general headache and dizziness; (B) There were no signs of central nervous system dysfunction and no scalp lesions; (C) EEG, skull x-ray, carotid or vertebral arteriogram, and pneumoencephalogram were negative if done; and (D) No specific diagnosis of organic brain disease was included in the final diagnoses.

A rectilinear scanner with a color videodisplay and processing unit was used in this study*. The display unit is capable of displaying the number of counts in any sized rectangular region of interest which can be positioned anywhere on the scope. For this study, only the total counts were used without subtraction or enhancement.

The region of interest was adjusted to include the maximal amount of peripheral activity between the temporal muscle and sagittal sinus on anterior view and between transverse sinus and sagittal sinus on posterior view (Fig. 1). The region of interest was moved horizontally above the temporal muscle activity on the anterior view and above the transverse sinus on the posterior view until it reached a maximal count of peripheral activity on either side. The difference between the counts on each side was expressed as a percent of the higher count. For 17

Received Aug. 4, 1972; original accepted Sept. 27, 1972.

For reprints contact: En-Lin Yeh, Nuclear Medicine Service, Wood Veterans Administration Center, Milwaukee, Wis. 53193.

* General Electric Co., Medical System Div., Milwaukee, Wis.




FIG. 1. Regions of interest. Rectangular areas are regions of interest.

TABLE 1. CHANGES ON PERIPHERAL ACTIVITIES DUE TO ROTATION OF HEAD BY 10 DEG

	Activity increased on the side toward which the nose was turned			Activity increased on the side opposite the nose		
	Number of scans/total	Mean increase	Number of scans with "abnormal" asymmetry*	Number of scans/total	Mean increase	Number of scans with "abnormal" asymmetry*
Anterior view	19/34 (56%)	3.3%	4	15/34 (44%)	5.1%	6
Posterior view	6/36 (17%)	3.6%	2	30/36 (83%)	5.6%	11

* "Abnormal" asymmetry indicates a difference of bilateral peripheral activity of more than 2 s.d. of the corresponding view without rotation (5.4% for anterior view and 5.2% for posterior view).

patients the anterior views were repeated after the head was rotated 10 deg to the right and then 10 deg to the left. With 18 patients the posterior views were repeated with head rotation of 10 deg to each side. On the lateral view two equal-sized regions of interest were obtained to yield minimal activity in both the anterior and posterior regions (Fig. 1). The results were expressed by the ratio of anterior to posterior counts.

RESULTS

In 38 "normal" anterior and posterior brain scans, the means and standard deviations of the difference between bilateral peripheral activity were $0.2 \pm 2.7\%$ and $0.2 \pm 2.6\%$ for the anterior and posterior views, respectively. Therefore, an asymmetry with activity on one side more than 5.4% higher than that on the other side was considered "abnormal" on either the anterior or posterior view.

Rotation of the head by 10 deg caused changes on the anterior and posterior views as shown in Table 1. On the anterior view rotation caused an increase of the peripheral activity on either side with about equal frequency (Figs. 2A-F). However, in 83% of the posterior brain scans, the activity was lower on the side toward which the patient's nose was turned (Figs. 2G, H, K).

On the lateral views all but one of 70 scans showed less activity in the frontal region. The mean and standard deviation of anterior to posterior ratio was 0.931 ± 0.038 . The exceptional case had a ratio of 1.004.

DISCUSSION

The actual count in each region of interest was about 10,000 counts, and the standard error of counting should be only 1% $[(10,000)^{1/2}/10,000]$. It is apparent that the normal asymmetry with 1 s.d.

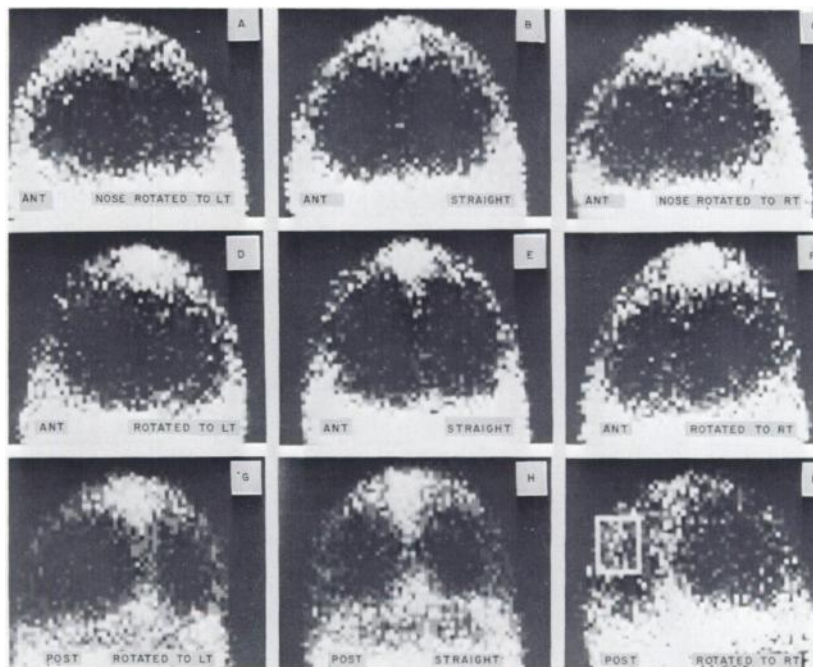


FIG. 2. Effect of rotation on anterior and posterior brain scan. Rectangular area in Picture K indicates region of interest.

POSTERIOR SCANNING

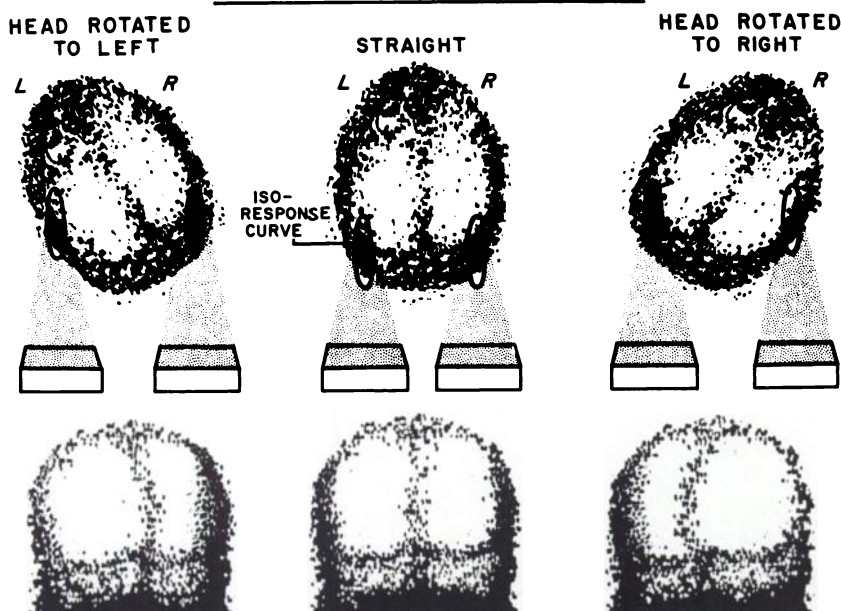


FIG. 3. Diagrammatic explanation of difference due to rotation on posterior brain scan. Note the activity on side to which sagittal sinus is shifted is higher than on other side.

of 2.7% or 2.6% of the counts is more than the difference resulting from statistical counting error. It was therefore concluded that there may be a real difference between the right and left side of a normal brain scan.

Since rotation of the head is known to cause asymmetry of the brain scan, the importance of proper positioning during scanning cannot be overemphasized. If rotation of the head produces a consistent finding in the brain scan, it may be possible to identify the false-positive findings and neglect them. Miller and Simmons reported that on a rotated posterior view with the nose turned to the right there was increased activity over the superior portion of the right hemisphere. If the rotation was marked, the concentration of radioactivity was even greater on the right, simulating the appearance of a right subdural hematoma (5). However, in our study 30 of 36 (83%) rotated posterior scans showed increased activity on the side opposite the nose (Table 1).

Figure 3 suggests why the activity may be increased on the side away from the patient's nose or to which the sagittal sinus activity is shifted. As shown in a normal vertex view, the peripheral activity is higher posteriorly on a brain scan. In a rectilinear scan when the head is rotated, the posteriorly located high activity is brought closer to the focal point on the side to which the sagittal sinus is shifted.

The finding that in a rotated posterior brain scan the peripheral activity is usually higher on the side to which the sagittal sinus is shifted (Figs. 2G, H, and K) may be useful in brain scan reading. For

example, if a rotated posterior brain scan shows higher activity on the side opposite the sagittal sinus, the chance of this brain scan being abnormal is greater and a repeat scan should be strongly recommended.

Unfortunately on the anterior view rotation caused increased activity on either side with about equal frequency. Miller and Simmons (5) observed that, on the anterior view if the nose had been turned to the right, the left hemisphere appears more intense. However, we could not confirm their observation as a rule in rectilinear scanning.

On the lateral view the so-called normal "frontal lucency" (6) was evident on all but one scan. It confirms the value of this normal sign.

ACKNOWLEDGMENT

The authors wish to thank Gene E. Keller for his technical assistance in this study.

REFERENCES

1. HEISER WJ, QUINN JL, MOLLIHAN WV: The crescent pattern of increased radioactivity in brain scanning. *Radiology* 87: 483-488, 1966
2. DELAND FH, WAGNER HN: *Atlas of Nuclear Medicine: Brain*, vol 1, Philadelphia, WB Saunders, 1969, pp 1-3
3. DOWSETT DJ, PERRY BJ: A comparative statistical analysis of brain scans using a digital computer. *Brit J Radiol* 43: 617-628, 1970
4. POPHAM MG, BULL JWD, EMERY EW: Interpretation of brain scans by computer analysis. *Brit J Radiol* 43: 835-847, 1970
5. MILLER MS, SIMMONS GH: Optimization of timing and positioning of the ^{99m}Tc brain scan. *J Nucl Med* 9: 429-435, 1968
6. PATTON DD, HERTSGAARD DB: Importance of frontal lucency in the lateral brain scan. *J Nucl Med* 12: 454-455, 1971