

AN INTERESTING ARTIFACT IN RADIONUCLIDE IMAGING OF THE KIDNEYS

Kenneth A. McKusick, Leon S. Malmud, Peter T. Kirchner, and Henry N. Wagner, Jr.

The Johns Hopkins Medical Institutions, Baltimore, Maryland

An artifactual area of increased activity in a kidney scan obtained with ^{99m}Tc -DTPA is attributed to gastric secretion of free technetium. The presence of such artifacts may be suspected from images of either the neck or abdomen obtained after the kidney scan.

We have recently observed an interesting artifact in a kidney study using ^{99m}Tc -DTPA (Sn). Our goal in presenting the results is twofold: first, to describe the pattern so that others may recognize it if it should occur in their patients, and second, to emphasize the importance of strict radiopharmaceutical quality control.

CASE

A 37-year-old hypertensive woman was referred for a renal scan. A previous IVP had shown a right double ureter. The scan using ^{99m}Tc -DTPA (Sn) prepared from a commercially obtained kit showed a diffuse area of increased activity over the upper pole of the left kidney (Fig. 1A). The activity which appeared within the first minute increased as the study progressed. A renal scan the following day with ^{111}In -DTPA showed no similar increased activity over the left upper pole (Fig. 1B), but images taken in the technetium window showed activity in the large bowel.

DISCUSSION

The artifact seen in this case was due to gastric secretion of free ^{99m}Tc . Technetium-99m-DTPA (Sn) is a stable chelated radiopharmaceutical which is excreted as a glomerular agent (1,2). The presence of free ^{99m}Tc in this case implied that there was inadequate binding of the technetium to the chelate. To be chelated by DTPA, technetium must be in the reduced IV valence state (3). Technetium-99m

is in the VII state when eluted from a generator and is reduced by the stannous ion present in Brookhaven DTPA (which was used in this case).

In order that the stannous ion not be oxidized to the stannic ion in the presence of oxygen, several steps in the production of DTPA (Sn) are performed under nitrogen (2). When there is a defective system with oxygen present, the stannous ion may be partially oxidized, leaving little stannous ion to act as the reducing agent for pertechnetate.

The gastric technetium-pertechnetate secretion in this case may have been due to one of several possibilities. Either a chemical from the technetium generator interfered with the tagging of the chelate or the vial of DTPA (Sn) was not properly prepared by the manufacturer.

When ^{99m}Tc -pertechnetate from three different commercial sources was tested by tissue distribution studies using vials from the same DTPA kit as used in the patient, the results were normal. This indicated that the fault was not a constituent or contami-

Received Aug. 28, 1972; original accepted Sept. 19, 1972.

For reprints contact: Kenneth A. McKusick, Div. of Nuclear Medicine, The Johns Hopkins Medical Institutions, 615 N. Wolfe St., Baltimore, Md. 21205.

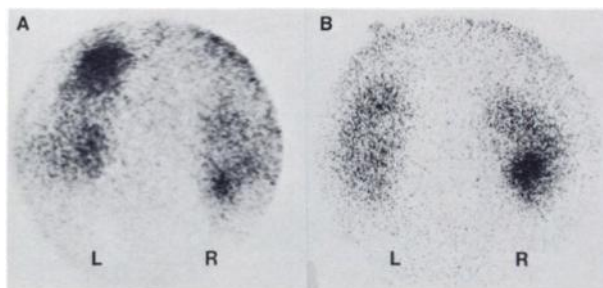


FIG. 1. (A) Renal scan using ^{99m}Tc -DTPA (Sn) with artifactual increased activity over the upper pole of the left kidney. (B) Renal scan performed following day with ^{111}In -DTPA showing no similar increased activity.

nant of the ^{99m}Tc source but was due to the processing of the single vial of DTPA (Sn) employed in the reported case.

Increasing numbers of new and complex radiopharmaceuticals are becoming rapidly available. While it is incumbent upon the manufacturers to continue to apply strict quality control, it is also becoming increasingly necessary for the clinician to be alert to unexpected behavior of these new agents. Therefore it is suggested that one of two additional images be routinely obtained to test for the presence of free pertechnetate when using ^{99m}Tc -DTPA (Sn) for renal scanning. This could be either a camera image of the neck for the presence of thyroid and salivary gland activity or an anterior abdominal image for the presence of gastric activity. This lab-

oratory has chosen the latter method, which is done at the end of the study after the routine anterior bladder image.

ACKNOWLEDGMENT

Phillip L. Hagan performed the tissue distribution studies.

REFERENCES

1. HAUSER W, ATKINS HL, NELSON KG, et al: Technetium 99m DTPA: A new radiopharmaceutical for brain and kidney scanning. *Radiology* 94: 679-684, 1970
2. ATKINS HL, CARDINALE KG, ECKELMAN WC, et al: Evaluation of ^{99m}Tc -DTPA prepared by three different methods. *Radiology* 98: 674-677, 1971
3. ECKELMAN WC, MEINKEN G, RICHARDS P: The chemical state of ^{99m}Tc in biomedical products. II the chelation of reduced technetium with DTPA. *J Nucl Med* 13: 577-581, 1972

WORLD FEDERATION OF NUCLEAR MEDICINE AND BIOLOGY

First World Congress of Nuclear Medicine and Biology

September 30-October 5, 1974

Tokyo and Kyoto, Japan

The First World Congress of Nuclear Medicine and Biology will be held in Tokyo and Kyoto, Japan, from September 30 to October 5, 1974, under the auspices of the World Federation of Nuclear Medicine and Biology (WFNMB).

The Congress is the first international event to be organized following the official foundation of WFNMB in Mexico on October 26, 1970. This meeting represents one of the most authoritative scientific projects ever planned in the field of nuclear medicine based on the Foundation Charter of 1970, and similar meetings are to be held every four years.

The Organizing Committee for the Congress is now making extensive preparations and has selected a meeting date that will not conflict with other international congresses in related fields scheduled for that time of year. Since a large number of participants from all over the world are expected, the Organizing Committee would appreciate information from every country on the number of persons who might attend.

A second progress report on the meeting will be mailed out soon. If you have any questions concerning the congress, please contact:

Hideo Ueda, M.D., President
First World Congress
of Nuclear Medicine and Biology
c/o Japanese Society of Nuclear Medicine
The Second Department of Medicine
Faculty of Medicine, University of Tokyo
7-3-1, Hongo, Bunkyo-ku, Tokyo 113, Japan

Cable Address "WORFEDNUC" Tokyo
Telephone 03-814-0530